

100 G



22101622286

BRITISH MEDICAL
ASSOCIATION
CANCELLED



THE
CROONIAN LECTURES FOR 1875

LONDON : PRINTED BY
SPOTTISWOODE AND CO., NEW-STREET SQUARE
AND PARLIAMENT STREET



ON
ADDISON'S DISEASE

BEING THE
CROONIAN LECTURES FOR 1875

DELIVERED BEFORE THE ROYAL COLLEGE OF PHYSICIANS

REVISED and ILLUSTRATED by PLATES and REPORTS of CASES

BY

EDWARD HEADLAM GREENHOW, M.D., F.R.S.

FELLOW OF THE ROYAL COLLEGE OF PHYSICIANS
PHYSICIAN TO, AND LECTURER ON THE PRINCIPLES AND PRACTICE
OF MEDICINE AT, THE MIDDLESEX HOSPITAL.

LONDON
LONGMANS, GREEN, AND CO.

1875

WELLCOME INSTITUTE
LIBRARY

Coll. we!MOmec

Call

No WK700

1875

G810

TO

SIR GEORGE BURROWS, BART., M.D., F.R.S., D.C.L.

PHYSICIAN IN ORDINARY TO THE QUEEN

PRESIDENT OF THE ROYAL COLLEGE OF PHYSICIANS

ETC.

THESE LECTURES

DELIVERED BEFORE THE COLLEGE OVER WHICH

HE SO ABLY PRESIDES

Are Dedicated

WITH SINCERE RESPECT

BY

THE AUTHOR



Digitized by the Internet Archive
in 2016

<https://archive.org/details/b21497485>

P R E F A C E .

THIS VOLUME comprises the Croonian Lectures delivered before the Royal College of Physicians in the early part of the present year ; and, also, a series of Reports of the principal cases upon which the Lectures were founded.

The Lectures have been carefully revised for publication in their present form ; many details, necessarily omitted at the time of their delivery, have been supplied ; and several passages have been amplified, or entirely re-written, in order to explain the views, which they were intended to convey, more fully than was possible in their original condensed form.

The limited time at my disposal, for the delivery of the Lectures, rendered it impossible to support my views by giving detailed reports of individual cases, even had I judged it suitable to do so, before the audience I had the honour of addressing ; but as these reports are necessary to the completion of my work, as supplying evidence of the clinical and pathological facts upon which I have formed the conclusions enun-

ciated in the Lectures, I have printed, in Appendix A, detailed reports of thirty-seven cases, selected partly from those which have come under my own observation, and partly from amongst those which have been published by other observers, both English and foreign.

I had prepared, and intended to have published, a series of tables, containing an abstract of the clinical history and *post-mortem* appearances in each of the three hundred and thirty-three cases, which I had collected as bearing upon the subject of Addison's disease. On further consideration, however—seeing that one hundred and ninety-eight of these cases had already been published by me, in this tabular form, in the seventeenth volume of the 'Transactions of the Pathological Society,' and that many of the abstracts were, necessarily, mere repetitions of the well-known, salient, features of the disease—I have judged it best to print, in fuller detail, the selection of illustrative cases already referred to as forming Appendix A; and, in Appendix B, merely to arrange the whole number of cases in groups, corresponding to those indicated in the text, under the names of their respective reporters, with a full reference to the publication from which each case was extracted. I have subjoined to the bibliographical reference, in each case, the sex, age, and rank or occupation, of the patient, together with such other

facts as are dwelt upon in the text, as bearing upon the questions of the etiology, or pathology, of the disease.

My best acknowledgments are due to several medical friends, who have courteously invited me to see cases of this somewhat rare disease, which have been under their care, in the London hospitals, during the preparation of this work. One of these cases, which was referred to in Lecture III., and the notes of which were kindly forwarded to me by Dr. Bristowe after the patient's death, appears as Case X. in Appendix A, and is included in the group of typical cases in Appendix B. The report of a case which came under my own care at the Middlesex Hospital, since the delivery of the Lectures, also appears in Appendix A, as Case VIII., but is not included in Appendix B.

I gladly avail myself of this opportunity of expressing my sincere thanks to Dr. Burdon Sanderson, V.P.R.S., to Mr. Henry Arnott, and to Dr. Sidney Coupland, for the very beautiful drawings of the microscopical appearances of the altered structures in Addison's disease, which form so valuable an addition to this volume.

14A MANCHESTER SQUARE :

September 1875.

CONTENTS.

LECTURE I.

PAGE

REASONS FOR SELECTION OF SUBJECT—BIOGRAPHICAL NOTICE OF DR. ADDISON—HISTORY OF DISCOVERY—CASES OF SUPRA-RENAL DISEASE PREVIOUSLY RECORDED—CLINICAL DESCRIPTION OF ADDISON'S DISEASE; CONSTITUTIONAL SYMPTOMS; DISCOLORATION OF SKIN, OF MUCOUS MEMBRANE OF MOUTH, LIPS, AND TONGUE; SEAT OF DISCOLORATION IN SKIN AND TONGUE; PAROXYSMAL COURSE OF DISEASE; OCCASIONAL LATENCY; VARIABLE COMPARATIVE DATE OF APPEARANCE OF SYMPTOMS AND DISCOLORATION—PATHOLOGICAL LESION; ONE PARTICULAR AFFECTION OF SUPRA-RENAL CAPSULES; VARYING IN APPEARANCE; SEMI-TRANSPARENT TISSUE; YELLOW CASEOUS MATERIAL; CRETACEOUS MATERIAL; CREAMY OR PLURIFORM FLUID; MICROSCOPICAL APPEARANCES—EVIDENCES OF INFLAMMATION IN AND AROUND ENVELOPES OF CAPSULES—IMPLICATION OF NERVE-PLEXUSES AND GANGLIA IN PROLIFERATED CONNECTIVE-TISSUE—ENLARGEMENT OF NEIGHBOURING LYMPHATIC GLANDS—ENLARGEMENT OF PEYER'S PATCHES AND SOLITARY GLANDS—MAMMILLATIONS, ECCHYMOSES, AND SMALL ULCERS OF GASTRIC MUCOUS MEMBRANE; MICROSCOPICAL APPEARANCE OF MAMMILLATIONS—ENLARGED SPLEEN 1

LECTURE II.

ADDISON'S DISCOVERY NEITHER GENERALLY ACCEPTED NOR GENERALLY UNDERSTOOD; ACCEPTANCE MAINLY RETARDED BY PREVALENT MISCONCEPTIONS—EVIDENCE IN PROOF OF RELATION BETWEEN CLINICAL SYMPTOMS AND ONE PARTICULAR LESION OF SUPRA-RENAL CAPSULES—STATISTICS OF PUBLISHED CASES—TYPICAL CASES; CASES APPARENTLY TYPICAL; CASES WITH OTHER CO-EXISTING DISEASE; IMPERFECTLY RECORDED CASES; CASES WITHOUT DISCOLORATION OF SKIN—MISCONCEPTIONS—DISCOLORATION OF SKIN MAY OCCUR WITHOUT DISEASE OF SUPRA RENAL CAPSULES; DISCOLORATION IN VAGABONDS; IN PITA-

RIASIS VERSICOLOR; IN SYPHILIS; IN UTERINE DISEASE; IN MALARIOUS POISONING AND HEPATIC DISEASE; IN PHTHISIS—CASES OF DISCOLORATION OF SKIN WITHOUT DISEASE OF THE SUPRA-RENAL CAPSULES; EXPLANATION OF THEIR TRUE CHARACTERS—DISEASE OF SUPRA-RENAL CAPSULES MAY EXIST WITHOUT DISCOLORATION OF SKIN; CASES OF CANCER, AMYLOID DISEASE, FATTY DEGENERATION, APOPLEKY, AND TUMOURS OF SUPRA-RENAL CAPSULES—CASES OF SPURIOUS BRONZING OF SKIN WITH VARIOUS DISEASES OF SUPRA-RENAL CAPSULES; EXPLANATION OF THEIR TRUE CHARACTERS—CASES OF ADDISON'S DISEASE ERRONEOUSLY CLASSED AS CASES OF CANCER OF THE SUPRA-RENAL CAPSULES—CASES IMPERFECTLY DESCRIBED OR OF DOUBTFUL NATURE . 31

LECTURE III.

SYMPTOMS OF ADDISON'S DISEASE NOT DUE TO DESTRUCTION OF TISSUE OF SUPRA-RENAL CAPSULES—INTIMATE RELATIONS OF SUPRA-RENAL CAPSULES WITH NERVOUS SYSTEM—SYMPTOMS DUE TO PROLIFERATION OF CONNECTIVE-TISSUE WITHIN AND AROUND CAPSULES, COMPRESSING NERVE-GANGLIA AND PLEXUSES—CHANGES PRODUCED IN NERVES BY PRESSURE OF INFLAMMATORY TISSUE; IRRITATION; ATROPHY AND FATTY DEGENERATION; IMPAIRMENT OF NERVE-FUNCTIONS—CLINICAL GROUNDS FOR REFERRING SYMPTOMS OF ADDISON'S DISEASE TO NERVE-LESIONS—PHYSIOLOGICAL GROUNDS; VIEWS OF OTHER AUTHORS—BRONZING OF SKIN; CAUSES OF; VIEWS OF OTHER AUTHORS—CONDITION OF BLOOD IN ADDISON'S DISEASE—BRONZING OF SKIN ALSO DUE TO NERVE-LESIONS—ETIOLOGY OF ADDISON'S DISEASE—AFFINITIES WITH TUBERCLE; FREQUENT CO-EXISTENCE OF TUBERCULAR OR STRUMOUS DISEASE—EXTENSION OF INFLAMMATION TO SUPRA-RENAL CAPSULES FROM DISEASED OR INJURED ADJACENT PARTS; CASES OF ADDISON'S DISEASE ASSOCIATED WITH PSOAS OR LUMBAR ABSCESSSES—CASES ASSOCIATED WITH MORE DISTANT ABSCESSSES OR DISEASE OF BONES—CASES FOLLOWING A STRAIN, OR BLOW, OR PHYSICAL SHOCK, WITHOUT EVIDENCE OF LOCAL INJURY—CASES FOLLOWING OVER-EXERTION AND MENTAL ANXIETY—INFLUENCE OF SEX, AGE, AND OCCUPATION ON DEVELOPMENT OF DISEASE—DIAGNOSIS—PROGNOSIS—TREATMENT—SUMMARY 64

APPENDICES.

APPENDIX A.

CASE	PAGE
I. Addison's Disease. Typical Case.	101
II. Addison's Disease. Pelvic Abscess	104
III. Addison's Disease. Typical Case. Slight Discoloration of Skin	107
IV. Addison's Disease. Tubercle of Lungs and Abdomen	110
V. Addison's Disease. Injury to Vertebrae. Lumbar Abscess	114
VI. Addison's Disease. Typical Case	117
VII. Addison's Disease. Angular Curvature of Spine; Lumbar Abscess	119
VIII. Addison's Disease. Angular Curvature of Spine; Obsolete Lumbar Abscess	125
IX. Addison's Disease. Typical Case	129
X. Addison's Disease. Typical Case	131
XI. Addison's Disease. Typical Case	133
XII. Addison's Disease. Apparently Typical Case.	139
XIII. Addison's Disease without Discoloration of Skin. Rapid Phthisis	140
XIV. Addison's Disease. Typical Case. Death after a few days' Illness	142
XV. Addison's Disease without Discoloration of Skin. Psoas Abscess and Caries of the Lumbar Vertebrae	143
XVI. Addison's Disease. Typical Case	145
XVII. Addison's Disease. Typical Case	150
XVIII. Addison's Disease. Typical Case	153
XIX. Addison's Disease. Tubercle in Lungs. Disease of Tibia and Tarsal Bones. Bronzing of Skin for Seven Years	155
XX. Addison's Disease. No Discoloration of Skin	156
XXI. Addison's Disease of one Supra-renal Capsule. Apparently Typical Case	157
XXII. Addison's Disease. Typical Case	160
XXIII. Addison's Disease. Typical Case	164
XXIV. Addison's Disease. Typical Case	167
XXV. Addison's Disease. Typical Case	169
XXVI. Addison's Disease. Typical Case. Discoloration of Skin . developed long before Constitutional Symptoms	172
XXVII. Addison's Disease. Typical Case	173
XXVIII. Addison's Disease, without Discoloration of Skin	176
XXIX. Addison's Disease. Typical Case	178
XXX. Addison's Disease. Typical Case	180
XXXI. Addison's Disease. Typical Case	182

CASE	PAGE
XXXII. Addison's Disease. Angular Curvature of Spine	183
XXXIII. Addison's Disease. Ulcers of Colon and Strumous Abscesses.	184
XXXIV. Addison's Disease. Typical Case	186
XXXV. Addison's Disease. Typical Case. Reported as Addison's Disease and Cancer of the Supra-renal Capsules	188
XXXVI. Addison's Disease. Typical Case. Reported as Addison's Disease and Cancer of the Supra-renal Capsules	189
XXXVII. Addison's Disease. Supposed Cancerous Disease of Supra- renal Capsules	190

APPENDIX B.

GROUP	PAGE
Introductory Explanation	193
I. Typical cases of Addison's Disease, in which the characteristic constitutional symptoms and discoloration of skin were more or less fully developed, and in which there was no co-existing disease	195
II. Cases of Addison's Disease apparently typical, but in which either the state of other organs is not reported, or the constitutional symptoms and discoloration of skin are not fully described	200
III. Cases of Addison's Disease, in which the characteristic constitutional symptoms and discoloration of skin were more or less fully developed, but in which there was some co-existing disease	201
IV. Cases of Addison's Disease imperfectly recorded	204
V. Cases of Addison's Disease without discoloration of skin, in which there were serious co-existent wasting diseases, and, generally speaking, no characteristic constitutional symptoms.	205
VI. Cases of Addison's Disease without discoloration of skin, in which there was no co-existing disease of importance, and which were typical as to constitutional symptoms, but of short duration	206
VII. Cases of 'Bronzed Skin' without any disease of the Supra-renal Capsules	207
VIII. Cases of Cancer of the Supra-renal Capsules without any discoloration of skin	208
IX. Cases of Miscellaneous Affections of the Supra-renal Capsules without any discoloration of skin	209
X. Cases of Cancer (or so-called Cancer) of the Supra-renal Capsules with some discoloration of skin	210
XI. Cases of Miscellaneous Affections of the Supra-renal Capsules with some discoloration of skin	210
XII. Cases in which the lesion in the Supra-renal Capsules is imperfectly described, or of doubtful nature	211

LIST OF PLATES.



PLATE	PAGE
I. Discoloration of the Tongue in a case of Addison's Disease	14
II. Fig. 1. Microscopical appearance of section of discoloured patch on the tongue in a case of Addison's Disease	
,, Figs. 2 and 3. Microscopical appearances of sections of discoloured Skin in cases of Addison's Disease .	16
III. Figs. 1-3. Naked-eye appearances of the Supra-renal Capsules in different stages of Addison's Disease	24
IV. Figs. 1-6. Microscopical appearances of the Supra-renal Capsules in different stages of Addison's Disease	25
V. Fig. 1. Microscopical appearance of section of a Supra-renal Capsule, illustrating the manner in which the inflammatory new growth encroaches upon and destroys the normal tissue of the organ in Addison's Disease	
,, Fig. 2. Microscopical appearance of a vertical section through the Mammillated Mucous Membrane of the Stomach in a case of Addison's Disease .	29

ON

ADDISON'S DISEASE.

LECTURE I.

REASONS FOR SELECTION OF SUBJECT—BIOGRAPHICAL NOTICE OF DR. ADDISON—
HISTORY OF DISCOVERY—CASES OF SUPRA-RENAL DISEASE PREVIOUSLY RE-
CORDED—CLINICAL DESCRIPTION OF ADDISON'S DISEASE; CONSTITUTIONAL
SYMPTOMS; DISCOLORATION OF SKIN, OF MUCOUS MEMBRANE OF MOUTH,
LIPS, AND TONGUE; SEAT OF DISCOLORATION IN SKIN AND TONGUE—PA-
ROXYSMAL COURSE OF DISEASE; OCCASIONAL LATENCY; VARIABLE COMPARATIVE
DATE OF APPEARANCE OF SYMPTOMS AND DISCOLORATION—PATHOLOGICAL
LESION; ONE PARTICULAR AFFECTION OF SUPRA-RENAL CAPSULES; VARYING
IN APPEARANCE; SEMI-TRANSPARENT TISSUE; YELLOW CASEOUS MATERIAL;
CRETACEOUS MATERIAL; CREAMY OR PURIFORM FLUID; MICROSCOPICAL AP-
PEARANCES—EVIDENCES OF INFLAMMATION IN AND AROUND ENVELOPES OF
CAPSULES—IMPLICATION OF NERVE-PLEXUSES AND GANGLIA IN PROLIFERATED
CONNECTIVE TISSUE—ENLARGEMENT OF NEIGHBOURING LYMPHATIC GLANDS—
ENLARGEMENT OF PEYER'S PATCHES AND SOLITARY GLANDS—MAMMILLATIONS,
ECCHYMOSES, AND SMALL ULCERS OF GASTRIC MUCOUS MEMBRANE; MICRO-
SCOPICAL APPEARANCES OF MAMMILLATIONS—ENLARGED SPLEEN.

51
MR. PRESIDENT AND GENTLEMEN,—When, upon my appoint-
ment to the honourable position of Croonian Lecturer for the
present year, I selected for my subject 'Addison's Disease,'
two reasons influenced me in making this selection. The
first, and perhaps the chief, reason was that the study of
this remarkable disease has always been to me especially
interesting, and has engaged my attention at every available
opportunity ever since the announcement of its discovery.
But another reason, which also weighed much with me when
making choice of my subject, was that a discovery which
must be counted among the great medical discoveries of the

present century, and which may with propriety be ranked side by side with Dr. Bright's discovery of the relation between dropsy and disease of the kidneys, has never, hitherto, been made the subject of any of the lectures delivered before this College, of which the discoverer was so distinguished a fellow.

And now, Sir, before I address myself to my proper subject—Dr. Addison's discovery—permit me to say a few words respecting Dr. Addison himself; for it seems to me that to show, though of necessity but briefly, from what, and how, Thomas Addison rose to become one of the most eminent physicians and ablest clinical teachers of our day, is, on the present occasion, only a fitting tribute to his memory.

Dr. Addison belonged to that class of men, so numerous in this country, who, by their abilities and energy, have raised themselves from the lower ranks of society to the most exalted positions in their respective callings. He was born in the autumn of 1795, at Long Benton, a small rural village in Northumberland, situated about three-and-a-half miles from Newcastle-on-Tyne. His father was a grocer and flour-dealer; but, though of humble station, he must have been a man of enlarged views, for he not only gave his son the best elementary education within his reach, but he aspired to start him in life on a much higher social level than his own. Dr. Addison himself told me that his father had designed him for the law, but that personal predilections had induced him to embrace the profession of medicine.

Addison was first sent, with his brother, to a school kept in a roadside cottage by one John Rutter, the parish clerk; from whom also, some years later, Robert, the son of George Stephenson, received his elementary education, whilst his father was engine-wright at the neighbouring Killingworth collieries. Addison was subsequently removed to a school of a somewhat higher class, either at Newcastle-on-Tyne, or at

a place called Three-mile Bridge, on the great North road. From thence he went to Edinburgh, and became a medical student.

Fortunately, his father had the means, as well as the desire, to afford his son every possible advantage for acquiring a knowledge of his profession. The opening out of collieries in the parish had largely increased his custom among the pit-folk of the neighbourhood, and he had become rich for his station. Addison, therefore, after passing through the necessary curriculum of medical study in Edinburgh, and taking the degree of M.D., was enabled to come to London, where he first became house-surgeon to the Lock Hospital, and subsequently physician to the Carey Street Dispensary, and also, I believe, to the Royal Infirmary for Children and Women in Waterloo Road. Soon after his arrival in London he had entered himself as a pupil at Guy's Hospital, and, in a comparatively short space of time, he was raised to be a member of the medical staff of that institution. In this position he speedily made for himself a great reputation as a practical physician and clinical teacher.

The wide experience acquired in such various fields of study, together with his own great natural powers of observation, sufficiently explain the apparently intuitive knowledge of disease, and almost unrivalled powers of diagnosis, which formed the basis of Addison's great and real success in professional life. For his success was real. It was not small, if estimated in the lower sense by its pecuniary results; but, if estimated in the far higher sense by achievement and reputation, his success was great indeed, and such as only a favoured few can hope to equal. In some subjects he was far in advance of his day. Pathological truths which he enunciated thirty years ago, with respect to diseases of the lungs, have only recently won their way to general acceptance. The discovery with which his name will ever be

associated was published to the medical world nearly twenty years ago, and has not yet been generally accepted, nor even generally understood.

Dr. Addison died at Brighton in June 1860, and was interred at Lanercost Abbey, in Cumberland, from whence his family had originally sprung, and where his paternal grandfather had been a respectable yeoman. I trust, Sir, that this slight sketch of the life and labours of one of the most eminent members of our body will not be deemed an unsuitable prelude to lectures which are expressly devoted to the elucidation of his most famous work.

Dr. Addison had been for nearly thirty years on the medical staff of Guy's Hospital when he discovered the existence of the disease to which Trousseau, if I mistake not, was the first to apply the name of 'Addison's Disease.' To quote his own words, he had, 'for a long period met with a very remarkable form of general anæmia, occurring without any discoverable cause whatever—cases in which there had been no previous loss of blood, no exhausting diarrhœa, no chlorosis, no purpura, no renal, splenic, miasmatic, glandular, strumous, or malignant disease;' and which he therefore termed 'idiopathic anæmia.' 'The disease,' he said, 'presented in every instance the same general character, pursued a similar course, and, with scarcely a single exception, was followed, after a variable period, by the same fatal result.' He further stated that the leading and characteristic features of the morbid state to which he would direct attention were 'anæmia, general languor and debility, remarkable feebleness of the heart's action, irritability of the stomach, and a peculiar change of colour in the skin, occurring in connection with a diseased condition of the supra-renal capsules.' 'The characteristic discoloration,' he says, 'pervades the whole surface of the body, but is commonly most strongly manifested on the face, neck, superior extremities, penis, and

scrotum, in the flexures of the axillæ, and round the navel. It may be said to present a dingy or smoky appearance, or various shades of deep amber or chesnut-brown; and, in one instance, the skin was so universally and so deeply darkened that, but for the features, the patient might have been mistaken for a mulatto.' This discoloration, he further remarked, was never attended by 'a harsh, dry condition of the surface.' To complete the picture, he added, in different passages, that there were occasionally actual vomitings, palpitation, and breathlessness on exertion, indications of disturbed cerebral circulation, and a strongly marked tendency to the formation of fat, in striking contrast to the failure and exhaustion observable in every other respect.¹

He had, therefore, before his mind's eye a distinct and definite morbid state, the nature and cause of which he sought to discover; and his discovery, when made at length, was no chance hit, but the result of long and careful investigation. Accurate clinical observation had first led him to discriminate, in the living patient, a remarkable train of obscure and apparently causeless symptoms, always of fatal augury; and, whilst searching out their hidden pathological cause, it was only after the careful exclusion of all other morbid conditions that he referred them to disease which he found seated in the supra-renal capsules.

It seems the more necessary to dwell upon this point, because, at a subsequent period, when Addison published his monograph on the disease he had discovered, he deviated from his first accurate conception and subjoined to his own true cases of the disease several other cases, which he had not seen during life; which, so far as could be known, had presented no constitutional symptoms that were not accounted for by other obvious diseases, and in which there was

¹ *On the Constitutional and Local Effects of Disease of the Supra-renal Capsules.* London, 1855. Pp. 2-8.

only very partial discoloration of the skin, not at all corresponding with the graphic description I have quoted from the first pages of his book. The mistake made by Addison with respect to these cases was the more remarkable, because, in the first place, as we have seen, he himself states that the chief motive of his investigation had been to determine the cause of certain symptoms, which had attracted his attention for the very reason that they could not be accounted for by any discoverable disease; and, in the second place, his great knowledge of skin affections must have made him familiar with the fact, that various organic and cutaneous diseases are attended by more or less pigmentation of the skin, though none of them by pigmentation presenting all the peculiar characters of the discoloration which he had described. These mistakes were doubtless due to the enthusiasm of mind attendant on his discovery, which led him to endeavour to include as much as possible within its scope; but, unfortunately, their effect has necessarily been to confuse his own true clinical and pathological description, and to give rise to misconceptions which are still far from being eradicated. We have Dr. Wilks's authority for the fact that, at a later period, Addison's views were more in accordance with our present knowledge; but, unfortunately, he did not live to revise his monograph.

As is known to have occurred with regard to most other discoveries, several previous observers had stumbled upon the facts which Addison discovered, but had failed to recognise the connection between them. Nearly thirty years before the date of Addison's discovery, his eminent colleague, Dr. Bright, had observed and recorded, in his celebrated 'Reports of Medical Cases,' a case of Addison's disease.¹ It was in all respects a well-marked example, and Addison included it in his monograph, where it stands as Case V. Mr. Sibley

¹ *Reports of Medical Cases.* Vol. II. London, 1831. P. 247.

also, in 1854, recorded in the Medical Register of the Middlesex Hospital the case of a patient of Dr. Seth Thompson's, who had presented all the chief symptoms of Addison's disease, including the discoloration of skin.¹ The late Dr. Kirkes likewise reported a case that had occurred in St. Bartholomew's Hospital several years before the publication of Addison's discovery, in which the asthenia, nausea, vomiting, and faintness seen in Addison's disease had been observed during life, and in which, after death, the only lesion found was the particular lesion of the supra-renal capsules which I shall hereafter show to be invariably associated with that disease.²

At a still more remote period, Dr. Schotte recorded, in the Halle Hospital Reports for 1823, a case of disease of the supra-renal capsules, in which the clinical history and symptoms and also the pathological appearances were those of an almost typical case of Addison's disease,³ and in all respects closely resembled those observed in the case of a girl who died of Addison's disease under my own care in 1865.⁴ It is true that neither in Dr. Kirkes's nor in Dr. Schotte's case was any discoloration of skin noted, but we need not therefore infer that it was necessarily altogether absent, seeing that in my own case, to which I have referred as almost parallel to Dr. Schotte's, the discoloration, though characteristic, was so slight that it might have been readily overlooked, more especially at a time when its importance as an indication of the nature of the disease was totally unknown. In such circumstances, we may be sure that the discoloration of the skin in Dr. Bright's and Dr. Seth Thompson's cases must have been well marked, or it would not have held the prominent place it does in the description of the symptoms. I refer to these two last cases with especial pleasure, because more striking illustrations

¹ See Appendix A, p. 142, Case xiv.

³ Case 198, Appendix B.

² Case 192, Appendix B.

⁴ See Appendix A, p. 107, Case III.

can scarcely be adduced of a truth which I have always deeply felt, and which was so well expressed by our last Harveian orator, Dr. West—namely, that ‘mere details, of which, when we have ascertained them most certainly, we yet cannot see the purport or the uses, will sooner or later surely find their place.’

I cannot, Sir, close these introductory remarks without some reference to two distinguished living members of our profession, but for whose labours Addison's discovery might possibly, at the time, have attracted much less attention. Soon after the publication of Addison's monograph, Mr. Jonathan Hutchinson gave a widespread impulse to the discussion of the subject, by collecting and publishing, in the ‘Medical Times and Gazette,’ a large number of cases, bearing upon the question of the reality of the disease and its relation to a morbid process in the supra-renal capsules. To Dr. Wilks we are even more deeply indebted for much of the advance made towards our present knowledge of the disease. In a succession of papers, published from time to time in ‘Guy's Hospital Reports,’ he described all the chief symptoms of the disease, and more especially the pathological appearances found in the supra-renal capsules, in a large number of cases, which had either occurred in the practice of the hospital, or had been submitted to him by other medical men for examination. He also prominently brought forward the truth, obscured by the admission of the spurious cases into Addison's monograph, that all genuine cases of the disease are due to one and the same characteristic lesion of the supra-renal capsules.

Notwithstanding the misconceptions which have prevented the general recognition of the truth of Addison's discovery, we have made, as I have said, much advance in our knowledge of the disease since Addison's time. More than three hundred cases bearing upon the subject have now been re-

corded; some in almost every country in which medical science is cultivated. Of these many are unfortunately so imperfectly reported that no positive conclusions can be drawn from them as to the existence of Addison's disease; and others again, which present neither the clinical nor pathological conditions described by Addison, are obviously not cases of Addison's disease at all, although many of them have been published as such. But, on the other hand, by far the larger number are true cases of the disease, having presented, in a more or less developed form, its characteristic clinical phenomena together with the particular lesion in the supra-renal capsules; whilst a very considerable proportion are what I may term 'typical' cases; that is to say, cases like Addison's own, in which not only the constitutional symptoms and discoloration of skin were more or less fully developed, but in which, also, no pathological lesion of any importance was found, except the one particular lesion in the supra-renal capsules. Several of these typical cases have come under my own care or observation,¹ and I pass now to the delineation of the living picture of Addison's disease, as it has repeatedly presented itself to me in these and other cases; unmistakable, almost at first sight, to one who held the key of the mystery supplied by Addison's discovery.

Progressive asthenia, often originating without any apparent cause and seldom dating from any definite period, an indescribable aspect of listlessness or depression, great languor and indisposition for exertion, remarkable weakness of the heart's action, and small, feeble, compressible pulse, loss of appetite, irritability of stomach, nausea, and retching, are symptoms almost invariably present. There are usually more or less severe and frequent pains in the loins, hypochondria, or epigastrium; and, not uncommonly, also tenderness on pressure in one or both hypochondria, with an almost spas-

¹ See Appendix A, pp. 101-125. Cases I. to VIII.

modic rigidity of the abdominal muscles, as if they were instinctively contracted in order to protect the more deeply seated parts from pressure. In advanced cases vomiting is seldom absent, and is sometimes spontaneous and irremediable; there are usually breathlessness and palpitation on making any muscular effort; frequent sighing or yawning, and sometimes persistent hiccup; generally faintness or giddiness on rising, or even on being raised up in bed.

Notwithstanding, however, the great feebleness, which is one of the invariable symptoms of the disease, there is, in uncomplicated cases, comparatively little or no real emaciation; but, on the contrary, together with some appearance of partial wasting, there is always a fair amount, and often a considerable excess, of subcutaneous fat, and the skin remains soft and smooth. The temperature, as a rule, is rather below the normal; the skin and the extremities are cool, if not cold, to the touch; the urine is often small in quantity, and generally of low specific gravity and deficient in solid constituents; the bowels are mostly confined; and the tongue usually remains clean and moist, until the advent of the typhoid symptoms, which often supervene during the last days of life.

The mind is often clear to the last; but so great is the prostration, in the latest stage of the disease, that the patient lies in a drowsy, semi-comatose state; from which he can, nevertheless, generally be roused by questions addressed to him, and he then gives pertinent though slow and monosyllabic answers. In this stage of the disease, the temperature sometimes falls considerably below the normal. Death takes place by asthenia, and sometimes, at the last, almost suddenly, apparently in syncope. There is, on the other hand, in many cases, towards the close of life, incoherence or delirium, sometimes low and muttering, sometimes more loud and active; and in this class of cases death often takes place in

coma. In one of my own most typical cases the patient had a convulsive fit, and lay for some hours before death with firmly closed jaws and great rigidity of the muscles of the abdomen and extremities. He was seemingly unconscious; but, whenever he was touched, convulsive twitchings took place, either of the face or of the whole body.¹

Various other symptoms, equally referable to disturbance of the nervous system—such as vertigo, numbness and anæsthesia of the face and arms, and more rarely of the lower extremities, dimness of sight and flashes of light before the eyes, noise in the ears and deafness, tremors, rigors, subsultus, and even epileptiform seizures—have been recorded in a considerable number of cases as occurring in the course of the disease, and in a few as having been the principal symptoms observed during life, except the invariable languor and debility. Another symptom which has been not unfrequently observed, especially near the close of life, is the exhalation of a fetid odour from the patient's body. It has been present in several of the cases which have been under my own care, and has appeared to me to be most marked in those persons whose skin had become most deeply and generally discoloured. It has been stated by some observers to be identical in character with the peculiar odour known to be exhaled from negro-skin, but on this point I have no personal experience. As far as my own observation goes, this fetid odour has only been developed towards the end of life, and it has seemed to me to partake somewhat of the cadaverous character.

To this sketch, of the characteristic constitutional symptoms of Addison's disease, I must add a description of the peculiar change of colour in the skin, as it has struck my own eye in every advanced case. This change of colour consists, as is generally known, in a gradual darkening of the skin of various parts of the body, or even of the whole body. The

¹ See Appendix A, p. 117, Case vi.

aspect of this discoloration, when fully developed, is very remarkable, and gives to the patient the appearance of belonging to one of the dark races of mankind. Most frequently it has a dusky, smoky, or yellowish-brown hue, but sometimes it is of an olive or green-brown colour, and, in the most deeply pigmented parts, approaches to the hue of negro skin.

The discoloration of skin in Addison's disease is not uniform over all parts of the body, but commences earlier and becomes deeper on some or all of the exposed parts, such as the face and neck, and the dorsum of the hands and fingers; and on some or all of those parts which are naturally the seats of more pigment than the general surface; namely, the axillæ, abdomen, groins, genital regions, nipples, and especially the areolæ. The deep discoloration of these last may, in my opinion, be regarded as one of the most decisive external signs of Addison's disease, and the appearance of small, well-defined black specks, like black moles or freckles, on already discoloured portions of skin, is, in my experience, another no less certain. Although sometimes universal, the discoloration is more frequently only distinctly obvious on certain parts of the body. Even in the latter cases, however, it probably affects in some degree the whole cutaneous surface; for, on microscopical examination of parts of the skin, which by contrast with the darker parts appeared normal, I have found deposited also in them, though in comparatively small quantity, the pigment which imparts the abnormal colour to the skin.

The transition from the darker to the paler shades of the discoloration on different parts of the body is never abrupt; even the darkest parts are never sharply defined patches, but merge insensibly into the lighter, or apparently normal, portions of the surface. There is, however, one marked exception to this rule. When the skin has suffered any super-

ficial abrasion or injury, as, for instance, when the patient has been blistered at some recent period, the injured parts not only become much darker than the surrounding portions of the surface, but they also present defined margins, coinciding with the extent of the cutaneous injury. The cicatrices of deeper injuries, on the contrary, usually remain pale, and are surrounded by a distinct though ill-defined border of more or less dark discoloration, contrasting strongly with the ivory-like hue of the cicatricial tissue. Thus, in two of my own patients, I found abruptly defined dark patches, in the first case on the hip, and in the second on the epigastrium, and I ascertained that they were the sites of blisters which had been applied some short time previously.¹ In the case of the second patient, who survived nearly two years, the dark patch gradually faded away, and before his death had ceased to be visible. On the other hand, in a third patient, the deep cicatrices caused by cupping on the hip, more than twenty years before, remained perfectly white, but each little scar was surrounded by a border of dusky discoloration.

I should add that it does not always require actual abrasion of the skin to excite a greater deposit of pigment in certain parts; slight local irritation of the surface appears, in not a few cases, to have produced the same effect. I have myself seen dark streaks on the skin corresponding with the lines of pressure exerted on particular parts by petticoat strings and garters, and the same circumstance has been noted by others. In a case recorded by Mr. Nicholson, in 1872, it is stated that the patient, a baker's lad, presented on his shoulders dark stripes, corresponding to the bands by which the basket he carried was slung at his back.²

The discoloration in Addison's disease is not entirely

¹ See Appendix A, p. 104, Case ii.; and p. 117, Case vi.

² Case 63, Appendix B.

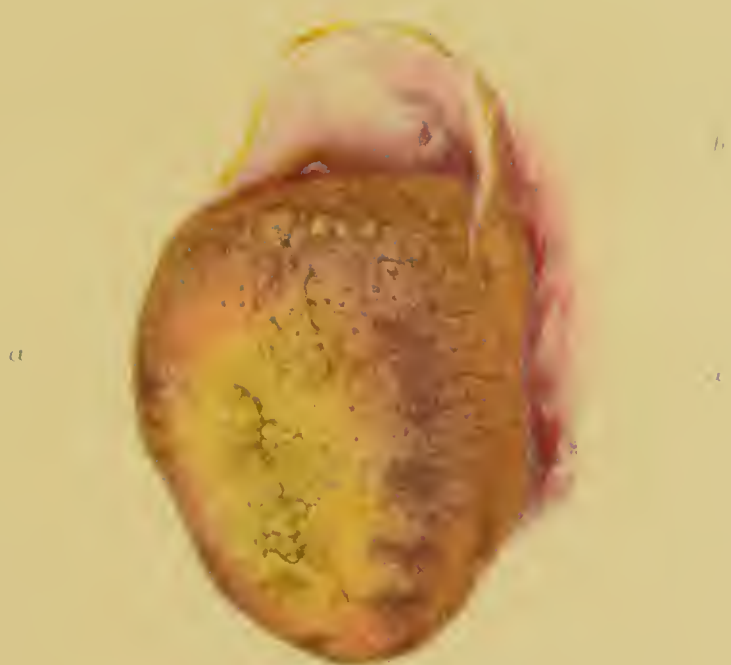restricted to the skin, being also frequently found upon the mucous membrane of the lips, cheeks, and gums, and also upon the tongue. On the lips it takes the form of an irregular bluish-black streak, running lengthwise, near the junction of the mucous membrane and the outer skin. It is seen on the gums and buccal mucous membrane in the form of irregular stains and patches, mostly of a brownish colour and with ill-defined margins. In two of my own cases the stains on the buccal mucous membrane have certainly corresponded with seats of irritation, produced by the pressure of ragged protruding teeth; but, in other cases, I have been unable to discover any such cause. These stains on the gums and buccal mucous membrane form another point of analogy between the discoloration in Addison's disease and the pigmentation natural to the dark races of men; for several lascars, who have come under my care in the Middlesex Hospital, have presented, on these parts, stains similar to those I have described. The discoloration of the tongue appears usually in more sharply defined stains of a purplish-black or somewhat inky hue; and, in my cases, these stains have always been situated near the free margins of the organ. (See Plate I.) On the other hand, the conjunctivæ always remain normal; and the contrast between their pearly whiteness and the dusky hue of the discoloured skin is very striking, and involuntarily recalls the similar contrast in the mulatto or negro countenance.

We see, therefore, that the discoloration of skin in Addison's disease usually begins, and eventually becomes deepest, on those parts which are naturally the most liable to become pigmented, either by exposure to sun and air, or by the excitement of certain physiological processes; and to these must be added such parts as may accidentally be subjected to the excitement of local irritation. In other words, this peculiar change of colour is, like many other pathological processes,

DESCRIPTION OF PLATE I.

This Plate shows the discoloration of the tongue in a case of Addison's disease. (Case X. Appendix A, p. 131.) From a drawing by Mr. W. Hurst.

- a.* Dark ink-coloured stains near the free border of the tongue.
- b.* Fungiform papillæ on the dorsum of the tongue, discoloured by deposit of pigment; the papillæ circumvallatæ remaining uncoloured.



merely an exaggerated, and therefore a morbid, development of a natural physiological process.

On microscopical examination of sections of the discoloured skin, the discoloration is seen to be due to deposit of yellowish-brown pigment in the deeper layers of the epidermis, more especially in the layer in immediate contact with the papillæ, whilst the more superficial layers and the true skin mostly remain free from pigment. (See Plate II. fig. 1.) Nevertheless, I have found, in several cases, traces of pigment in some of the more superficial scales of the epidermis, and also pigment-granules deposited here and there in the cutis.¹ (See Plate II. fig. 3.) Dr. Sidney Coupland also observed, on microscopical examination of sections of skin from one of my patients, pigment-granules, both isolated and in groups, in the connective tissue of the cutis, at some distance below the epidermic layer.² Drs. Meyer and Recklingshausen and Dr. Wolff likewise report, in their examinations of the skin of two patients who had died of Addison's disease, that they found many pigmented connective-tissue cells in the papillary portions of the cutis;³ and Mr. Schäfer observed in the same portions of the skin, from a patient of Dr. Ringer's, 'a number of irregularly-shaped corpuscles, apparently wander-cells, some of them perhaps connective-tissue cells,' containing a considerable amount of pigment.⁴ The principal part of the pigment, however, is in every case deposited in the cells of the rete Malpighii and accumulated round their nuclei, but some of it is generally free, and irregularly distributed around and amongst their cells. Possibly this portion of the pigment has also been originally contained in cells, which have disintegrated and allowed the colouring matter to escape and become diffused.

¹ See Appendix A, p. 114, Case v.; and p. 119, Case vii.

² See Appendix A, p. 124, Case vii.

³ Cases 58 and 103, Appendix B.

⁴ See Appendix A, p. 137, Case xi.

The colouring matter in the patches on the tongue is deposited in a corresponding situation with that in the skin, being seated in the lower cells immediately overlying the papillæ, the superficial layer of the epithelium remaining quite free from pigment. (See Plate II. fig. 2.) To those who have carefully examined the skin of negroes, lascars, or persons belonging to the other dark races of men, it will be obvious, from this description, that the differences between their normal colouring and the abnormal pigmentation of Addison's disease are merely differences of degree, although in the former they are natural physiological conditions, and in the latter pathological causes have operated to produce them.

Before quitting the description of the constitutional symptoms and discoloration of skin in Addison's disease, I must advert to one remarkable feature common to them both, to which I directed attention in my clinical lectures on the subject in 1866—I mean their paroxysmal mode of progress. This peculiarity has been noted also incidentally by several other observers in their reports of typical cases; but owing, no doubt, to the shortness of the time that the majority of the patients have remained under treatment, it has never hitherto been classed in its true place as one of the characteristic features of the disease.

The asthenia, the constitutional symptoms generally, and the change of colour in the skin, are all, it is true, progressive, but not steadily so. The course of the disease, on the whole, is slow and chronic; but it is subject to alternate exacerbations and remissions, usually in some degree dependent upon favourable and unfavourable circumstances, but sometimes also apparently quite independent of them. During the remissions, strength is in a great degree recovered, the appetite improves, the sickness abates, the discoloration becomes paler; and, above all, the patient's

DESCRIPTION OF PLATE II.

This Plate shows the microscopical appearance of sections of the discoloured patches on the tongue, and of the discoloured skin, in cases of Addison's disease.

FIG. 1. Section of pigmented patch on the tongue, viewed with a one-inch objective. The lower plumper cells clothing the papillæ are seen loaded with pigment; the sub-epithelial connective-tissue remaining quite uncoloured. (Case IV. Appendix A, p. 110.) From a drawing by Mr. Henry Arnott.

FIG. 2. Section of bronzed-skin. (Case VI. Appendix A, p. 117.) From a drawing by Mr. Henry Arnott.

- a.* Rough, scarf skin free from pigment.
- b.* Plumper cells of the rete mucosum, the deepest layer loaded with pigment.
- c.* Sub-epithelial connective-tissue free from pigment.

FIG. 3. Section of discoloured patch of skin, site of a recent blister. (Case V. Appendix A, p. 114.) From a drawing by Mr. Lens Aldous.

- a.* Brown pigment deposited in the deeper layers of the epidermis.
- b.* Scattered masses of pigment situated in the cutis vera.

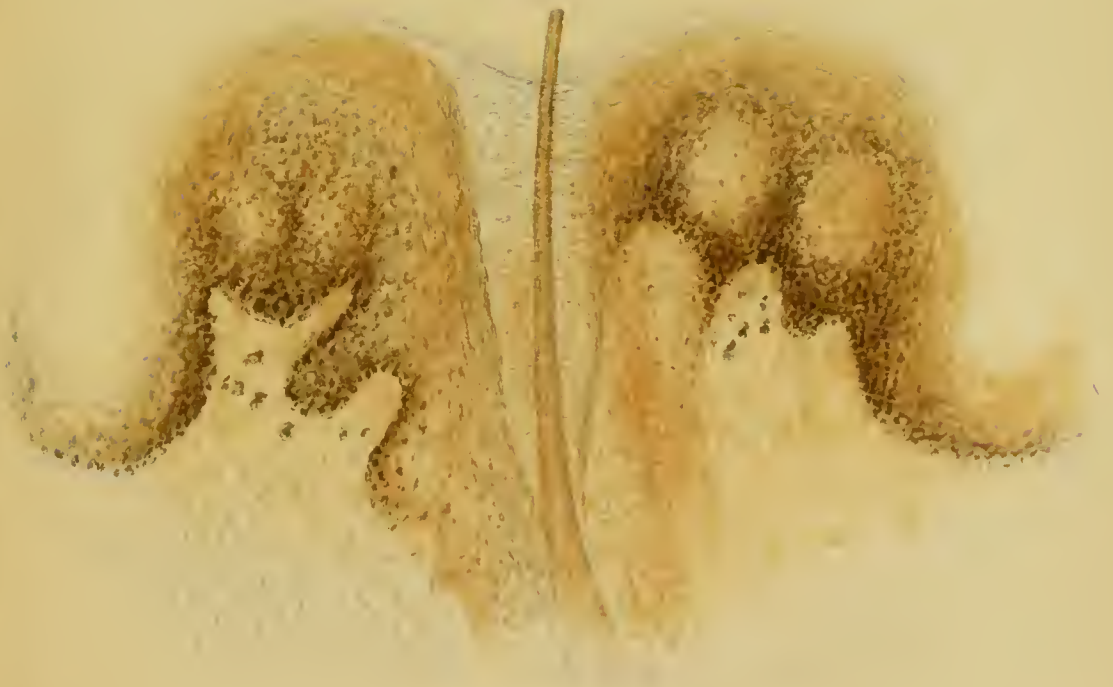Fig. 1




Fig. 2




Fig. 3



whole aspect bespeaks that a heavy weight has been lifted from his head. After each fresh exacerbation, however, the patient remains upon a somewhat lower level than during the previous remission. The recovery of strength and the abatement of other symptoms is less marked, and the skin, though paler than during the last exacerbation, is yet visibly darker than before it. Similar alternations may occur several times before the onset of the fatal paroxysm, but on each occasion the patient takes at least one downward step that he never regains. In two of my own patients these alternations were well marked, though they died in less than one and two years respectively after they came under my care; but, in two others, which were under my care for five and eight years respectively, the remissions in the symptoms and the paling of the discoloration were most striking. Both of these, I regret to say, have for the present drifted out of sight, but several similar cases have been recorded by other physicians after their termination.

Dr. Van Corput relates, in the case of a woman aged thirty, who died under his care in St. John's Hospital, Brussels, that during four years she had had three considerable periods of remission, and that the colour markedly alternated with the symptoms.¹ Severini records of a woman aged thirty-eight, that, during the months she was in hospital at Bologna before her death, there were several alternations of illness and improvement, and that 'the discoloration regularly alternated darker and lighter according to her state of health.'² Löwe and Wolff have also noted similar alternations of symptoms and colour in two very characteristic cases;³ and Dr. Ringer states, in his report of a case which he sent to me for exhibition at the Pathological Society in 1873, that 'with each slight improvement the discoloration

¹ Case 177; Appendix B.

² Case 75, Appendix B.

³ Cases 53 and 103, Appendix B.

of skin grew decidedly less, but on each relapse it became darker than before.¹

Although a slow chronic progress, with alternate exacerbations and remissions, is, as I have said, the usual course of the disease, it is by no means the only one. Many cases, particularly in younger subjects, run what may be termed a latent course; that is to say, the constitutional symptoms make their first appearance suddenly in a fully developed form, and produce fatal consequences in a few days.

This occurred in the case, already mentioned, of Dr. Seth Thompson's patient, a man aged twenty; who, although his skin had been getting dusky for six weeks, had exhibited no symptoms of illness until two days before his admission into the Middlesex Hospital, but grew worse so rapidly that he died on the following day.² The case of the young girl who died in the Middlesex Hospital, under my own care, in 1865, affords another illustration of this occasional latent course of the disease.³ She had returned home from an absence of six weeks in the country, apparently quite well, though her parents remarked that she looked sunburnt. This slight dinginess of complexion never left her, but she remained well for some months. Her father then regarded her as 'drooping' for three or four weeks, but she had no symptoms of illness, and continued to attend school until two days before she was brought to the hospital, when she presented all the constitutional symptoms of the disease in so fully developed a form that I diagnosed the case at first sight, although the discoloration was scarcely observable. She had suddenly become sick and cold, and her mother had given her a cathartic powder, which was followed by intense depression. Notwithstanding all possible care and restoratives, she died in a week. In Dr. Schotte's almost parallel

¹ See Appendix A, p. 139, Case XII. ² See Appendix A, p. 142, Case XIV.

³ See Appendix A, p. 107, Case III.

case, the patient, a girl aged fifteen, had been doing heavy work in the country, and, after complaining for only about four weeks of debility, powerlessness of limbs, and tendency to fall asleep, she was admitted into hospital with the symptoms of the disease in an advanced stage, and died the same night.¹ Risel also relates the case of a young man aged twenty, who, though his skin had been darkening for a year, and he had been feeling unwell for three months, continued to work as a bricklayer until two days before his death, when his strength suddenly failed him.² Without doubt these differences in the mode of onset and course of the disease are partly due to differences in the mode of progress of the supra-renal lesion, but the suddenly fatal termination in the first paroxysm is, I feel assured, like the accession of the successive paroxysms, in most cases, partly due also to the action of some depressing external influence. In the case of my patient this was, apparently, the active aperient administered by her mother, and in the case recorded by Dr. Schotte it was, probably, a dose of calomel and jalap given in the hospital.

One other peculiarity in the course of this remarkable disease must not be overlooked; namely, the very variable date of the appearance of the bronzing of skin, as compared with that of the characteristic constitutional symptoms. In a large proportion of the cases, as might be expected in a disease prevailing chiefly among the class of persons who become hospital patients, no note has been made on this point; and, in a great many other cases, it is reported that the appearance of the symptoms and discoloration of skin was simultaneous, or nearly so. Sometimes the appearance of the discoloration is mentioned as having soon followed that of the characteristic constitutional symptoms, and sometimes as having slightly preceded it. But, in a certain

¹ Case 198, Appendix B.

² Case 67, Appendix B.

number of cases, chiefly among the few that have occurred in the middle and higher classes, or have been longer than usual under medical observation, the interval between the appearance of the bronzing of skin and that of the constitutional symptoms has been accurately recorded.

In a typical case related by Addison and Wilks, the patient, a lady aged eighteen, was ill only four months, but the bronzing of skin had existed for a year.¹ In a case of Dr. Risdon Bennett's, published by Mr. Hutchinson, the patient, a boy aged eleven, had felt ill only a few weeks, but the bronzing of skin had been noticed for six months.² Löwe relates the case of a young woman aged twenty-seven, whose illness lasted four months, but who had remarked the gradual darkening of her skin on face, neck, hands, arms, and trunk, seven months before death, whilst she still felt quite well.³ In Risel's case, already mentioned, the darkening of the patient's skin had been noticed by his friends for at least a year before death, although, with the exception of a single attack of vertigo, which had only kept him from work one day, he had continued to feel perfectly well for nine months longer. In a few exceptional cases there has been a much longer interval between the first appearance of the bronzing of skin and that of the constitutional symptoms. Dr. Monro, of Dundee, has related the case of a clergyman's wife, in whom the discoloration of skin began, several years before death, on the forehead and gradually spread over the body, although the constitutional symptoms, which were quite characteristic, only made their appearance eight or nine months before death.⁴ In the case of a poor labouring woman, reported by Martineau for Drs. Cornil and Vast, the discoloration, which ultimately became general and intense, is said to have begun six years before death; whilst the ill-

¹ Case 5, Appendix B.

³ Case 53, Appendix B.

² Case 47, Appendix B.

⁴ See Appendix A. p. 172, Case, xxvi.

ness, with typical symptoms of Addison's disease, was only of about fifteen months' duration.¹ These were all typical cases of the disease, no lesion of the slightest importance having been found after death, except in the supra-renal capsules.

On the other hand, in about an equal number of cases of the same class, the development of the constitutional symptoms is recorded as having preceded the appearance of the discoloration of skin by several months, and sometimes by even longer periods of time. In a typical case, related by Mr. J. Moore, the patient, a clerk, had been failing in health for two years with constitutional symptoms indicative of Addison's disease, but the discoloration only became visible during the last six months of his life and, though characteristic, was never strikingly developed.² In a case of Mr. Kent Spender's, the patient, a young woman, aged twenty-one, was ill for a year with fully-developed constitutional symptoms of Addison's disease, but the discoloration only began to make its appearance three months before death on her face and hands, where it became intense, but it had not spread to the covered parts of the surface in any appreciable degree when the patient died.³ Dr. Robertson relates the case of a labourer who had suffered, for twenty-two months, from quite characteristic symptoms of Addison's disease, never having had any previous illness, but in whom the bronzing of skin only began on the face, arms, hands, and chest a year before death.⁴ A German factory manager, aged forty, is reported by Dr. Ploss to have had severe pains, supposed to be rheumatic, in the muscles of the back, from over-exertion, for more than two years before death, and to have been ill with typical symptoms of Addison's disease for a year; but the discoloration of skin only began, on his face and hands, about six months before death, and, although it spread some-

¹ Case 56, Appendix B.

² Case 62, Appendix B.

³ Case 77, Appendix B.

⁴ Case 68, Appendix B.

what, was still very partial when the patient died.¹ In a typical case, recorded by Dr. Tuckwell, the patient, a young woman aged thirty-one, was ill for a year with characteristic symptoms of Addison's disease, but the first appearance of the discoloration of skin was only about three months before death, when there was a sunburnt look of face, neck, shoulders, and fore-arms; which, however, spread and deepened during the short remainder of life into the typical bronzed skin of Addison's disease.² In one or two cases, the interval between the development of the constitutional symptoms and that of the bronzing of skin seems to have been considerably longer; for Dr. Andrew reports a typical case of Addison's disease which was under the care of Dr. Black in St. Bartholomew's Hospital, in which the patient had been ailing for three years with debility and loss of appetite before the discoloration of skin first made its appearance, two years before death.³ In another case, related by Mr. Workman, in which the disease apparently followed an injury to the loins, the patient suffered for four years from progressive debility, lumbar pains, and occasional sickness; but the face and upper extremities became bronzed only during the last eighteen months of life.⁴

I must now turn to the consideration of the pathological lesion, which Addison's observation of the clinical phenomena he described led him to seek for as necessary to explain them, and which he only briefly mentions as 'a diseased condition of the supra-renal capsules.' He evidently believed that any diseased condition of those organs might produce the same effects, for he recorded in his monograph, in connexion with the cases of spurious bronzing of skin to which I have referred, other diseased conditions of the supra-renal

¹ Case 167, Appendix B.

² Case 82, Appendix B.

³ Case 6, Appendix B.

⁴ Case 183, Appendix B.

capsules totally different from the particular diseased condition which he had found in his own cases.

This particular condition is, nevertheless, well described, as regards its naked-eye appearances, in the report of the post-mortem examination of one of his own most typical cases. 'Each supra-renal capsule,' he records, 'was completely destroyed and converted into a mass of strumous disease, the latter of all degrees of consistency. The left supra-renal capsule had formed at the upper part a close connexion with the outer coat of the stomach. The upper part of this capsule seemed fluid and of the colour of pus, the lower firmer, and of the consistency of putty. The right capsule had all degrees of consistency from the bottom to the top, the lower part almost fluid and resembling pus, the centre putty-like; and above this matter could be detached in flakes, and at the top it was quite earthy, separate angular pieces being easily detached.'¹ Addison, however, gives no description of the microscopical appearances in this case, nor in any other, excepting one which was submitted to Dr. Hodgkin for examination. Dr. Hodgkin's report, though brief, corresponds in its main points with the reports of more recent observers. 'The capsules,' he says, 'when cut into, seemed to consist of a firm, slightly transparent, reddish basis, interspersed with irregular spots of opaque yellow matter, the whole bearing a strong resemblance to an enlarged mesenteric gland mottled with tubercular deposit. The naked eye could discover no trace of cystiform arrangement, and the opaque matter, when examined with the microscope, exhibited a copious amount of fatty matter, but no nucleated cells.'² These characters I have frequently verified in genuine cases of Addison's disease, as being all quite accurate so far as they go.

¹ *On Disease of the Supra-renal Capsules*, p. 18, Case III.

² *Loc. cit.*, p. 28.

I shall now proceed to describe more fully the pathological change in the supra-renal capsules, as I have observed it, in careful post-mortem examinations of the same typical cases from which I have already drawn the clinical picture of the disease.

The capsules are generally enlarged, hard, and nodulated, though in rare cases they are of normal, or even less than normal, size. On section they scarcely ever present any trace of the distinction between cortex and medulla, which is so obvious in the normal condition of the organs. In all the fresh specimens I have seen, the cut surfaces have presented a marbled appearance, from the admixture of two materials of different colours and consistence. One of these materials is a semi-transparent tissue, of firm consistence and of a grey or greenish-grey colour, at least when quite freshly cut, but on being exposed to the air it rapidly assumes a reddish hue. (See Plate III. fig. 2.) The other material is of an opaque yellow or cream colour, and generally assumes the form of irregular roundish masses, of a more or less friable consistence, embedded in the translucent tissue, from which they can in many cases be easily enucleated. On close examination, intermediate gradations will often be seen between the translucent parts and the opaque cheesy nodules; and sometimes, again, cretaceous granules, or small masses, formed by the hardening of the cheesy matter, are felt to grate under the knife. More rarely the whole cheesy material dries up and hardens into calcareous masses, and it is in these rare cases that the capsules are smallest. (See Plate III. fig. 1.) Not unfrequently, on the other hand, the caseous matter softens down into collections of thick creamy fluid, called abscesses by some observers, which are found occupying larger or smaller cavities in the diseased capsules. (See Plate III. fig. 3.) In some cases the whole central part of the organ constitutes

DESCRIPTION OF PLATE III.

This Plate shows the naked-eye appearance of the supra-renal capsules in different stages of Addison's disease of those organs. From drawings by Mr. W. Hurst.

FIG. 1. Section of one of the supra-renal capsules from Dr. Greenhow's patient, J. D. (Case VI. Appendix A, p. 117.)

Illustrates the calcareous change sometimes undergone by the original inflammatory exudations of Addison's disease.

FIG. 2. Section of one of the supra-renal capsules from Dr. Greenhow's patient, W. B. (Case II. Appendix A, p. 104.)

Illustrates the ordinary marbled appearance of the inflammatory exudation into the supra-renal capsules in Addison's disease.

a. Opaque yellow masses having undergone caseation.

b. Semi-transparent tissue forming the matrix in which the cheesy nodules are embedded. (This portion of the capsule was of a greenish-grey colour when freshly cut, but, after exposure to the air for a short time, acquired the pink hue shown in the Plate.)

FIG. 3. Section of left supra-renal capsule from Dr. Bristowe's patient, R. B. (Case X. Appendix A, p. 131.)

Illustrates the softening down of the inflammatory exudation into a creamy puriform fluid.

Fig. 1.




Fig. 2.

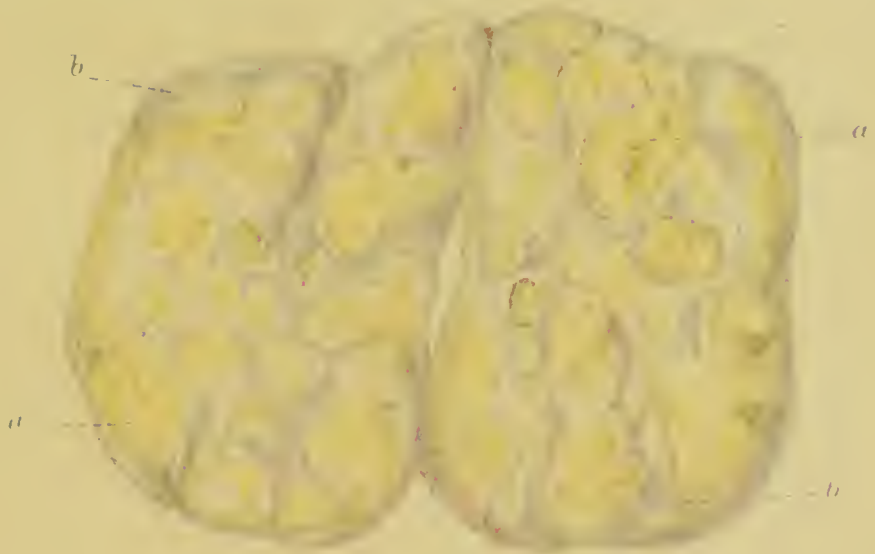

Fig. 3.

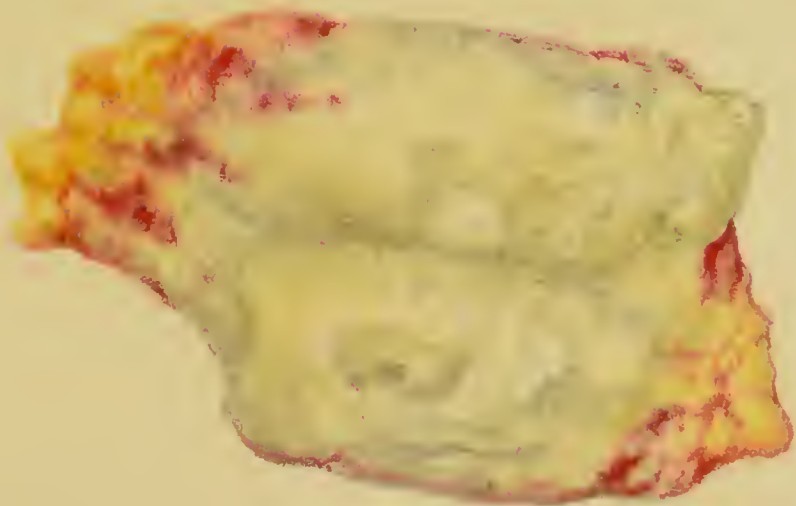

Fig. 1



Fig. 2




Fig. 3



Fig. 4

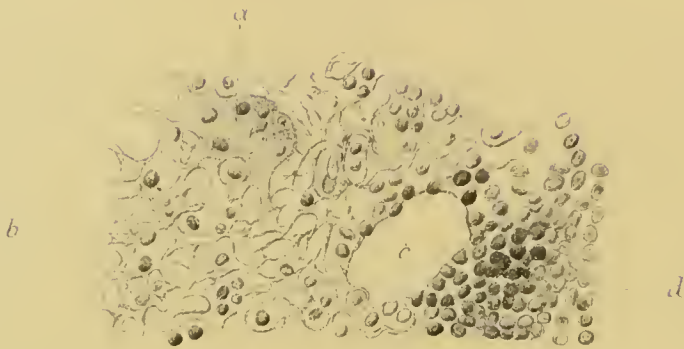


Fig. 5





Fig. 6



DESCRIPTION OF PLATE IV.

This Plate shows the microscopical appearances of the suprarenal capsules in different stages of Addison's disease of those organs.

FIGS. 1, 2, and 3. From sections taken from the left suprarenal capsule of Dr. Greenhow's patient, E. W. (Case III. Appendix A, p. 107.). From drawings made at the time by Dr. Burdon Sanderson.

Fig. 1. Oval and round nuclei embedded in a finely granular stroma; from the pinkish semi-translucent portion of the capsule, after the addition of weak acetic acid.

Fig. 2. Connective-tissue from the same part of the organ, after the addition of acetic acid.

Fig. 3. The same; treated with water only.

FIGS. 4, 5, and 6. From sections taken from the right suprarenal capsule of Dr. Greenhow's patient, A. H. (Case VII. Appendix A, p. 119), and stained with logwood. From a drawing by Dr. Sidney Coupland.

Fig. 4. *a.* Irregular granular mass of protoplasm, 'giant-cell,' containing several nuclei and sending off processes which unite with the meshes of the reticulum.

b. Reticulum of fine homogeneous fibrils enclosing nuclei in its meshes.

c. Lumen of a vessel cut across.

d. Infiltration of new cell-growth.

Fig. 5. Increase of reticular tissue at the expense of the nuclei.

Fig. 6. (From another view of same section as Fig. 5.) Bundles of fibres leaving spaces which are occupied by nuclei.

one large cavity filled with creamy fluid; but more commonly, there are, if any, several small separate cavities, the fluid in which is of the same character, but of various degrees of thickness.

It follows obviously, from this description, that the proportions of the translucent and opaque materials found in the diseased capsules differ greatly in different cases. In some few cases the translucent substance constitutes nearly the whole of the mass; in others the yellow friable matter greatly predominates, whilst in others again the normal tissue is almost entirely replaced by calcareous masses, or else by creamy fluid. All these gradations, however, depend solely upon the duration and upon the more or less acute or chronic course of the disease; the morbid process is identical in them all; a fact which, as Dr. Wilks pointed out, gives a greater definiteness to the disease than Addison himself conceived it to possess.

On microscopical examination the translucent substance is seen to consist of a fibrillated stroma, containing numerous lymphoid corpuscles. In some cases these corpuscles are arranged in rows between bundles of fibres, in others they are contained in a delicate reticular stroma (see Plate IV. fig 4). The opaque cheesy material is formed of amorphous granular matter, mixed up in variable proportions with irregular-shaped, shrunken cells, nuclei, and oil. The creamy-looking fluid contained in cavities of the capsules consists mainly of oily débris. It is evident, from these microscopical appearances, that the morbid process in the capsules consists, primarily, in their infiltration by an inflammatory exudation of low type, which destroys the natural structure of the organs, and finally itself undergoes caseous degeneration.

In every one of my own cases, and in a very large number of those which have been most carefully examined and reported on by other observers, clear evidence of inflammation

in the cellular envelopes of the capsules has been afforded by the great proliferation of their connective tissue, and also by the existence of firm adhesions to neighbouring organs, such as the diaphragm, liver, pancreas, vena cava, kidneys, or stomach. It is probable, therefore, that in many other cases these conditions have been overlooked, or have remained unreported, their significance not being understood. Of course such extensive overgrowth of connective tissue around the capsules cannot fail to invest the nerves of both the supra-renal and solar plexuses with dense indurated tissue; and, accordingly, when these nerves have been thoroughly examined, their fibrous investment has been found to be hypertrophied.

The first careful dissection of the nerves in the neighbourhood of the supra-renal capsules, in a case of Addison's disease, was made by Dr. Habershon, who had previously published, in the *Guy's Hospital Reports* for 1856, a very valuable paper on the Abdominal Sympathetic and its Connections with the Phrenic and Pneumo-gastric Nerves. The results of his dissection of the nerves, in the case to which I have referred, were published in 1854 in the same series of Reports.¹ He found the semilunar ganglia, and the branches of the nerves proceeding to the capsules, surrounded by an unusual quantity of dense fibrous tissue.

In several of my own cases the same condition of the nerves has been found, though they have not always been so thoroughly dissected out of the mass of hard tissue in which they were embedded. My colleague, Dr. Cayley, however, several years ago, at my request, very carefully examined the supra-renal nerves in the body of a man who had died of Addison's disease in the Middlesex Hospital under Dr. Stewart's care.² He found the nerves proceeding from the

¹ *Guy's Hosp. Reports.* Third series. Vol. x. Lond., 1864. P. 83.

² See Appendix A, p. 116, Case v.

semilunar ganglia to the supra-renal capsules, and especially one branch of the great splanchnic nerve, at least twice the size of the same nerves in a healthy subject, dissected at the same time for the purpose of comparison. On microscopical examination, he ascertained that this increased size of the nerves was due to an increase in the fibrous investment of the nerve-bundles. Dr. Tuckwell, of Oxford, also made a very complete and skilful dissection of the nerves in a case of Addison's disease, recorded by him in the *St. Bartholomew's Hospital Reports* for 1873; in which case, as in two others he had previously dissected, he found 'decided evidence of thickening, extending from the surface of the capsule to the supra-renal plexus, the semilunar ganglia, and thence up the great splanchnic nerve.'¹ This thickening of the nerves was found, on microscopical examination, to be caused by hypertrophy of their fibrous investment, and not by any apparent change in the nerve-fibres themselves.

A similar condition of these nerve-plexuses in cases of Addison's disease has been verified also by several eminent foreign pathologists. Rindfleisch states, in his report on the microscopical examination of the nerves in a case of Kulhmann's, that he found two large nerve-trunks, bound up in the firm adhesions which attached the diseased capsules to the neighbouring parts.² Professor Tigri found, in a case of Burresi's, the semilunar ganglia considerably enlarged, and the nerve-fibres forming the solar plexus thickened by hypertrophy of the neurilemma, whilst the true nerve portions were small.³ Hertz also reports that he found the cœliac plexus, particularly the semilunar ganglia, enclosed in hard connective tissue, with considerable thickening of the connective-tissue sheaths of the nerve-fibres going off from the ganglia;⁴ and

¹ *St. Bartholomew's Hosp. Reports.* Vol. VII. Lond., 1871. P. 73.

² See Appendix A, p. 181, Case xxx.

³ See Appendix A, p. 179, Case xxix.

⁴ See Appendix A, p. 177, Case xxviii.

Wolff observed the nerves of the solar plexus and semilunar ganglia, and the nerve-branches which go to the capsules, surrounded by a tough thick envelope of connective tissue.¹ Bartsch, Van Andel, and others have reported similar conditions of the nerves.²

In almost every case I have seen, the dense connective tissue surrounding the capsules has contained some enlarged lymphatic glands, and the same has been reported very frequently by other observers. The mesenteric and retro-peritoneal glands in the neighbourhood of the capsules are also frequently found to be enlarged. On section, these enlarged glands sometimes present only the normal appearance, but more commonly they are firm, glistening and pale-coloured, and, not unfrequently, in process of caseation. Microscopical examination of these enlarged glands sometimes reveals no obvious change of structure; in other instances, when they have been hard and glistening, the fibrous stroma has been seen on section to be much increased and the glandular elements atrophied.

There is another morbid appearance, first noted by Dr. Addison himself,³ which has been so frequently observed, both by myself and others, in cases of Addison's disease, that it must be ranked among the characteristic, though perhaps not quite invariable, lesions incident to the disease. I mean enlargement of the agminated and solitary glands of the small intestine, and sometimes likewise of the solitary glands of the large intestine. In many cases, also, including one of Addison's cases, reported on by Dr. Hodgkin,⁴ the mucous membrane of the stomach, especially towards the pylorus, has presented a mammillated appearance, and the mucous surface has not unfrequently been covered with thick tena-

¹ See Appendix A, p. 175, Case xxvii.

² See Appendix A, p. 184, Case xxxii.; and p. 182, Case xxxi.

³ *On Disease of the Supra-renal Capsules*, p. 20.

⁴ *Loc. citat.*, p. 26.

Fig 1.






Fig 2





DESCRIPTION OF PLATE V.

Fig. 1 shows the microscopical appearance of a section taken from one of the supra-renal capsules in a case of Addison's disease, and illustrates the manner in which the new-growth encroaches upon and destroys the normal structure of the organ. From a drawing by Dr. Sidney Coupland.

- a.* Remains of one of the normal cortical cell columns of the capsule; surrounded by
- b.* Nuclear new growth; and
- c.* Imperfectly fibrous new growth.

Fig. 2. Shows the microscopical appearances of a vertical section through the mammilated mucous membrane of the stomach, in the pyloric region, in a case of Addison's disease. (Case VIII. Appendix A, p. 125.) The section was almost entirely limited to the mucosa. From a drawing by Dr. Sidney Coupland.

- a.* Mucosa infiltrated with small round cell-like lymph-cells. The surface epithelium is wanting, and the gastric tubules are shrunken and atrophied.
- b.* Cavity left by the breaking down of the summit of one of the mamillæ. The mamilla formed by the exuberant new-growth is here seen displacing the tubuli, and, but for its situation in the mucosa, resembling a solitary gland.
- c.* Lower extremities of gastric tubules.
- d.* Muscular coat.
- e.* Vein.
- f.* Artery.

cious grey mucus. Small ecchymoses and, more rarely, superficial abrasions, or small ulcers, have also been found on the mucous membrane of the stomach, and in a few instances on that of the large intestine. Careful microscopical examinations of the mucous membrane of the stomach, in two different cases, by Dr. Coupland and Mr. Schäfer, have shown that the mammillations are caused by numerous overgrowths of lymphoid tissue around and between the gastric tubules. (See Plate V. fig. 2.) Some of these mammillations presented small depressions in their centres, which were ascertained by Mr. Schäfer to be due to 'a breaking down and opening into the surface of the summit of the patches.'¹ Probably these depressions indicate the first stage of the small ulcers, which have been reported by other observers as occurring on the gastric mucous surface.

Lastly, I must not omit to mention one other morbid organic change, which has been too often recorded in cases of Addison's disease to be passed over here, although I have no personal experience of its presence. In a very considerable number of chronic cases, including cases reported by Addison and Habershon,² the spleen has been found to be enlarged, sometimes very greatly enlarged, and usually also dark-coloured and soft. It is worthy of remark that in very few of these cases had the patient, so far as was known, suffered from intermittent fever. There has, however, been no considerable enlargement of the spleen in any of the cases which have been under my own care, and it is therefore certain that this lesion, though undoubtedly an occasional, is by no means an essential, feature in the morbid anatomy of Addison's disease.³

¹ See Appendix A, p. 138, Case XI.; and p. 129, Case VIII.

² *On Disease of the Supra-renal Capsules*, p. 20; and Case 32, Appendix B.

³ Softening of the brain, with effusion beneath the arachnoid and into the ventricles, and pericarditis with effusion, have also been recorded in several cases of Addison's disease. They have not yet been so frequently observed as

Having thus delineated, as I believe, the true clinical and pathological features of Addison's disease, I must, in conclusion, observe, in order to prevent misunderstanding, that it is only in a certain number, even of the typical cases, that the striking clinical phenomena which I have described are all fully developed. The progressive asthenia, muscular debility and feeble circulation, are invariably present in typical cases; and, in my experience, neither the loss of appetite and vomiting, nor the dyspnoea and faintness on exertion, have ever been absent in the later stages of the disease; but there is not perhaps one of the other symptoms I have enumerated which is invariably present. Every physician is sufficiently aware that this is equally true with respect to every other organic disease. It is only in the comparatively small number of cases in which an organic disease runs a long, uncomplicated, chronic course, that we can expect to observe the full development of all its characteristic symptoms. The absence of some of these, therefore, in complicated cases, or in cases of short duration, cannot be regarded in Addison's disease, more than in any other organic disease, as militating against the connection between such symptoms and the pathological condition with which they are associated.

to justify me in ranking them now among the secondary consequences of the disease; but it is quite possible that further researches may lead to their being placed in the same category as the enlargement of the spleen.

LECTURE II.

ADDISON'S DISCOVERY NEITHER GENERALLY ACCEPTED NOR GENERALLY UNDERSTOOD; ACCEPTANCE MAINLY RETARDED BY PREVALENT MISCONCEPTIONS—EVIDENCE IN PROOF OF RELATION BETWEEN CLINICAL SYMPTOMS AND ONE PARTICULAR LESION OF SUPRA-RENAL CAPSULES—STATISTICS OF PUBLISHED CASES—TYPICAL CASES; CASES APPARENTLY TYPICAL; CASES WITH OTHER CO-EXISTING DISEASE; IMPERFECTLY RECORDED CASES; CASES WITHOUT DISCOLORATION OF SKIN—MISCONCEPTIONS—DISCOLORATION OF SKIN MAY OCCUR WITHOUT DISEASE OF SUPRA-RENAL CAPSULES; DISCOLORATION IN VAGABONDS; IN PITYRIASIS VERSICOLOR; IN SYPHILIS; IN UTERINE DISEASE; IN MALARIOUS POISONING AND HEPATIC DISEASE; IN PHTHISIS—CASES OF DISCOLORATION OF SKIN WITHOUT DISEASE OF THE SUPRA-RENAL CAPSULES; EXPLANATION OF THEIR TRUE CHARACTERS—DISEASE OF SUPRA-RENAL CAPSULES MAY EXIST WITHOUT DISCOLORATION OF SKIN; CASES OF CANCER, AMYLOID DISEASE, FATTY DEGENERATION, APOPLEXY, AND TUMOURS OF SUPRA-RENAL CAPSULES—CASES OF SPURIOUS BRONZING OF SKIN WITH VARIOUS DISEASES OF SUPRA-RENAL CAPSULES; EXPLANATION OF THEIR TRUE CHARACTERS—CASES OF ADDISON'S DISEASE ERRONEOUSLY CLASSED AS CASES OF CANCER OF THE SUPRA-RENAL CAPSULES—CASES IMPERFECTLY DESCRIBED OR OF DOUBTFUL NATURE.

MR. PRESIDENT AND GENTLEMEN,—I said in my first lecture that Addison's discovery has not yet been generally accepted, nor even generally understood. The connection between the peculiar constitutional symptoms and bronzing of skin, which attracted Addison's attention, and the disease in the supra-renal capsules, which he found in association with them, is still regarded, by many, rather as a matter *sub judice* than as a certain and definite relation. This scepticism is, no doubt, partly due to the fact that the relation between the organic lesion and the clinical symptoms, in Addison's disease, is much less susceptible of obvious explanation than the relation between the organic lesion and the clinical symptoms in many other diseases. To this part of the question

I shall refer in my next lecture; but, in the meanwhile, it is evident that the obscurity of the relation can be no bar to the recognition of its reality, if this latter be substantiated by a sufficient number of well-attested facts. The general acceptance of Addison's discovery has, however, been mainly retarded by the prevalence of misconceptions which have prevented it from being generally understood. I propose therefore, in to-day's lecture, to review, in the first place, the evidence proving the reality of the relation; and, subsequently, to deal with the misconceptions which have interfered with its general recognition.

If it were only that so obscure a disease, as one particular lesion in the supra-renal capsules, has been often correctly and publicly diagnosed from the symptoms supposed to be connected with it, it seems difficult to understand that the connection should not be universally allowed to have passed out of the region of theory into that of established truth. I have myself, on twelve occasions, diagnosed Addison's disease of the supra-renal capsules in the presence of medical students and friends, and in eight of these cases the correctness of the diagnosis has been verified at the autopsy. Two of the twelve patients died at a distance from London, and the remaining two are still living. There have now, indeed, been so large a number of cases similarly diagnosed that it is impossible to enumerate them, and the evidence which they afford of the reality of the connection between the clinical symptoms and the pathological condition found to co-exist with them, would alone seem to me unanswerable.

It is still argued, however, in some quarters, both at home and abroad, that, although a diseased condition of the supra-renal capsules may frequently coincide with certain clinical symptoms, it is by no means essential to their development, and consequently cannot be their cause. I shall therefore proceed to show that the whole weight of the evidence, fur-

nished by the large number of cases bearing upon the subject which have been published since Addison's time, goes to prove that the coincidence of the clinical symptoms of Addison's disease with one particular lesion of the supra-renal capsules is the almost invariable rule; the exceptions to which, if duly investigated, may be satisfactorily explained. I shall also be able to show that this particular lesion is essential to the development of those symptoms; in so far that medical records have, as yet, produced no single case, exhibiting the really characteristic features of Addison's disease, in which this particular lesion of the supra-renal capsules was not also present.

For many years past I have, from time to time, collected all the cases I could find in the Transactions of Medical Societies, or in the British or foreign medical journals, published under the names of Addison's disease, Bronzed-skin disease, disease of the supra-renal capsules with or without bronzing, and bronzing of skin without disease of the supra-renal capsules. I cannot, however, presume that none have escaped me, for I have not had access to all the medical works in which cases may have been recorded, and latterly my leisure for such researches has been less than in former years. This collection amounts now altogether to upwards of 330 cases, in all of which there is a more or less complete report of the morbid appearances found after death; for I have disregarded, as useless for my present purpose, all those cases which have not undergone the test of post-mortem examination. Of this total collection of cases a very considerable number fall into three classes, which must be set aside till the later part of this lecture. One of these classes includes all the cases in which no disease at all was found in the supra-renal capsules after death, although some bronzing or discoloration of skin had existed during life; the second, all those cases in which the disease found in the supra-renal

capsules was of an altogether different nature from the particular lesion characteristic of Addison's disease; whilst the third class comprises all those cases in which the description of the condition of the supra-renal capsules leaves doubtful the nature of the lesion, and even, in some instances, the existence of any lesion at all. After deducting the cases which fall into these three classes from the total number collected, there remain 230 cases, in all of which the supra-renal capsules are reported to have undergone the one particular morbid change which I have described.

As regards the reality of the relation between this particular lesion of the supra-renal capsules and the clinical symptoms found in association with it, I take first, because most indisputable, the evidence furnished by 103 of these cases, which may be classed in one group as typical cases of Addison's disease;¹ typical, as corresponding in all their main facts with the outline of Addison's own description; more or less typical, according as the length of their course, or the opportunities of observation, have enabled their reporters to present, more or less in detail, the remarkable features which fill in that outline.

In all these 103 cases, the train of constitutional symptoms and the peculiar change of colour in the skin, such as I have described them, were observed during life, in a more or less fully developed form.

In all the 103 cases the supra-renal capsules were found, after death, to be diseased; and the disease was, in every case, found to be of the same nature, corresponding with one or other of the stages of the particular lesion which I have described.

Lastly, in none of the 103 cases did any other organic lesion exist which could be of the slightest importance.

¹ See Appendix B, Group 1. Cases 1-103.

There can surely be no reasonable doubt that in every one of these cases the disease in the supra-renal capsules was, either immediately, or mediately through its consequences, the sole cause of death.

But although, with a view to adducing first the most unanswerable argument to be derived from the facts collected, I have placed in a group by themselves these 103 cases, which I have called typical, there are two other groups of cases, which in reality afford scarcely less convincing proof of the connection between the clinical symptoms of Addison's disease and the one particular lesion in the supra-renal capsules.

In 16 more cases, the imperfection of the reports alone prevents their being included in the typical group.¹ In some of these cases the constitutional symptoms, discoloration of skin and condition of the capsules, were all typical of Addison's disease, and no symptoms of any other disease were observed during life, but the state of the other organs of the body was not examined after death, so as to place beyond question the absence of any co-existing disease. In the remainder of the 16 cases, whilst the absence of any co-existing disease is duly reported, the descriptions of the train of constitutional symptoms and of the discoloration of skin, though characteristic so far as they go, are too meagre to entitle them to be placed in the typical group.

Again, in no less than 64 more cases the constitutional symptoms and discoloration of skin characteristic of Addison's disease were observed during life in a more or less fully developed form; but in all these cases some other disease was found co-existing with the disease in the supra-renal capsules, giving rise in many instances to symptoms of its own, independent of those characteristic of the supra-

¹ See Appendix B, Group II. Cases 104-119.

renal lesion, and in a few instances modifying or obscuring some of the usual symptoms of Addison's disease.¹

We have thus altogether, out of the 230 cases in which the one particular lesion of the supra-renal capsules has been found after death, no less than 183 cases in which the peculiar change of colour in the skin, and some, at least, of the constitutional symptoms, characteristic of Addison's disease, were observed during life.

In 19 of the remaining 47 cases the reports of the constitutional symptoms, discoloration of skin, and state of other organs, are either altogether wanting, or are too imperfectly recorded to warrant any conclusions being founded upon them.² Amongst this number are included several cases which occurred before the announcement of Addison's discovery.

These 19 cases being necessarily left out of the question, there remain only 28 of the 230 cases still to be accounted for; and in these 28 cases it is distinctly stated either that no bronzing of the skin existed, or that it was almost inappreciable.

In 18 of these 28 cases the disease in the supra-renal capsules co-existed with other serious wasting diseases, which were the efficient cause of death.³ These predominant diseases were almost all of a tubercular or strumous character.

In five out of the eighteen cases the predominant co-existing disease was acute tuberculosis or acute phthisis;⁴ in seven other cases it was general tuberculosis, or phthisis, running a less rapid course;⁵ whilst in three cases there were open spinal or lumbar abscesses, connected with caries of the vertebræ.⁶

¹ See Appendix B, Group III. Cases 120-183.

² See Appendix B, Group IV. Cases 184-202.

³ See Appendix B, Group V. Cases 203-220.

⁴ Cases 208, 209, 213, 214, 219.

⁵ Cases 204, 206, 210, 212, 215, 217, 218.

⁶ Cases 203, 207, 211.

Of the remaining three cases, one was associated with Bright's disease, one with extensive disease of brain and kidneys, and the third with liver disease and ascites.¹

Three of these eighteen cases have occurred in the Middlesex Hospital, and I was present at the post-mortem examination of one of them, and verified the absence of all trace of discoloration of the skin; but the patient, a boy aged thirteen, who died under Mr. Shaw's care, had been rapidly worn down by profuse discharge of pus from an abscess connected with carious vertebræ.² In these cases, generally, no constitutional symptoms are reported to have been developed except those of the predominant disease; but, in one or two of them, some of the peculiar constitutional symptoms characteristic of the supra-renal lesion seem to have been also present, though not in a sufficiently marked form to give rise to any suspicion of their real cause, until it was discovered at the autopsy. Thus in the second of the three Middlesex Hospital cases to which I have referred, Dr. Thompson recorded in his case-book that the patient, a man aged 40, who died after an illness of only six weeks with extreme disorganisation of the lungs, had, before he took the cold which brought on his rapidly fatal illness, been suffering from 'languor, failure of appetite, and vomiting after food.'³ The third case, which was one of psoas abscess from vertebral disease, was under the care of Mr. Hulke, who stated in his notes that the patient suffered from 'a degree of feebleness quite out of proportion to the loss of flesh, a very irritable stomach, and obstinate constipation.'⁴ In this last case it was obvious that the supra-renal lesion was in a comparatively early stage when the patient died, for the inflammatory exudation, with which

¹ Cases 205, 216, 220.

² Case 203.

³ Case 208. See also Appendix A, p. 140, Case XIII.

⁴ Case 211. See also Appendix A, p. 143, Case XV.

the right capsule was infiltrated, had not yet undergone the process of caseous degeneration, and the left capsule appeared to be still healthy.

The inference which I draw from the absence of bronzing of skin, and most frequently also of the constitutional symptoms, in these eighteen cases, is, that in most of them the diseases co-existing with the disease in the supra-renal capsules proved fatal before this latter had produced any of its characteristic effects; whilst, in a few of them, the end was probably hastened by the specific debility and depression which are usually the first symptoms of the supra-renal disease, but which in such circumstances would naturally pass unnoticed. As we have seen, Dr. Thompson's and Mr. Hulke's patients did both present such symptoms, distinct from those of the more acute diseases which caused their deaths; a fact which seems to confirm the inference I have drawn with respect to these eighteen cases.

The other 10 cases, in which there is reported to have been no bronzing of skin, differ altogether in character from the eighteen cases just discussed; and the explanation, as regards them, of the absence of the usual discoloration, is at first sight less obvious.¹

In none of these ten cases was there any other disease of the least importance co-existing with the disease in the supra-renal capsules. In no less than eight of them, all other organs are reported to have been perfectly healthy, with the exception in some instances of small inactive tubercular deposits in the apices of the lungs; and, in the remaining two cases, there was only a little more active tubercular disease in the same seats. We may, therefore, fairly presume that, in all these cases, the disease in the supra-renal capsules was the efficient cause of death, more especially as the

¹ See Appendix B, Group vi. Cases 221-230.

constitutional symptoms were, in every case, characteristic of Addison's disease, and in several of them as typical as in any cases on record.

In nearly all of these cases, however, the illness was of comparatively short duration, only one of the ten cases having exceeded a course of eight months; and, in several of them, there appears to have been, notwithstanding the absence of any developed bronzing, some peculiarity in the colour of the skin, sufficient to attract attention. In a case reported by Sir W. Gull, the face is said to have been of a sallow or yellowish cast;¹ in two cases, which were respectively under the care of Dr. Bristowe² and Dr. Owen Rees,³ the complexion was noticed to be brownish after death; in one recorded by Dr. Tuckwell, there was a sallow hue, as of slight jaundice, with the conjunctivæ pearly;⁴ and, in a case reported by Professor Heschl, it is noted that the skin was yellowish, with a grey tinge.⁵ On the other hand, in one case, very fully reported by Hertz in Virchow's 'Archiv' for 1870, there was no trace of discoloration of skin, even at death;⁶ but the illness would seem to have been of very short duration, for, although the patient reported himself to have been failing in health since an attack of cold and quartan fever a few months previously, he only presented himself at the hospital six days before death. At that time, moreover, he had still some appetite, and the description of his condition is not that of an advanced stage of the disease, but he sank suddenly under the unusual severity of the nervous symptoms. In another case, under the care of Dr. Owen Rees, which was most characteristic as regards the constitutional symptoms, and in which the patient was failing in health for a year, and ill for nine weeks, there was no

¹ Case 224. ² Case 221. ³ Case 229. See also Appendix A, p. 157, Case xx.

⁴ Case 230.

⁵ Case 225.

⁶ Case 226. See also Appendix A, p. 177, Case xxviii.

discoloration whatever.¹ The same may be said with respect to two other cases recorded by Dr. Murchison and Mr. Crossman, of six and eight months duration respectively.² This last case is the longest on record in which death has taken place with all the characteristic constitutional symptoms of Addison's disease, but without any sign of change of colour in the skin. There is, nevertheless, one case included in the ten, in which the illness is stated by Mr. Bruce, who reported the case for Dr. Russell Reynolds, to have lasted sixteen months.³ But, as the patient had been always delicate and a hard drinker, and as the only symptoms observed were sickness, loss of flesh, and sense of emptiness at the epigastrium, it may have been difficult to fix the commencement of the symptoms due to the disease in the supra-renal capsules. It is certain that this latter was not in an advanced stage at the time of the patient's sudden death, for a little of the proper tissue of the organs was still found remaining.

The simple and satisfactory explanation of these ten cases lies, I believe, in the variable comparative date of development of the constitutional symptoms and bronzing of skin in different cases, to which I drew attention in my first lecture, as one of the peculiar features in the course of this remarkable disease. It was at first thought that the absence of bronzing of skin, in otherwise obviously characteristic cases of Addison's disease, might be accounted for on the supposition, that a course of several months at least was requisite for the development of the bronzing. More extended clinical observation has now established the fact, of which I gave several examples in my first lecture, that, in some cases, the bronzing of skin is more or less fully developed for considerable periods of time before the patient feels any symptoms of illness; whilst, on the other hand, in

¹ Case 228.

² Cases 227, 223.

³ Case 222.

a considerable number of cases, the constitutional symptoms have shown themselves for longer or shorter periods before the appearance of any discoloration of skin.

It will be easily understood that cases belonging to the former of these classes are much less liable to give rise to misunderstanding than cases of the latter class; for, whilst those patients who are affected first by the discoloration of skin will live on as usual till the constitutional symptoms make their appearance, those patients in whom the constitutional symptoms are first developed may very possibly die, especially if exposed to the effects of any external depressing influence, before the appearance of the discoloration of skin. This is, in fact, precisely what I believe to have occurred in all the ten cases which I am now discussing. I believe them all to have been typical cases of Addison's disease, whose course was cut short by individual feebleness, or by unfavourable circumstances, before the development of the bronzing of skin; which would have presently taken place, as in the similar cases quoted in my first lecture, if their course had been sufficiently prolonged.

Looking to all the difficulties which have stood in the way of our obtaining full and accurate reports of even the recognised cases of this rare and obscure disease, and to the certainty that many of the cases have remained unrecognised till after death, when it was too late to fill up deficiencies in the clinical records, I cannot but regard these statistics as furnishing conclusive evidence of the real and constant relation of a certain train of constitutional symptoms and a peculiar change of colour in the skin, to one particular diseased condition of the supra-renal capsules.

Such a weight of concurrent testimony to the truth of Addison's discovery could scarcely, indeed, have remained so long unrecognised, had it not been for the extensive prevalence of those misconceptions to which I have alluded, as

obscuring the true aspect of the question from the moment it was first submitted to the profession.

These misconceptions had reference chiefly to the characters of the discoloration of skin, and of the lesion in the supra-renal capsules, which were really indicative of Addison's disease; and they originated, as we have seen, in a great degree, in Addison's own mistakes. He subjoined to his own true cases of the disease several spurious cases, presenting discoloration of skin and disease in the supra-renal capsules of quite different characters from those he had described, and unassociated with any of the apparently causeless constitutional symptoms which had existed in his own cases. He also gave to the disease the name of 'melasma supra renale,' for which was afterwards substituted that of 'bronzed skin disease;' thus identifying the disease itself with its most conspicuous, but least important, feature. In consequence of these mistakes, the asthenia and other peculiar constitutional symptoms, which had first revealed to Addison the existence of the disease, were by degrees in a great measure overlooked, both in reports of cases and in discussions based upon them. Numerous cases were brought forward, on the one hand, only to show that discoloration of skin not unfrequently occurred without any disease whatsoever being found in the supra-renal capsules; and, on the other hand, merely to prove that discoloration of skin did not always result from disease in the supra-renal capsules, even when sufficiently extensive to cause the entire destruction of those organs. In both these classes of cases the facts were undeniable, and the inferences drawn from them have been alleged, from that day to this, as the principal arguments against the truth of Addison's discovery—namely, that :

Discoloration of skin not unfrequently exists without any disease of the supra-renal capsules; and that :

Disease of the supra-renal capsules not unfrequently exists without producing any discoloration of skin.

Both these allegations are undoubtedly true ; but, as I shall proceed to explain, they neither of them contravene, in the slightest degree, the reality of the relation subsisting between the peculiar change of colour in the skin and the particular lesion of the supra-renal capsules which are found to co-exist in Addison's disease.

First, then, discoloration of skin does frequently exist without any disease of the supra-renal capsules ; but, it is discoloration which either presents altogether different characters from that associated with supra-renal disease, or which, if more or less resembling it, is easily referable to some other obvious pathological cause, or to some known physiological condition. Neither Dr. Addison himself, nor anyone who upheld his views, has ever professed that disease of the supra-renal capsules was to be regarded as the only cause of discoloration of skin. This would have been as absurd as it would have been for Dr. Bright to have asserted that disease of the kidneys was the only cause of dropsy. In both cases, the truth discovered was the relation between a hitherto undiagnosed local lesion and one particular form of an obvious affection.

There are various conditions, both physiological and pathological, which are accompanied by general or partial darkening of skin ; but, as the former are universally known and attributed to their true physiological causes, I need not dwell upon them ; and I, therefore, pass on to the various discolorations of skin produced by pathological causes, which have been more or less frequently confounded with the peculiar discoloration of Addison's disease. Among these there is, perhaps, none more striking than the cutaneous discoloration often seen in elderly persons of very indigent circumstances and uncleanly habits, especially when infested

by vermin. I have records of several such cases, which have been under my care in the Middlesex Hospital, either for obvious disease, or simply for the debility and sinking consequent upon long-continued hardships and exposure. In the year 1864 I exhibited one of these cases at the Pathological Society as a case of bronzed skin, simulating the discoloration of Addison's disease.¹ Such cases, however, though undoubtedly presenting some of the appearances of Addison's disease, may yet be easily distinguished from it. In my patient, a woman aged sixty-five, the skin was extensively bronzed, especially over the abdomen, chest, and back; but the discoloration, when carefully examined, was totally different from the bronzing in Addison's disease. It was seated in the superficial, instead of in the deeper, layers of the epidermis; it was paler, instead of deeper, on the face, hands, and other parts, which are naturally the seats of most pigment; and the small, isolated dark spots were all upon the pale, instead of on the discoloured, portions of the surface. The darkened cuticle, also, was not soft and smooth, but in many parts raised and rough. Lastly, such constitutional symptoms as were present—debility, languor, and a sense of sinking at the epigastrium—were obviously referable to apparent causes, and were soon removed by tonic treatment and an ample supply of food. I should add that, under the use of alkaline warm baths and soap, the discoloration greatly diminished, though the skin did not entirely regain its normal hue.

Again, it is well known that pityriasis versicolor is attended by more or less extensive and permanent discolorations of skin; and cases of this kind have, more than once, been adduced in supposed disproof of the connection between bronzing of skin and disease of the supra-renal capsules. The seat and distribution of these discolorations,

¹ *Trans. Path. Soc. of Lond.* Vol. xv. P. 226.

however, as well as their modes of development and disappearance, are widely different from the characters of the peculiar change of colour in Addison's disease. The dark patches are usually rather upon the trunk and limbs than on the face; they have abrupt margins and convex borders, and are interspersed with spaces of normal coloured skin; they appear and disappear rapidly; and, above all, no asthenia nor other constitutional symptoms are associated with them.

Syphilitic eruptions are also notoriously the cause of more or less permanent stains on the skin; but, although their coppery hue and patchy character distinguish them clearly from the bronzed skin of Addison's disease, they must be not unfrequently confounded with it, for it has happened to myself to have two such cases sent to me, in private practice, on the supposition that the discoloration indicated the existence of Addison's disease.

There are, however, various kinds of discoloration of skin which bear a somewhat more real resemblance to the bronzing of Addison's disease than those to which I have referred; in so far that the skin remains soft and smooth, and the pigment is deposited in the same layers of the epidermis, though not in the same quantity, nor usually to the same extent, nor in the same characteristic seats. Such discolorations are well known to be produced occasionally by diseases peculiar to women, by tropical and malarious fevers, by long-continued hepatic disease, and by very chronic phthisis.

Of this last class of cases I have seen several remarkable examples since my attention has been directed to the subject. A woman, aged twenty-six, who died under my care in the Middlesex Hospital of chronic phthisis in 1871, presented, when I first saw her, precisely the appearance of Addison's disease in an early stage, her face having the same peculiar

duskiness, and her forehead, except where covered by the hair, being of a distinct brown colour, though the skin remained perfectly soft and smooth. Another phthical patient, a man aged fifty, was sent to me, in 1872, by my colleague Mr. Num, with an abnormal pigmentation of the tongue, almost exactly resembling that frequently seen in Addison's disease, and with patches of brown discoloration on the mucous membrane lining the inside of the lips and cheeks.¹ My colleague, Dr. Thompson, also invited me to examine, some time ago, a man aged fifty-five, suffering from bronchitis and emphysema, with, it was suspected, old-standing phthisis behind the more acute ailments. He exhibited several brown patches, corresponding with the extent of superficial injuries received in a fall about a year before; and, on the lower part of the sternum, there was a transverse irregular white cicatrix, about an inch-and-a-half long by a quarter-of-an-inch wide, which was encircled by a dark-brown ring, of nearly half-an-inch in width, fading off into the normal hue of the surrounding parts; the skin of the groins was also slightly dusky. In all these cases the partial discolorations strikingly resembled those found in corresponding situations in Addison's disease; but, they neither deepened nor spread over the general surface during the subsequent illness of the patients, nor did these latter suffer from any constitutional symptoms beyond those which were due to their pulmonary complaints. I need therefore scarcely say that, in all three cases, the supra-renal capsules proved, on post-mortem examination, to be perfectly healthy.

The observation of these and other similar cases has convinced me that no partial discolorations of skin are to be relied on, as diagnostic of Addison's disease, unless when found in conjunction with the characteristic constitutional symptoms.

¹ See Report of case, *Trans. Path. Soc. of Lond.* Vol. xxiv. P. 94.

It will be remembered that, when dealing with the total number of cases collected as bearing upon the subject of Addison's disease, I set aside in the first instance, for subsequent discussion, all those cases in which the supra-renal capsules were not shown to have undergone the one particular change characteristic of Addison's disease. These cases fell into three classes, and the first class included all those cases which I had found reported as bronzing or discoloration of skin without any disease of the supra-renal capsules. These cases are 21 in number, and a brief analysis will show that, in almost all of them, the abnormal pigmentation was due to one or other of the pathological conditions I have mentioned.¹

Two of the twenty-one cases, published by Averbeck and Vernois, very closely resemble the case, already referred to, of the woman exhibited by me to the Pathological Society;² the ages, circumstances, uncleanly habits, and states of health, as well as the characters of the discoloration, having been very similar in all three patients.³ The patients in these two

¹ See Appendix B, Group VII. Cases 231-251.

² Cases 231, 242.

³ Since the delivery of these lectures, Dr. Moore, of Dublin, has courteously forwarded to me a copy of a case I had overlooked, which was published by him in 1871 in the *Dublin Quarterly Journal of Medical Science*, and which appears to me to have had very considerable analogies with these cases.

The patient, a delicate woman aged sixty-two, had fallen into poverty after her husband's death, and for seven or eight years her body had gradually been getting discoloured, whilst for two years she had also been emaciating and her mind had been giving way. When she came under Dr. Moore's care she was quite demented, her body was reduced to a skeleton, and her skin was universally and deeply discoloured. The face and extremities, however, had been the last to take on the discoloration, and were still the lightest parts. The skin had a soft greasy feel, and gave off a disgusting odour, and the cuticle was peeling off the body and arms. She could take no solid food, and vomited liquids, was always in a drowsy state, and finally slept away to death, having made no complaint from first to last. On post-mortem examination no disease was found in the supra-renal capsules, nor in any other organs, except in the mesenteric and lumbar glands, which were complete masses of tubercle, and in the lungs, in which there was also some tubercle.

cases, however, died, when the capsules were found to be perfectly normal ; and it is significant of the confusion which prevails on the subject, that Dr. Averbeck, who did not consider his own case as a true example of Addison's disease, nevertheless tabulated the parallel case of my patient, who recovered, among the so-called 'cured cases' of that disease, which, as he justly observes, 'must be received with suspicion.'

In three cases published by Puech and Gordon, there had been constitutional syphilis.¹ In one of Puech's cases, which was complicated with phthisis, there was 'an earthy colour of face, with large brown patches nearly covering breast and abdomen ;' in the other the crusts of ecthyma on the chest showed, on removal, normal-coloured skin beneath, proving the discoloration to be merely superficial, and the face was of a much lighter hue than the body ; whilst, in Dr. Gordon's case, the skin is only said to have been first of a dirty yellow, and then of an olive hue, with chesnut-coloured specks on the scrotum ; and Dr. Aitken, of Netley, to whom the healthy capsules were submitted for examination, attributed all the symptoms to syphilis.

In two cases, recorded by Sloane and Luton, the darkening of the skin was associated with phthisis.² In the first, the patient had also suffered from liver complaint, with permanent discoloration of skin ; and, although the whole surface was bronzed, the mammæ around the nipples were much paler than the surrounding parts, and there were many white spots on the breast and back. In the second case, the whole surface is said to have had the earthy hue seen in the last stage of phthisis, with bistre patches on the forehead and cheeks, and dirty-brown wrists and backs of hands.

In two cases, related by Gibb and May, there was disease of both the lungs and heart.³ Dr. Gibb's patient had disease

¹ Cases 246, 247, 235.

² Cases 241, 251.

³ Cases 234, 243.

of the aortic valves, which sufficiently accounted for the 'pale-greenish bronze hue of the face and neck.' In Mr. May's case the patient had also suffered from gout, and although the discoloration is said to have been most marked on the face, neck, axillæ, arms, and legs, the small brown spots scattered over the normal-coloured skin were quite uncharacteristic of Addison's disease, and point rather to the remains of some gouty eruption.

In four cases, published by Hutchinson, Harley, and Fricke, the discoloration dated from attacks of yellow fever, jaundice, and hepatic derangement.¹ Mr. Hutchinson's patient died of pneumonia after an illness of fourteen days. His skin had darkened from the time he had had yellow fever in the Crimea; the entire surface was more or less bronzed, and the pigment was chiefly in the rete mucosum, but the face and hands were the lightest parts. In one of Dr. George Harley's cases the darkening of skin followed an attack of jaundice, and remained during five years of good health; the face, neck, and arms were dark, but the discoloration on the body was diversified with irregular white patches; the patient died of diseased liver and ascites. In Dr. Harley's other case, the patient had suffered, during four years, from occasional hepatic symptoms and gastric disorder. The face, arms, and trunk were all of a dark bronze colour, except the scar of a burn on the breast; but apparently the discoloration was quite uniform, and, unfortunately, the condition of the liver was not noted. In Dr. Fricke's case the bronzing was limited to the forehead, face, and neck, and merged into jaundiced skin; the patient had suffered from ague, and died of cirrhosis of the liver.

A case seemingly allied to these, but far more complicated, is reported by Dr. Merkel.² The man's skin had always

¹ Cases 240, 237, 236, 233.

² Case 244.

been dark, and he had suffered from ague. He died of bronchitis and pleurisy, but he was found to have a large liver and spleen, with fatty degeneration of heart, liver, and kidneys. The whole surface was bronzed, equally on covered and uncovered parts, and there were grey-black patches on the buccal mucous membrane.

Two cases of discoloured skin, without disease of the supra-renal capsules, recorded by Dr. Bucknill and M. Regnard, occurred in women who were maniacal at the climacteric period of life—circumstances in which extreme duskiness of skin is by no means rare.¹ Two cases of internal cancer, not involving the supra-renal capsules, are reported by Mitchell and Frémy as presenting a certain degree of discoloration of skin;² but of the first it is only said that the sallow skin became of a leathern hue, much darker in eczematous scars and in the site of a blister than on other parts; and of the second, that some days before death the skin assumed, in places, a very evident bronze hue. Dr. Hodges found on the bodies of two old men, one of whom died insane and the other of old age and debility, darkening of skin, with a deeply bronzed hue of the genital organs, but the face and other parts of the surface were but little discoloured.³

There still remains, however, a case of bronzed skin without disease of the supra-renal capsules, published by Rossbach in Virchow's 'Archiv' for 1870, which requires more special notice.⁴ The case is most fully and accurately recorded, and, on the supposition that it is a true case of Addison's disease, is made the basis of a new theory on the pathology of that disease, to which I must hereafter revert. The patient, a lady aged sixty-two, had always been prone to excitement and sleeplessness, and these natural tendencies had been aggravated by long-continued distress of mind. She suffered

¹ Cases 248, 249.

³ Cases 238, 239.

² Cases 245, 232.

⁴ Case 250.

from anæmia, debility, loss of appetite, occasional vomiting, and violent pains in the epigastrium, and also in the right scapula, which she had hurt by a fall. These pains gradually extended round her body with the intensity of the neuralgia of shingles, and were always worst at night. Scleroderma began to develop on her right hand and fore-arm, and spread more or less to other parts of her body. The skin and subcutaneous tissue became as hard as stone, split, and formed fissures; and, together with this very rare cutaneous affection appeared dark and extensive pigmentation of skin, of which large patches were sometimes developed in a single night. Meantime the patient's restlessness and misery of mind and body increased; she could bear no position in or out of bed for fifteen minutes together, and at length she became totally sleepless and actually deranged at night. Towards the close of life her pulse was quick, hard, and occasionally intermitting; she had albuminuria and anasarca; and sank under a slight attack of pneumonia, after nine months' illness. The cerebellum was found to be very soft, the brain and lungs œdematous, and there was some fatty degeneration of the heart, liver, and kidneys; but the supra-renal capsules and neighbouring nerves were perfectly normal. The pigmentation of skin was co-extensive with the scleroderma. Where palest it was produced by innumerable small dark points, and on the darkest parts there were dendritic patches of colourless skin. Under the microscope, the pigment was seen to be deposited chiefly in the papillæ and upper layers of the cutis. I need not pause to point out, in detail, the totally opposite characters of this discoloration of skin from those of the discoloration in Addison's disease. The morbid excitement and restlessness of mind and body, which were the chief constitutional symptoms throughout the case, were also conditions totally uncharacteristic of Addison's disease; and the anæmia and

other symptoms, which did resemble some of the characteristic constitutional symptoms of that disease, were all fully accounted for by the obvious ailments, mental and physical, of the patient.

From this analysis of the twenty-one cases, published as cases of bronzing of skin without disease of the supra-renal capsules, I think it is evident that, in all of them, the discoloration of skin was due to other existing pathological causes, and that it presented in none of them the really characteristic features of the bronzed skin of Addison's disease. I should add, what in my view is even more important, that in none of these cases are any constitutional symptoms recorded but such as are easily referable to the morbid conditions which I have mentioned as present in each. They are of course only representative cases, as others of similar characters are continually occurring, though they have not been brought forward as bearing upon the subject of supra-renal disease.

The second allegation against the truth of Addison's discovery—namely, that 'disease of the supra-renal capsules not unfrequently exists without producing any discoloration of skin'—is also, as I have said, perfectly true. Apart, however, from the small number of cases already discussed, which have terminated before the development of the bronzing of skin, it may be positively enunciated that disease of the supra-renal capsules, which is not attended by discoloration of skin, presents totally different characters from the particular lesion of those organs existing in Addison's disease.

The second of the three classes of cases, set aside at the beginning of this lecture, comprised all those cases in which the disease found in the supra-renal capsules was of an altogether different nature from the particular lesion characteristic of Addison's disease. This class includes thirty-six cases, which I have found published as examples of disease of

the supra-renal capsules without bronzing of skin, as well as fourteen other cases, with which I shall presently deal.

Of the thirty-six cases of supra-renal disease without bronzing of skin, 24 are cases of cancer of one or both capsules, invariably secondary to cancer of other neighbouring organs;¹ and 12 are cases of miscellaneous affections of the supra-renal capsules.² In three of these twelve cases the capsules had undergone fatty or amyloid degeneration;³ in two cases there were cysts,⁴ in four apoplexy,⁵ and in three sarcomatous, fatty, and hyperplastic tumours respectively;⁶ affecting, in seven cases out of the twelve, only one of the two capsules.

It is obvious that none of these lesions bear any resemblance to the one particular lesion of the supra-renal capsules which is attended by discoloration of skin, nor were any constitutional symptoms present in any of these cases except such as were due to disease existing in other organs. I should add, that I have myself had the opportunity of observing, in the Middlesex Hospital, several unpublished cases of abdominal cancer, in which the supra-renal capsules were found to be involved. The structure of the capsules was destroyed in all these cases, but in none of them were there any constitutional symptoms, or bronzing of skin, resembling those of Addison's disease.

Hence, therefore, although it is quite certain that bronzing of skin may occur without the existence of any disease in the supra-renal capsules; and, again, that disease of the supra-renal capsules may exist, to the extent of entirely destroying their structure, without producing any bronzing of skin; it is also, on the other hand, equally clear, that in

¹ See Appendix B, Group VIII. Cases 252-275.

² See Appendix B, Group IX. Cases 276-287.

³ Cases 277, 281, 287.

⁴ Cases 276, 285.

⁵ Cases 279, 280, 283, 284.

⁶ Cases 282, 278, 286.

the one case, the bronzing of skin is not the peculiar discoloration indicative of the existence of Addison's disease, and that, in the other case (with the few exceptions already explained), the lesion in the supra-renal capsules is not the particular lesion of those organs which constitutes Addison's disease.

Were these the only misconceptions with respect to the relation between supra-renal disease and discoloration of skin, I might here close my review of this part of the subject; but, unfortunately, a small number of misunderstood cases have given a certain degree of prevalence to another quite opposite misconception: namely, that any disease of the supra-renal capsules, involving destruction of their tissues, will produce the same effects as the particular lesion characteristic of Addison's disease.

Had not attention been too entirely directed to the bronzing of skin, to the neglect both of the constitutional symptoms and of Addison's original reservation that other pathological causes must first be excluded, such a misconception could never have arisen. It began, however, with Addison himself, who published in his monograph four cases of cancer of the supra-renal capsules, as having been attended by some degree of discoloration of skin. I have found published, since Addison's time, five other cases of cancer, or so-called cancer, of the capsules with discoloration of skin, making 9 cases nominally belonging to this class:¹ and, also, 5 cases of miscellaneous affections of the supra-renal capsules attended by various kinds of discoloration.²

A glance at these fourteen cases, however, will show that they afford no true basis for this misconception. In the first of Addison's four cases the patient was a woman aged sixty—a time of life when the skin, even in healthy subjects, is apt

¹ See Appendix B, Group x. Cases 288–296.

² See Appendix B, Group xi. Cases 297–301.

to assume a dry brownish appearance—and she was suffering from extensive cancer of the left breast, lung, and surface of the liver. The only discoloration noted was a light-brown swarthy hue of the face, arms, and chest. The second case was that of a woman aged fifty-three, who died of cancer of the stomach. She had previously had an eruption on her body, and her skin is described as harsh, dry, and of a darkish hue. The folds of the axillæ were remarkably dark, and coloured patches, the size of the palm of the hand, were observed raised in wrinkles, and resembling slight ichthyosis. In the third case, which was that of a woman aged twenty-eight, who had died of cancer of the uterus, the only discoloration noticed was a peculiar dingy appearance of the skin, not very strongly marked. The fourth case was that of a man who had died of cancer of the thorax and lungs, and when cancer was unexpectedly found in one of the supra-renal capsules, it was ascertained from the clinical notes that the patient's face had presented a dingy hue.¹ Two more recent cases of cancer of the capsules with discoloration of skin have been recorded by Drs. Gibb and Cayley.² In Dr. Gibb's patient, cancer of the liver and right capsule were associated with a proliferous ovarian cyst, and it is only stated that there was distinct brownish discoloration of the abdomen, especially below the navel, and of the chest, especially over the sternum. Dr. Cayley's case was that of a woman aged forty-five, who died of cancer of the uterus, with secondary deposits in most of the abdominal organs. There was only a nodule of cancer, the size of a pea, which projected from the surface of the supra-renal capsule, but during the last month of life the surface was remarkably dusky and sallow, especially on the face and neck. I need scarcely point out that in none of these six cases was the discoloration of skin in any degree character-

¹ Cases 288–291.

² Cases 292, 296.

istic of Addison's disease, and in none of them were any constitutional symptoms present, but such as were due to the disease existing in other organs.

It will be observed, moreover, that in all these six cases, as in every one of the twenty-four cases of cancer previously referred to, the cancerous disease in the capsules was secondary to cancer of other important organs.

The three remaining cases of so-called cancer of the supra-renal capsules, attended by discoloration of skin, are of a very different character; having all presented, in a typical form, the constitutional symptoms and bronzing of skin described in my first lecture, and having been in fact, as I believe, typical cases of Addison's disease. In the first of these cases, Dr. Mettenheimer says that the capsules were replaced by cancerous deposits;¹ but he gives no description of them, and he was so little clear as to the nature of such deposits that he further reports the presence of some tuberculous or cancerous indurations in the left lung; and, as no cancerous disease was found in any other organs, I think there can be no doubt that the deposits both in the lungs and in the capsules were of the so-called tuberculous character. Dr. Duclos, in the second case, pronounces the disease in the capsules to have been 'perfect scirrhus;' but his report of the condition of the organs, including that of the microscopical appearances, is, on the contrary, a perfect description of the lesion peculiar to Addison's disease.² The capsules, he says, 'formed tumours of the size and shape of eggs, very hard and much nodulated, and on section they grated against the scalpel, and presented precisely the appearance of lardaceous tissue.' Both these cases, I should add, although denominated by their authors cancer of the supra-renal capsules, were at the same time regarded by them as true examples of

¹ Case 295. See also Appendix A, p. 190, Case xxxvi.

² Case 293. See also Appendix A, p. 189, Case xxxv.

Addison's disease. The third case is published by Dr. Gage, of Worcester, U.S., and had a history from which the existence of cancer in the supra-renal capsules was apparently inferred, though it is not expressly asserted.¹ The patient, a lady aged fifty-one, was said to have had scirrhus of the right breast, which, though of several years' growth, had not involved any of the neighbouring lymphatic glands, and had been removed two years before her death without recurrence. Her last illness was of six months' duration, and both the constitutional symptoms and bronzing of skin were characteristic of Addison's disease. Both capsules were found to be much enlarged, and they were joined together by a thickened mass of enlarged and diseased lymphatic glands. The right capsule was adherent to the under-surface of the liver, and it is stated that from the point of attachment 'several broad lines of reddish-white deposit, resembling soft cancer, radiated into the substance of the liver for one-and-a-half inches.' In this case there appears to have been no microscopical examination of the diseased organs, and although the description is less clear than in the two previous cases, it presents on the whole a greater resemblance to the lesion in Addison's disease than to cancer. Besides, it must be borne in mind, that, if these three cases were in truth cases of cancer of the supra-renal capsules, they are the only cases on record in which cancerous disease of those organs has ever given rise to the constitutional symptoms and bronzing of skin characteristic of Addison's disease, or has ever been attended by fatal results without the implication of other important organs—circumstances so incredible, that they seem to justify the opinion I have ventured to express with regard to their real character.

Of the five cases of miscellaneous affections of the supra-renal capsules accompanied by discoloration of skin, two are

¹ Case 294. See also Appendix A, p. 190, Case xxxvii.

cases of amyloid disease.¹ In one of these, published by Averbek, the patient, a man aged fifty-three, presented a dirty grey-brown colour of skin, deepest on the shoulders and back, whilst the face was of a lighter hue. I need scarcely observe that discoloration of skin, such as is described in this case, is very commonly seen in cases of amyloid disease. In the other case, recorded by Wolff, the patient had suffered for years from profuse suppuration in a large hydatid cyst of the left kidney. A year before death his face and forehead acquired a dark-yellow, sunburnt hue, but the mucous membranes remained anæmic, and the only signs of discoloration on the body were a few lentil-sized black spots on the neck, abdomen, and extremities. The debility, loss of appetite, vomiting, and epigastric pains, which were present in this case, were all, as well as the emaciation, obvious results of the general abdominal disease and of the increasing discharge of fetid pus. In the remaining three cases there was fatty degeneration of the capsules.² One, related by Sir Henry Thompson, is the case of an old woman, aged eighty-one, who died of bronchitis. Her skin was bronzed except on the face and hands, and the whole skin was permeated by colouring matter. In another of these cases, recorded by Charcot, the patient, a man aged fifty-seven, presented large brown patches on most parts of the body, with a slight but almost general lichenoid condition of skin; but the face, hands, and feet remained of normal hue. The third case, published by Schet, is worthy of fuller notice, because the discoloration of skin appears, from the description, to have been identical with that seen in Addison's disease. It dated, however, from nine years' work in the glowing sun of a tropical climate, where the man had suffered from repeated attacks of intermittent fever, which continued to recur at intervals during the four years he sur-

¹ Cases 297, 301.

² Cases 300, 298, 299.

vived his return to Europe. When he died, of epileptiform attacks following copious spirit-drinking, the spleen was found to be much enlarged, and the blood contained pigment-granules and an excess of white blood-corpuscles. The discoloration in this case was therefore doubtless due, in part, to the effects of climate, but mainly to melanæmia, arising from malarious poisoning and enlarged spleen.

It seems, on the whole, quite clear that these fourteen cases afford no real grounds for the misconception that any other disease of the supra-renal capsules, involving destruction of their tissues, will produce the same effects as Addison's disease of those organs.

I have now reached the last of the three classes of cases, set aside at the beginning of this lecture; comprising all those cases in which the imperfect description of the condition of the supra-renal capsules leaves doubtful the nature of the lesion, and even; in some cases, the existence of any lesion at all.

These cases are 32 in number, and they belong in reality, so far as I can judge, to several different classes;¹ the only feature they have in common being the vagueness of description, which has compelled me to throw them all into the same class.

In eight of these cases, the reports of the constitutional symptoms and discoloration of skin incline me to the belief that they were true cases of Addison's disease; but the descriptions of the lesion in the supra-renal capsules are quite insufficient to entitle me to class them as such. Thus, in one of the two cases reported by Mr. Harrinson, the supra-renal capsules are merely said to have been in an advanced stage of disease; and in the other, it is only stated that the interior of the left capsule was softened and broken up, and that the right capsule was in a similar, but less advanced, condition.²

¹ See Appendix B, Group XII. Cases 302-333.

² Cases 316, 317.

In a case reported by Surgeon-Major Wyatt, the supra-renal capsules are only described as being very dark, irregular in form, and hard on section;¹ and, in one published by Dr. Martin, the right capsule is merely said to have been converted into a cyst filled with sero-purulent fluid.² The descriptions in the other four cases are equally vague;³ and, in none of the eight, is there any report of the microscopical appearances.

In four cases, reported by Drs. Hayden, Collins, Second Féréol, and Löwe, the disease in the capsules was probably fatty change;⁴ and in one, reported by Mr. Barton, it was probably cancer, secondary to cancer of the liver.⁵ In twelve of the thirty-two cases the nature of the lesion in the capsules is altogether uncertain; indeed, two of these cases were published, by Drs. Moxon and Tuckwell, as examples of doubtful or anomalous affections of the supra-renal organs.⁶ In four cases, published by Drs. Murney, Isaac Taylor, Bühl, and Brehme, the change in the capsules appears to have been merely a post-mortem change;⁷ and, in some of the other cases in this class, I am disposed to attribute the dark-red or brownish colour of the capsules to the same cause. Lastly, in three cases, the supra-renal capsules are reported to have been absent or entirely atrophied.⁸

It is certain that the characteristic features of the supra-renal lesion, in Addison's disease, are not described in any of these thirty-two cases. A considerable number of them would appear to have been published under a misconception, which undoubtedly exists in some quarters, to the effect that any abnormal condition of the supra-renal capsules is sufficient to justify the assumption of the existence of Addison's disease.

¹ Case 333.

² Case 325.

³ Cases 310, 314, 319, 321.

⁴ Cases 318, 309, 312, 323.

⁵ Case 304.

⁶ Cases 326, 332.

⁷ Cases 327, 331, 306, 305.

⁸ Cases 330, 322, 324.

I must advert for a moment to the most recent of these cases, reported by Dr. Wickham Legg in the tenth volume of *St. Bartholomew's Hospital Reports*;¹ because its author is of opinion that its facts have sufficient weight to require the modification, if not the abandonment, of the prevailing theories with respect to Addison's disease. The patient, a woman aged thirty-seven, unquestionably exhibited certain symptoms resembling some of the constitutional symptoms of Addison's disease; for she suffered during eighteen months from debility, shortness of breath, occasional vomiting of food, and constipation; and she died, after five weeks' residence in the hospital, of vomiting and exhaustion. But, on the other hand, there was a distinct bilious tendency to explain the vomiting, the appetite was fair, and there was great thirst, with a red fissured tongue and swollen spongy gums, and a temperature above the normal. Moreover, the patient had lost four stone in weight during her illness—an absolutely unprecedented occurrence in Addison's disease, unless when resulting from some serious co-existent wasting disease. The discoloured skin, also, was harsh, dry, and warm, instead of being soft and cool, and was not more deeply pigmented in the axillæ or mammary areolæ than at other parts. At the post-mortem examination the right supra-renal capsule could not be found, its place being occupied by a mass of yellow fat, and the left capsule was only represented by a small black body as thin as paper. This was a most peculiar and interesting condition of the supra-renal capsules, but it obviously bore no relation whatever to Addison's disease of those organs, nor were the constitutional symptoms and discoloration of skin, taken as a whole, characteristic of that disease. The most difficult point in the case is the absence of any apparent cause of illness and death; for, that an abnormal condition of the nature described could

¹ Case 322.

produce active symptoms and fatal consequences, without the implication of any other organs, seems, to say the least of it, highly improbable.

One case remains, of the whole number collected, which represents another misconception so remarkable that it cannot be entirely passed over; although, from the absence both of supra-renal disease and of discoloration of skin, it could not be classed with any of the other cases. The case is related by Dr. Gilliam, of the United States, and is that of a man aged forty-five, who suffered from symptoms resembling several of the characteristic constitutional symptoms of Addison's disease.¹ Gradually increasing debility, dyspnoea and palpitation on exertion, loss of appetite and obstinate tendency to vomiting, were symptoms which, in the absence of any other discoverable cause, might fairly lead to the diagnosis of Addison's disease, although no discoloration of skin had appeared. But when, after death, not only the supra-renal capsules were found to be healthy, but advanced degeneration and atrophy of the gastric tubules was discovered, which, as the author himself remarks, fully accounted for all the symptoms, the diagnosis had clearly been a mistake. From this case, however, Dr. Gilliam concludes: first, that bronzing of skin is a quite unimportant feature of Addison's disease; and, secondly, that Addison's disease itself consists not in a lesion of the supra-renal capsules, but in disease of the gastric tubules. The misconception lying at the root of this singular theory appears to have been, that the presence of symptoms resembling some of the constitutional symptoms of Addison's disease was, in itself, sufficient evidence of the existence of that disease; and that, consequently, the lesion which had produced them might be safely pronounced to be the essential lesion of Addison's disease. That the lesion in

¹ *Schmidt's Jahrbuch*, vol. cliii. p. 31, quoted from *Philadelphia Med. and Surg. Reporter*.

the stomach was the cause of the gastric and other symptoms, in the case referred to, is obvious enough; but I trust I have made it equally clear, that no symptoms, obviously referable to other morbid conditions, can possibly justify any assumptions as to the existence of Addison's disease.

The question naturally arises, how misconceptions, so baseless in fact and disproved by such conclusive evidence, can have been so widely propagated and have survived so long? I believe that this has been mainly due to the great rarity of the disease, which has prevented all but a small minority of medical men from acquiring even the scanty degree of practical acquaintance with its true characters, which the observation of a single typical case would afford.

If, however, the relation between the clinical phenomena and the supra-renal lesion which are found co-existing in Addison's disease, may be considered as proved, the obscure pathological processes involved in that relation, and the equally obscure causes of the supra-renal lesion itself, will still afford ample field for investigation. To these parts of the subject I must endeavour to address myself in my next lecture, although perfectly conscious of the insurmountable difficulties they present, in the present vague and imperfect state of our knowledge with respect to many essential facts.

LECTURE III.

SYMPTOMS OF ADDISON'S DISEASE NOT DUE TO DESTRUCTION OF TISSUE OF SUPRA-RENAL CAPSULES—INTIMATE RELATIONS OF SUPRA-RENAL CAPSULES WITH NERVOUS SYSTEM—SYMPTOMS DUE TO PROLIFERATION OF CONNECTIVE TISSUE WITHIN AND AROUND CAPSULES, COMPRESSING NERVE-GANGLIA AND PLEXUSES—CHANGES PRODUCED IN NERVES BY PRESSURE OF INFLAMMATORY TISSUE; IRRITATION; ATROPHY AND FATTY DEGENERATION; IMPAIRMENT OF NERVE-FUNCTIONS—CLINICAL GROUNDS FOR REFERRING SYMPTOMS OF ADDISON'S DISEASE TO NERVE-LESIONS—PHYSIOLOGICAL GROUNDS; VIEWS OF OTHER AUTHORS—BRONZING OF SKIN; CAUSES OF; VIEWS OF OTHER AUTHORS—CONDITION OF BLOOD IN ADDISON'S DISEASE—BRONZING OF SKIN DUE ALSO TO NERVE-LESIONS—ETIOLOGY OF ADDISON'S DISEASE—AFFINITIES WITH TUBERCLE; FREQUENT CO-EXISTENCE OF TUBERCULAR OR STRUMOUS DISEASE—EXTENSION OF INFLAMMATION TO SUPRA-RENAL CAPSULES FROM DISEASED OR INJURED ADJACENT PARTS; CASES OF ADDISON'S DISEASE ASSOCIATED WITH PSOAS OR LUMBAR ABSCESSSES—CASES ASSOCIATED WITH MORE DISTANT ABSCESSSES OR DISEASE OF BONES—CASES FOLLOWING A STRAIN, OR BLOW, OR PHYSICAL SHOCK, WITHOUT EVIDENCE OF LOCAL INJURY—CASES FOLLOWING OVER-EXERTION AND MENTAL ANXIETY—INFLUENCE OF SEX, AGE; AND OCCUPATION ON DEVELOPMENT OF DISEASE—DIAGNOSIS—PROGNOSIS—TREATMENT—SUMMARY.

MR. PRESIDENT AND GENTLEMEN,—The lesion in the supra-renal capsules in Addison's disease is produced, as I have shown, by the inflammatory exudation of low type, with which these organs become infiltrated. This exudation becomes converted into a firm fibrous material, which first encroaches upon and destroys the normal tissue of the capsules, and subsequently itself, together with the destroyed elements of the organs, undergoes degeneration into purulent, cheesy, or cretaceous material. (See Plate V. fig. 1.)

It might, not unnaturally, be supposed that this complete destruction of the normal structure of the supra-renal capsules must be the immediate cause of the symptoms of Addison's disease; or, in other words, that these symptoms

must result from the abolition of the proper function of those organs. This was evidently the opinion entertained by Addison when he published his book; for he expressed his belief that the urgency of the symptoms was determined by the actual amount, or degree, of the morbid change going on in the capsules; and that, whilst universal disease of both capsules would, in all probability, be found to prove uniformly fatal, cases in which the morbid change was limited to a single capsule might be found to present proportionately slighter results.¹ Since Addison's time, however, it has become generally recognised, by all those best acquainted with the subject, that the symptoms associated with the supra-renal lesion cannot proceed from mere destruction of the tissue of the capsules and consequent abolition of their function. Many physiological experiments have been made upon animals by Drs. Brown-Séquard, George Harley, and others, with the view of deciding this point; but, looking to the differences in their results, and to the doubt how far these may have been due to accessory differences in the operative processes, I am disposed to attach much more weight to certain clinical and pathological facts, which seem to me to determine the question.

In my last lecture, I think it was clearly shown, that when the normal structure of the supra-renal capsules is altogether supplanted by cancer, or has undergone complete fatty degeneration, none of the peculiar symptoms of Addison's disease are produced, notwithstanding the total destruction of the organs for all functional purposes. On the other hand, it is quite certain that, in many cases of Addison's disease, the conversion of the supra-renal capsules into a mass of fibroid tissue, and even the degeneration of this latter into cheesy material, must have been almost, if not

¹ On *Disease of the Supra-renal Capsules*, pp. 7 and 31.

altogether, complete, before the development of any of the characteristic symptoms of the disease.

In one of my own patients, for example, the profound alteration in the capsules, more especially in the right one, which consisted chiefly of cheesy masses with some gritty matter bound together by translucent tissue, could not possibly have taken place to any extent during the brief period of her illness;¹ and in other cases, in which the illness has been equally short, the capsules have been found in a still more advanced and complete state of degeneration. Mr. Stromeyer Little reports the case of a servant girl, aged fifteen, whose illness was first noticed only four weeks before her death; and yet both the supra-renal capsules were in great part 'made up of a material of yellowish colour, cutting like hard cheese, with here and there a little gritty matter,' and presented no trace of normal structure.²

The paroxysmal mode of progress, characteristic of the usual chronic course of the disease, is also quite adverse to the probability of the symptoms being due to abolition of the function of the capsules; for, in that case, the frequent rallyings from severe paroxysms of the symptoms could scarcely take place, when the nature of the local lesion must render any renewal of function impossible.

Again, it usually happens, in the case of other symmetrical organs, such as the lungs or kidneys, that, if only one of the two organs is rendered functionally useless by disease, the other acquires an increased functional activity; and, if life be not preserved, it is at least prolonged much beyond the average term in cases in which both organs have become diseased. In Addison's disease, on the contrary, in some of the very few cases in which one capsule only has been found diseased, the symptoms have nevertheless run a

¹ Case 25, Appendix B. See also Appendix A, p. 109, Case III.

² Case 52, Appendix B.

course in all respects resembling the usual course of the disease when both capsules are involved.

Thus, in a girl aged eleven, whose case was reported by Guttman in 1870, and who had been under observation during five months, the left supra-renal capsule only was found to be diseased, the right one being still perfectly intact;¹ but, nevertheless, the constitutional symptoms had been quite characteristic, and the discoloration of skin very fully developed. A more striking case of the same class, which had been under medical observation for some years, was published by Dr. Murchison in the 'Pathological Transactions' for 1866.² In the year 1864 the patient, a man aged twenty-seven, was in the Royal Infirmary of Edinburgh, where his case was diagnosed by Drs. Dyce Duckworth and Pye-Smith as a typical example of Addison's disease. He survived until April 1866, having been occasionally able to work at his trade during the periods of remission of his symptoms. At the autopsy only one of the supra-renal capsules was found to be diseased; the diseased organ exhibiting all the characteristic appearances of the capsules in Addison's disease, whilst the other had remained quite healthy.

Whatever, therefore, may be the hitherto undiscovered function of the supra-renal capsules, these facts would seem to justify the conclusion that abolition of that function, by whatever lesion it may be produced, cannot be the cause of Addison's disease. That disease being, nevertheless, invariably associated with one particular organic lesion of the supra-renal capsules, we must seek for some other means by which this lesion can give rise to the characteristic symptoms which indicate its presence. Manifestly, also, the condition to which we refer the production of these symptoms must

¹ Case 30, Appendix B.

² Case 114, Appendix B. See also Appendix A, p. 160, Case XXI.

be one which is found in connection with this one particular lesion of the capsules, and which is not associated with any of the other lesions of those organs, which equally destroy their structure, but, as we have seen, do not produce the symptoms of Addison's disease.

This condition is, as I believe, the extension of the chronic inflammatory process, which constitutes Addison's disease of the supra-renal capsules, from the diseased capsules to surrounding parts; a condition which I described, in my first lecture, as one of the characteristic features of the morbid anatomy of Addison's disease. This extension of the inflammatory process beyond the capsules produces, as I have stated, dense overgrowths of connective tissue, which form extensive adhesions between the capsules and neighbouring organs; and which, if merely by their pressure, cannot fail to affect in a very serious degree, not only those nerves which pass into and out of the capsules, but likewise all those which are in intimate relation with them.

Now it is certain that the supra-renal capsules, which lie in close contiguity to the solar plexus and semilunar ganglia, receive a much larger supply of nerves in proportion to their size than any other organs in the body. Kölliker says that he has counted as many as thirty-three nerve-trunks in the right supra-renal capsule;¹ and Lobstein, when describing, half-a-century ago, a case of tubercle of the capsules, stated that he had found eight nerve-branches going from the right semilunar ganglion to the right capsule, and thirteen from the left semilunar ganglion to the left capsule.²

Some physiologists, indeed, believe the supra-renal capsules themselves to be ganglionic nerve-centres. Thus, Kölliker considered the cortical and medullary portions of

¹ *Manual of Human Histology* (Sydenham Society's Translation), vol. ii. p. 218.

² *De nervi sympathet. human.* Paris, 1823. P. 160.

the organs to be physiologically distinct;¹ and, whilst regarding the cortical portions as 'blood vascular glands,' he looked upon the medullary portions as appertaining to the nervous system. Bergmann held very much the same opinion. More recently, Leydig has stated that the cells which are embedded in the meshwork of the medulla of the supra-renal capsules are of irregular form, and exhibit processes like the multipolar ganglion-cells of the brain and spinal cord. He further says, that a number of nerve-trunks which pass through the cortical portions of the capsules are lost in the medulla, and do not again pass out; facts which, he considers, compel the belief that the nerve-fibres arise in these ganglion-cells, and that the medullary portion of the supra-renal capsules is essentially a ganglionic nerve-centre.²

Although I cannot venture to pronounce an opinion on these histological and physiological views respecting the nature and functions of the supra-renal capsules, the observations I have quoted seem to render it certain that these organs have very intimate relations with the semilunar ganglia and solar plexus, by means of very numerous nerve-fibres. Dr. Habershon, to whose researches I have already referred, several years ago traced a direct branch of the pneumogastric nerve to one of the supra-renal capsules;³ and Bergmann found direct branches, both from the pneumogastric and phrenic nerves, passing to the supra-renal capsules.⁴ Dr. Sidney Coupland, also, when making the post-mortem examination of a girl who died recently in the Middlesex Hospital, under my care, of Addison's disease, dissected out very thoroughly the nerves in the vicinity of the supra-renal capsules, and distinctly showed a very con-

¹ *Loc. cit.*, vol. ii. p. 219.

² *Lehrbuch der Histologie des Menschen und der Thiere*. Frankfurt am Main, 1857. P. 189.

³ *Guy's Hosp. Reports*. Third series, vol. x. p. 83.

⁴ Kölliker's, *Man. Human Hist.*, vol. ii. p. 217.

siderable nerve-branch, in a greatly thickened condition, passing directly from one of the pneumogastric nerves to the neighbouring capsule.¹ The supra-renal capsules are therefore not only very intimately connected with the chief centre of the ganglionic nervous system situated in the abdomen, but also indirectly, through that centre, and more directly, through the pneumogastric and phrenic nerves, with the cerebro-spinal nervous centres.

It will readily be conceived that the pressure exercised by a mass of hard connective-tissue forming within and around the capsules, closely investing the nerves passing into those organs, and sometimes involving the semilunar ganglia and solar plexus, must seriously interfere with the functions of the nerve-branches embedded in the contracting growth. But, as we have seen, the injury to the nerves is by no means always limited to those branches which are actually bound up in the inflammatory new growth; for, in many cases, several of which were quoted in my first lecture, the nerves at some distance from the inflammatory tissue have been found enlarged, by reason of the increased thickness of their neurilemma—a condition which could only arise from the further extension of the inflammatory process along their sheaths. Moreover, though in numerous cases it is stated that the only change discoverable in the nerves was this increased growth of connective-tissue in their outer sheaths, in other cases inflammatory growths have been also distinctly seen in the connective-tissue sheaths of the individual nerve-fibres. Thus Hertz saw, in Van Geuns' case, to which I referred in my last lecture, numerous oval or spindle-shaped cells embedded in the connective-tissue between the nerve-fibres of the solar plexus and the semilunar ganglia.² This undue thickening of the neurilemma must naturally tend to

¹ See Appendix A, p. 128, Case VIII.

² See Appendix A, p. 177, Case XXVIII.

produce irritation, and ultimately atrophy, of the compressed medullary portions of the nerves, and these conditions have, in fact, been verified in many cases of late years.

The first notice, indeed, of a morbid condition of the nerves in Addison's disease, is by Addison himself, who records in his monograph that Mr. Quekett had found, on microscopical examination of a portion of the semilunar ganglion and solar plexus in one of his cases, that they had undergone some form of fatty degeneration.¹ Dr. Monro reported, only a year later, a case of Addison's disease, already referred to, in which he found the sympathetic nerves on the right side, going from the lesser splanchnic, greatly increased in size, as were also some of the branches, as well as the ganglia, of the solar plexus on the same side and in contact with the diseased capsule.² The texture of these nervous parts was of a rosy hue, as if under the influence of vascular excitement. But researches into the condition of nerves at autopsies were then much rarer than they are now, and the fullest and most accurate descriptions I have found are in the reports of recent and mostly of foreign cases.

Hertz found, in Van Geuns' case, both semilunar ganglia reddened on the surface and also on section, and the separate ganglionic cells so filled with granular pigment as almost to conceal their nuclei.³ Professor Tigri found, in Burresi's case, the whole sympathetic nervous system reddened and swollen, and the semilunar ganglia enlarged.⁴ Under the microscope, both ganglia and nerve-fibres showed remains of old and recent hæmorrhages, consisting of yellow granular corpuscles and of small roundish or irregular bright-red molecules, together with some still normal red blood-corpuscles. The cells of the enlarged semilunar ganglia, but

¹ *On Disease of the Supra-renal Capsules*, p. 3.

² See Appendix A, p. 172, Case xxvi.

³ See Appendix A, p. 177, Case xxviii.

⁴ See Appendix A, p. 179, Case xxix.

more especially of the left one, were opaque and granular, and showed no trace of nucleus; and it should be mentioned, in connection with this fact, that the left supra-renal capsule was double the size of the right one. Rindfleisch, again, in Kuhlmann's case, found the fibres of two nerve-trunks, embedded in the inflammatory adhesions of the capsule to neighbouring organs, in a state of partial fatty degeneration.¹ Van Andel states that in his case the microscope revealed atrophy of the sympathetic nerve and of the solar plexus, with almost total disappearance of the medullary cells, and pigmentation of the ganglionic cells.² Boogaard found, in a case of Schmidt's which he examined, the sympathetic nerve much atrophied;³ and Bartsch reports, in a case in which the pathological conditions of the supra-renal capsules were very characteristic, that the semilunar ganglia were of a greyish-red colour, and the ganglionic cells almost all filled with fat, and very few of them showing any nucleus.⁴

These numerous observations, by competent pathologists, leave no doubt that the antecedent probability of injury to the nerves in intimate relation with the supra-renal capsules, from the chronic inflammatory process going on around them, is borne out by the facts.

We now come to the question, how far the various symptoms of Addison's disease can be shown to be due to these morbid changes in the abdominal portions of the sympathetic nervous system. Addison himself conjectured, latterly, that the intimate connection of the supra-renal capsules with the nervous system had a large share in the production of the symptoms; and Drs. Wilks, Habershon, and others, adopted this view, and attributed them to the implication chiefly of the sympathetic nerve. But the belief in this

¹ See Appendix A, p. 181, Case xxx.

² See Appendix A, p. 182, Case xxxi.

³ See Appendix A, p. 187, Case xxxiv.

⁴ See Appendix A, p. 184, Case xxxii.

mode of production of the symptoms was at that time mainly hypothetical, and, as such, I attached little importance to it. Of late years, however, the observations which I have detailed have convinced me that the nerves in close relation with the supra-renal capsules are undoubtedly affected in every case to a greater or less extent, by the chronic inflammatory process of Addison's disease; and, from various analogies, I think it must be inferred that at least all the more important features and prominent symptoms of the disease are due to the morbid changes in the affected nerves.

These changes are, as I have shown, of two kinds; corresponding to two different stages of disease. In the earlier stage, the nerves connected with the supra-renal capsules and the semilunar ganglia are in a state of irritation; in the other, and later, stage, the structure of these same nerves, and even of the ganglia themselves, has become seriously injured, and we may presume that their functions must be greatly impaired. The first of these changes, the stage of irritation, is exemplified in the redness and swelling of the nerves and ganglia observed by *Monro*, *Hertz*, and *Burresi*, and may be regarded as the primary consequence of the extension of the inflammatory process to the nerves and local nerve-centres. The second change, attended by more or less complete impairment of function, consists in the atrophy and fatty degeneration of the nerves, described by *Quekett*, *Rindfleisch*, *Boogaard*, *Bartsch*, and others; and, it would naturally occur as a secondary consequence of the continuance of the stage of irritation.

It is obvious that such irritation of the nerves, as has been shown to exist in Addison's disease, would be likely to vary greatly in intensity in different cases, and even from time to time in the same case, according to the greater acuteness or chronicity of the inflammatory process in the supra-renal capsules. Such irritation also, though due to

a permanent cause, might very possibly subside more or less completely at intervals, under favourable circumstances, but would be readily rekindled by comparatively trivial causes. It is also quite conceivable that the implication of the nerves may not always take place with equal rapidity, nor at an equally early period of the disease.

If, then, the condition of the nerves may be expected to vary thus in different cases, and at different periods in the course of the same case; and, if the outward manifestations of the disease be produced only by the nerve-lesions; there would appear to be no difficulty in explaining, either the varieties in the course and symptoms of Addison's disease in different cases, or the marked alternations of remission and exacerbation frequently observed in the same case.

These views would also explain the occasional latency of the symptoms of Addison's disease for lengthened periods, and their sudden development on the occurrence of some external cause of depression; as well as the fact, to which I have already directed attention, that, at the post-mortem examination of patients dying of Addison's disease, after perhaps only a few days of obvious illness, the supra-renal capsules have been found in as advanced a stage of disease, and their natural structure as completely destroyed, as in patients who have died after a long course of fully developed typical symptoms.

Again, the individual constitutional symptoms of Addison's disease seem in great part explicable, either as direct effects of the nerve-lesions upon certain organs, or as secondary consequences of those lesions, through the medium of their interference with the circulation. In the first place you will have observed that branches both of the pneumogastric and of the vaso-motor nerves have been found implicated in the inflammatory process of Addison's disease. The pneumogastric nerve has very intimate relations with

the lungs, the heart, and the stomach, all of which organs are functionally disordered in Addison's disease. It is, therefore, probable that such symptoms as the sighing, yawning, hiccup, and the irritability of stomach, may result, at least in part, from the lesions of the peripheral branches of the pneumogastric nerve distributed to the supra-renal capsules and solar plexus.

Physiological investigations appear, also, to throw light upon the relation between the lesion found in the vaso-motor nerves and semilunar ganglia and many of the prominent symptoms of Addison's disease. It is stated, as the result of physiological experiment, that lesions of the sympathetic nerve-centres of the abdomen, by removing or diminishing the vaso-motor influence, give rise to functional dilatation of the blood-vessels and to a consequent excess in the supply of blood to the abdominal viscera; from which a corresponding drain of blood from the other organs of the body would necessarily follow. Such a condition, in Addison's Disease, would sufficiently explain the extremely small, compressible pulse, the asthenia, listlessness, and indisposition for exertion; the excessive feebleness without corresponding muscular emaciation, the shallow respiration and breathlessness on exertion; all of which symptoms point to some deficiency in the supply of blood to the affected organs. The symptoms more directly referable to the nervous system—the occasional dimness of sight or impaired hearing, the vertigo, delirium, and coma, the muscular rigidity, tremors, convulsive twitchings of the face and limbs, and even the epileptiform attacks recorded in some cases—may also with much probability be regarded as the effects of some interference with the due supply of blood to the great nerve-centres. They closely resemble, indeed, the nervous phenomena which sometimes follow copious hæmorrhages. It is true that, in Addison's disease, there is no

actual loss of blood, but it seems of little importance, as regards the effect upon the brain, to what cause the deficient supply of blood be due; whether it arise from actual hæmorrhage, from the failure of the heart to send an adequate supply of blood to the brain, or from a drain of blood from the cerebral arteries produced by an inordinate flow towards the abdominal viscera at the expense of other organs.¹

One objection to this view is that, generally speaking, no evidence of there having been over-fulness of the abdominal vessels appears to have been found after death, either in the form of vascular distension, or of exudation into the tissues of the congested organs. Even congestion of the abdominal viscera has only been noted in comparatively few instances, and I have found no considerable degree of it existing in any of my own cases.² The action of the heart is, however, so feeble in Addison's disease, that no active hyperæmia of the abdominal organs would be likely to occur; nor, except in cases of long duration, would any permanent enlargement of the calibre of the abdominal vessels be at all likely to take place; so that even if congestion had existed, more or less, during life, it would not follow that, in the majority of cases, any sufficient proof of its existence should be found after death. The large, soft, dark-coloured spleen, not unfrequently mentioned in chronic cases of Addison's disease, is, in all probability, the one result of the long-continued excess of blood in the abdomen which most often remains in evidence.

¹ As bearing upon this subject, see Dr. Tappeiner's report of the comparative effects produced upon the circulation, in animals, by tying the portal vein and by taking blood from the carotid artery.—Ludwig's *Arbeiten aus der Physiol. Anstalt zu Leipzig*, Jahrgang vii. 1872. P. 20.

² One case has, nevertheless, come under my observation since these lectures were written, in which great venous engorgement of all the abdominal viscera was found after death. The patient died recently of Addison's disease in St. Thomas's Hospital, under the care of Dr. Bristowe. See Appendix A, p. 133, Case x.

With respect to the changes in the gastric and intestinal mucous membranes, there is also strong physiological evidence in support of the belief that they are caused by the lesions of the pneumogastric nerves, semilunar ganglia, and solar plexus. Pincus states that section of the pneumogastric nerves and extirpation of the solar plexus, in animals, is followed by hyperæmia, ecchymoses, and ulcerations of the stomach and upper part of the intestinal canal.¹ The catarrhal and other affections of the mucous membrane of the stomach, and the enlargement of the solitary and agminated glands of the small intestine, so frequently found in chronic cases of Addison's disease, would thus appear to be the direct results of the interference with the functions of the abdominal nerve-centres by the extension to them of the inflammatory process from the supra-renal capsules.

Some of these physiological experiments are quoted also by Dr. Risel, of Halle, in an able paper on the Pathology of Addison's Disease, in which he expresses views on the subject agreeing in many respects with my own.² Like myself, he attributes the more prominent symptoms of the disease to lesions of the nerves secondary to the lesion in the supra-renal capsules; and he considers them to be the direct results of excess of blood throughout the abdominal cavity consequent on impairment of vascular tone.

Many other foreign writers have concurred in attributing the constitutional symptoms of Addison's disease to some lesion of the nervous system, but they differ widely in their ideas of the relation which subsists between the supposed nerve-lesion and the disease in the supra-renal capsules, and also with respect to the means by which the symptoms are produced. Schmidt, Burresi, and Kuhlmann have concluded,

¹ *Henle u. Pfeufer's Zeitschrift f. Rat. Med.* 1856. Dritte Reihe, vol. ii. p. 352.

² *Deutsches Archiv f. Klin. Med.* vol. vii. p. 42.

from the important nerve-lesions found by them in cases of Addison's disease, that the essence or primary cause of the disease is a morbid affection of the sympathetic or trophic system of nerves, and that the disease in the supra-renal capsules is only a secondary phenomenon or incidental complication.

To these theories it would seem sufficient to oppose the fact, that there is no single case on record in which the group of symptoms characteristic of Addison's disease has been observed during life, and in which, after death, the affection of the nerves, supposed by these writers to precede, or to give rise to, the disease in the supra-renal capsules, has been found to exist unassociated with this latter. Neither, amongst the many hundred post-mortem examinations annually made in the London hospitals, has, so far as I can discover, any similar condition of the abdominal nerve-centres ever been found unassociated with inflammatory disease of the supra-renal capsules.

Bartsch considers it doubtful whether the supra-renal capsules or the semilunar ganglia will be found to contain the centre of the trophic nerves, which he regards as the true seat of the disease.¹ Rossbach, as I have said, deduces, from the case related in my last lecture, an altogether new theory of the nervous origin of the symptoms of Addison's disease.² He attributes them entirely to functional disturbance of the cerebro-spinal nervous system, produced by long-continued grief and trouble, and bearing a close analogy to the nervous ailments which produce hysteria. He includes the two diseases under the head of 'general neuroses with unknown anatomical causes,' and concludes that, as hysteria often exists without uterine disease, so the lesion in the supra-renal capsules bears no constant

¹ *Central Blatt. f. Med. Wiss.* vol. v. p. 397.

² *Virchow's Archiv f. Path. Anat. etc.* vol. li. p. 100.

relation to Addison's disease. Had the premises only been correct, it would have been difficult to controvert his arguments; but he had to do, as we have seen, not with a case of Addison's disease at all, but with a case of hysterical mania, aggravated no doubt by the irritation of the scleroderma, from which the patient was also suffering, and complicated with degenerative disease. Consequently, his arguments, which are convincing enough as to the origin of the symptoms in the case really before him, have no bearing whatever upon the question of the origin of the disease with which he supposed himself to be dealing.

Owing to the undue prominence which has always been given to the bronzing of skin as a symptom of Addison's disease, the character and causes of this abnormal pigmentation have been far more fully and widely discussed than those of the constitutional symptoms.

Virchow, in his work on Tumours, expresses his belief that the bronzing of skin is due to affections of the nerves in close relation with the supra-renal capsules; without reference, however, he considers, to the particular nature of the morbid process in those organs.¹ Bühl regards the pigment-deposit as the direct result of a blood change, characterised by a deficiency of fibrine, excess of white corpuscles, and unusually dark colour of the blood.² I should remark, by the way, that the four cases upon which Bühl founded this opinion were all complicated with general disease of the lymphatic glands, or extensive tuberculosis, and with great enlargement of the spleen, in one case to four times its natural size; and, though in some of them the capsules seem to have presented the appearances of Addison's disease, in one at least they certainly did not. The other conditions, found in these four cases, are such as are well known to be associated with leukæmia and

¹ *Die Krankhaften Geschwülste*. Berlin, 1864-5. P. 701.

² *Wiener Med. Wochenschrift*. 1860. P. 22.

melanæmia. Martineau holds that the bronzing of skin, though most frequently associated with disease of the supra-renal capsules, is really independent of its existence, 'because equally common in tuberculous, cancerous, and miasmatic cachexias.'¹ This I have clearly shown to be a misconception, as regards the peculiar discoloration of skin characteristic of Addison's disease. Jaccoud, in his able article on 'Bronzed-skin Disease' in the new French Dictionary of Medicine, attributes the pigmentation, in Addison's disease, to irritation of the vaso-motor sympathetic nerves excited by the supra-renal lesion; but he considers the length of time requisite for the hypersecretion of pigment, by this means, to be the obvious explanation of the earlier development of the constitutional symptoms.² This latter view is negatived by the fact that, in a considerable number of cases, several of which were quoted in my first lecture, the bronzing of skin has been observed for longer or shorter periods before the development of any of the constitutional symptoms. Bartsch is of opinion that the bronzing of skin is the consequence of disease in the centres of the trophic nerve-fibres of the skin, and does not believe that change of the blood-colouring matter can produce it. Risel, on the other hand, is of opinion that, although vaso-motor influences may have a share in causing the pigmentation of the skin in Addison's disease, it cannot be sufficiently accounted for without the supposition of some abnormal state of the blood. This he believes to consist in an altered condition of the hæmoglobin, due to the change in the spleen and lymphatic glands, as well as to the diminished nutrition arising from the catarrh of the stomach and intestines.

So far, however, as I have been able to ascertain, the

¹ *De la Maladie d'Addison.* Paris, 1864. P. 121.

² *Nouveau Dict. de Méd. et de Chirurg. pratiques.* Paris, 1866. Article 'Maladie Bronzée,' vol. v. p. 729.

composition of the blood does not undergo any important alteration in uncomplicated cases of Addison's disease. In all my later cases the blood has been examined microscopically, with virtually negative results. In one woman, who was anæmic, and had never been robust since an attack of scarlatinal dropsy seven years before her last illness, the white corpuscles were slightly in excess; but, in all other respects, the blood appeared perfectly normal, the red corpuscles being abundant, and forming rouleaux in the usual manner. In another of my patients, who had been in the hospital previously, and was readmitted on account of the extreme prostration following loss of blood from a slight wound on the forehead, the blood, when first examined, was not exactly normal. There was no marked excess or diminution of white corpuscles; but there was a deficiency of red corpuscles, and those present did not form into rouleaux, but were scattered singly over the field. There was also a large number of globular highly refractive nuclei, of a red colour, measuring on an average $\frac{1}{4300}$ of an inch in diameter, mostly lying isolated, but here and there aggregated in groups. At the end of three weeks, however, when the patient had recovered her strength, the abnormal conditions of the blood had disappeared, and their temporary existence could not well be a specific result of Addison's disease, seeing that precisely the same appearances were found, though to a less marked extent, in the blood of two other patients who were in the hospital at the same time, one of whom was suffering from constitutional syphilis, and the other from simple debility and anæmia. Since the delivery of my last lecture the courtesy of Dr. Bristowe has given me another opportunity of examining the condition of the blood in a well-marked case of Addison's disease.¹ The patient, a woman aged forty-eight, who is at present under his care in St.

¹ See Appendix A, p. 131, Case x.

Thomas's Hospital, is suffering from extreme debility and nausea; her circulation is so feeble that it was most difficult to obtain a tracing of the pulse, and she is quite as dark as a mulatto. Nevertheless, her blood was found, on microscopical examination, to be rich in red globules, which arranged themselves freely in rouleaux, and it certainly did not contain any marked excess of white corpuscles. A few of the small highly refractive bodies, described as having been present in my own case, were scattered singly over the field.

Dr. Thudichum, who examined chemically, for sixty-five continuous days, the urine of a patient who died in the Middlesex Hospital, under the care of Dr. Burdon Sanderson, found a great deficiency in the uric acid and colouring matter. He concludes from his researches that 'the brown deposit in the skin is the varying balance of a current account,' which 'may increase or decrease.'¹ Apparently he means to infer that the abnormal deposit of pigment in the skin is an alternative result of these deficiencies in the composition of the urine, and varies in intensity according to their variations. Mr. West, in a paper recently read before the Royal Medical and Chirurgical Society, states the exact amount of the deficiency in the proportion of urea excreted in a case of Addison's disease.² His analyses, though few in number, agree with the results obtained by Rosenstein from analyses of urine in some cases of Addison's disease, in which he always found the quantity of urea excreted to be deficient, and that of indican in excess.³ It appears to me, however, that no inferences can be drawn from the results of these researches with respect to the production of the bronzing of skin. I believe the deficiency both of uric acid and of urea

¹ *Tenth Report of the Med. Officer to the Privy Council.* London, 1868. P. 281.

² Not yet published.

³ Virchow's *Archiv*, vol. lvi. pp. 27-37.

in the urine to be due to the diminished waste of tissue, invariably characteristic of Addison's disease. The excess of indican is perhaps more directly due to altered nervous influence, for I have repeatedly found it in the urine of patients who had just recovered from the collapse stage of cholera, or who were suffering from certain diseases of the spinal cord.

My own opinion is, that the change of colour in Addison's disease is undoubtedly produced, like the constitutional symptoms, through the medium of the nervous system. The paling of the discoloration coincidently with remissions of the constitutional symptoms, and its deepening and extension with every fresh exacerbation of the illness, appear to me to afford strong clinical evidence that these two features of the disease are referable to a common cause. There is, however, no evidence which enables me to refer the discoloration of skin directly to any of the nerves actually involved in the inflammatory process, and I am inclined to attribute it, rather, to reflex irritation through the cerebro-spinal nervous system.

Although the correctness of these inferences is not susceptible of proof, without much clearer knowledge than we now possess of the part actually played by the nerves in the physiological processes disturbed by the disease, I venture to think that the views I entertain derive considerable support from the clinical and pathological facts upon which they are based.

The still more obscure question of the etiology of the inflammatory disease in the supra-renal capsules remains to be considered.

Nearly ten years ago, in a paper read before the Pathological Society, I observed that the production of the symptoms of Addison's disease by means of the implication of the nerves was, after all, a secondary question to that of the

origin of the supra-renal disease itself, of which the nerve-lesions were the consequence, not the cause. This is still my opinion; but, unfortunately, it is even more difficult to throw light upon the question of the etiology of the disease than upon that of its pathological processes; and this difficulty is owing, not only to the peculiar obscurity of the subject, but to the absence, in a large proportion of the cases on record, of many of the data required in order to allow of any positive conclusions being drawn from them.

There are, at the same time, some pathological conditions recorded in association with Addison's disease, in so considerable a number of cases, as to leave no doubt on my mind that they are not accidental complications, but have a real, and more or less causal, connection with the disease; and these conditions I shall now proceed to consider.

In describing the characters of the lesion in the supra-renal capsules, I have purposely avoided the use of the term 'tubercular,' lest I should convey an erroneous impression; but the product of the chronic inflammatory process has, undoubtedly, analogies with tubercle, and it has been termed 'tuberculous,' 'strumous,' and 'scrofulous,' more often than inflammatory. It may, indeed, be a question whether the distinction between inflammatory and tubercular deposits can be so clearly drawn as was formerly thought; for even the giant cells, relied on by Schüppel as decisive of the presence of tubercle, are now stated to be merely characteristic of chronic inflammatory processes in lymphatic structures.¹

Be this as it may, it is impossible to resist the evidence of clinical facts as to the existence of some affinity between Addison's disease and the tubercular diathesis. By far the larger proportion of the diseases of other organs, found in

¹ Green, *Introduction to Pathology and Morbid Anatomy*. Second Edition. London, 1873. P. 212.

association with Addison's disease of the supra-renal capsules, are diseases of tubercular or strumous character. In the typical cases, it is true, these complications are either altogether absent, or are indicated only by small tubercular concretions in the lungs, some of which are described as cheesy, some as calcareous, others as peri-bronchitic nodules, and others again simply as indurations in the apices of the lungs. But a very considerable proportion of the other cases are complicated with more or less active tubercular disease; and, in a certain small number of cases, the inflammatory lesion in the supra-renal capsules has been found co existing with advanced phthisis or general tuberculosis.

This connection between Addison's disease and the tubercular diathesis may be explained in two ways. Even if the general tubercular disease and the inflammatory lesion in the supra-renal capsules never stand to each other in the relation of cause and effect, it can be no matter of surprise, seeing how much a 'vulnerable' constitution, as Virchow calls it, predisposes to the development of low chronic inflammatory processes, that these two diseases should not unfrequently be found co-existing in the same patient. There have been, however, a very small number of cases, in which it does appear to me as if the lesion in the supra-renal capsules, characteristic of Addison's disease, had arisen as part of a general chronic tubercular process going on at the same time in several other organs. It will be remembered that in those particular cases, which were discussed in my last lecture, the characteristic symptoms and bronzing of skin were altogether undeveloped. Although this is a part of the subject on which I desire to speak with great diffidence, seeing that it is a question which can only be determined by further clinical and pathological investigations, I may say that it seems to me by no means improbable that, in certain cases, secondary deposits of tubercle may have taken place in the

capsules, to the extent of entirely destroying their structure, without having produced the inflammatory nerve-lesions which I regard as essential factors in the development of the symptoms of Addison's disease.

It is much more certain that Addison's disease is frequently due to the extension of inflammation to the supra-renal capsules from diseased or injured adjacent parts. I have records of fourteen cases in which psoas abscesses, connected with caries of the lower vertebræ, or other abscesses in the immediate vicinity of the capsules, have been followed or accompanied by Addison's disease.¹ In three more cases there is stated to have been angular curvature of spine or disease of lumbar vertebræ;² and in several other cases, in which the vertebral column and neighbouring parts were not examined after death, distinct tenderness on pressure was observed over two or more of the lower dorsal and upper lumbar vertebræ; so that I believe the number I have stated by no means represents all the cases in which this form of disease has given rise to the inflammatory lesion in the supra-renal capsules.

There is clear evidence, in many of the fourteen cases, that the abscesses had existed previously to the supra-renal lesion, and in some cases they had even become entirely quiescent for several years before the development of any of the symptoms of Addison's disease. A man aged twenty-four, who died of that disease in St. Bartholomew's Hospital, under the care of Sir George Burrows, had suffered in childhood from spinal disease, and two years before death from spinal abscess, which healed after a few months.³ His last illness was of eight months' duration, and after death the bodies of the fifth and sixth dorsal vertebræ were found to be destroyed,

¹ See Appendix B, Cases 15, 121, 133, 137, 138, 145, 152, 160, 169, 181, 203, 207, 211, and Appendix A, p. 129, Case VIII.

² See Appendix B, Cases 124, 141, 173.

³ Case 152.

but there was no active disease. Both supra-renal capsules contained purulent fluid, and yellowish pea-sized bodies, resembling concrete tubercular matter. Again, in a deformed woman, aged twenty-six, who died under the care of Dr. McDonogh of Clapham, of Addison's disease, and whose case is recorded by Dr. Wilks, the lower dorsal and one or two of the upper lumbar vertebræ were found, at the autopsy, to be almost destroyed;¹ and, around them, adjacent to the supra-renal capsules on either side, was found a quantity of putty-like and cretaceous matter, the remains of an old abscess. The supra-renal capsules presented the characteristic appearances of Addison's disease, in a not very advanced stage.

This seems to me a point of so much importance in its bearings on the etiology of Addison's disease, that I will quote also two of the fourteen cases, in which inflammatory processes, not connected with disease of the spine, had apparently, by reason of their close proximity to the supra-renal capsules, been the exciting cause of Addison's disease.

The first is a case published by Dr. Cotton, of Lynn, in which the patient, a member of our own profession, had suffered in the year 1847 from an abscess in the right lumbar region, which produced very serious effects upon his health; but, contrary to expectation, he recovered and remained well until 1854.² His complexion then underwent a marked change, and, somewhat later, the constitutional symptoms of Addison's disease supervened. After several alternations of remission and exacerbation, the patient died in April 1857; and, at the autopsy, a fibrous-looking obliterated sinus was found, proceeding from the cicatrix of the old abscess in the right loin to the site of the structures in which the diseased capsules were firmly embedded. The disease in the right capsule appeared older than in the left. The other case is that of a labourer aged thirty-seven, a patient under the

¹ Case 181.

² Case 15. See also Appendix A. p. 167, Case xxiv.

care of Niemeyer, by whom the case was diagnosed as one of Addison's disease three or four years before death, and it was published as such, by Averbek, during the patient's lifetime.¹ The results of the autopsy were reported by Schüppel. The disease seems to have run a slow and sluggish course, complicated by successive abscesses and fistulæ in various parts of the body. The symptoms and discoloration were both characteristic, and the patient died in a sudden paroxysm of nerve-paralysis. The supra-renal capsules were found in the usual conditions characteristic of Addison's disease; the right one still showing a trace of normal structure, and both being embedded in much firm tissue. The left capsule and kidney were blended into one mass with the neighbouring portion of the descending colon, by means of firm tissue traversed by strong fibrous threads. The colon was, at this part, the seat of an extensive cicatrix of a large ulcer, which had at some previous time involved the whole tube, and had much contracted it by thickening its walls. The colon was adherent to the pancreas by the same mass of firm tissue which bound it to the left supra-renal capsule.

In the four cases I have just quoted, the inflammatory disease, which appears to have spread to the supra-renal capsules, was apparently due to constitutional tendencies; but, in several of the other cases of this class, there is a distinct history of local injury which has obviously produced it, and in apparently healthy subjects.

The most striking case of this kind which has come under my own observation, is that of a coal-porter, aged thirty-three, who was admitted into the Middlesex Hospital in the year 1866, under Dr. Stewart's care.² His health had been robust until about three years before his death, when he severely strained his back in pushing a loaded coal-

¹ Case 169. See also Appendix A, p. 184. Case xxxiii.

² Case 138. See also Appendix A, p. 114, Case v

truck, and felt a sensation as if something had given way. From that time he constantly felt more or less pain in the loins, but the first symptoms of Addison's disease supervened only ten months before his death, or two years after the accident. The case, like most of those belonging to the class I am discussing, was quite typical as regarded the constitutional symptoms and bronzing of skin. At the post-mortem examination the supra-renal capsules were both found embedded in thick fibrous tissue and adherent to surrounding parts; the right one was much enlarged and nodulated, and consisted of semi-transparent tissue, yellow cheesy masses, and small calcareous patches; the left capsule was smaller than the right one, and contained more calcareous matter. Adjacent to the capsules, in front of the lower dorsal and upper lumbar vertebræ, was a largish abscess, bounded by firm fibrous investments. Lastly, on examination of the spine, the intervertebral substance between the lowest dorsal and first lumbar vertebræ was found to be separated from the upper surface of the last-named vertebra, on the left side, for two-thirds of its depth, but the separation did not extend to the spinal canal. The upper surface of the first lumbar vertebra was bare and rough. The clinical history and pathological conditions, in this case, scarcely leave room for doubt that the separation of the intervertebral substance took place at the moment of the strain, three years before death; and that this injury gave rise, primarily, to the abscess in front of the injured parts, and, secondarily, by extension of inflammation from this abscess, to the disease in the supra-renal capsules.

Another remarkable case of the same character was published by Dr. Grey Glover in the 'Edinburgh Medical Journal' for 1859.¹ The patient, a furnace-man at some chemical works, had hurt his back by a fall. Three years

¹ Case 133.

later he became of a yellow colour, and was supposed to be jaundiced. Notwithstanding medical treatment, this discoloration of skin never left him, and it ultimately deepened into the typical bronzing of Addison's disease. The peculiar constitutional symptoms only began to develop three years after the first appearance of the discoloration of skin, and the patient died after two years' illness. The supra-renal capsules were found to be entirely destroyed; they consisted of semi-translucent deposit, with some opaque white material and cretaceous masses. In this case, also, there was psoas abscess with caries of the two lower dorsal and two upper lumbar vertebræ. Dr. Wilks, to whom the capsules were submitted for examination, pronounced the case to be a capital example of the disease; and, in referring to it, stated that the fact of caries of the spine being the only disease which had, in two or three instances, been found preceding Addison's disease, strongly suggested the opinion that the capsules might have been secondarily affected by it.

In ten or twelve other cases, abscesses, frequently connected with disease of bones, or otherwise apparently of scrofulous character, have been found in situations more or less remote from the diseased supra-renal capsules.¹ In several of these, as in many of the cases complicated with tubercle in the lungs, the only connection between the two diseases has probably been the constitutional vice which predisposed to the development of both; but in other cases, in which the local seats of inflammation were not far removed from the supra-renal capsules, the disease probably spread, as in Dr. Cotton's case, by continuity of tissue, although the connection was overlooked at the post-mortem examination. In a case of my own, that of a man aged twenty-four, who

¹ Cases 130, 136, 140, 142, 147, 149, 151, 153, 156, 166, 178, 210. Appendix B.

died in the Middlesex Hospital in the year 1864, there had been abscesses in the left hypochondrium about nine months previously.¹ Soon after it healed he was attacked with severe pain in the left hip, which never left him. Typical symptoms of Addison's disease supervened, together with discoloration of skin, and he died in a few months. The capsules exhibited the usual characteristic changes; and a small abscess was found, situated underneath the pelvic fascia, containing about half-an-ounce of pus, and directly communicating with carious bone at the left sacro-iliac synchondrosis. I have since suspected that I overlooked a connection between this abscess and the tissues adjacent to the supra-renal capsules; it is certain, at least, that, not fully appreciating at that time the important bearings of such a connection, I made no sufficient search for it.

I must now invite your attention to another class of cases: namely, cases of Addison's disease in which no pathological evidence was found of the existence of any local lesion, from which there could have been extension of inflammation to the supra-renal capsules; but in which, nevertheless, the clinical history of each case very decisively points to some physical shock, severe strain, or blow, usually in the back, as the starting-point of the illness.

Unfortunately, the previous history is wanting in so large a proportion of cases that I can only quote seven cases of this class.² A woman, aged thirty-one, who died under my care in 1858, when I was physician to the Western General Dispensary, always assured me that she had never recovered from a strain in the back, received in turning a mangle some years before her last illness.³ A female servant, aged thirty, who died in the Middlesex Hospital under the care of Dr.

¹ Case 136. See also Appendix A, p. 104, Case II.

² Cases 10, 25, 67, 71, 114, 158, 183, Appendix B.

³ Case 25. See also Appendix A, p. 101, Case I.

Burdon Sanderson, was laid up for a week with pain in her back caused by a fall down stairs, and began to fail in health from that time.¹ A druggist's assistant, a lad of sixteen, fell through a trap-door, and, although Dr. Bristowe, whose patient he was, could not discover any signs of disease in the bones of the spine or pelvis, the lad's illness undoubtedly dated from that fall, which he survived sixteen months.² A blacksmith, aged thirty, whose case is reported by Dr. Murchison, dated the commencement of his illness from a violent fall on the back four or five years before his death.³ A labourer, aged thirty-three, who had formerly been a cavalry soldier, stated to Mr. Workman that he had been ailing ever since his horse fell on him and hurt his loins, four years before his death.⁴ In a case reported by Dr. Risel, a bricklayer, aged twenty, had fallen from a scaffolding nearly two years before his death, and although he remained well in health until the last three months of his life, his relations had noticed the gradual and apparently causeless discoloration of his skin for more than a year.⁵ In another German case, recorded by London, the discoloration of skin and pains in the region of the liver and spleen followed a fall over a bank, which rendered the patient unconscious for some minutes.⁶

No disease of the spine, or of other bones, is reported in the post-mortem examinations of any of these cases, and in several of them it is certain that none existed.

In five out of the seven cases, however, some tubercles or cheesy nodules are reported to have been found in the apices of the lungs, giving evidence of the existence of the tubercular diathesis, with which Addison's disease appears to have

¹ Case 71. See also Appendix A, p. 145, Case XVI.

² Case 10. See also Appendix A, p. 160, Case XXII.

³ Case 111. See also Appendix A, p. 158, Case XXI.

⁴ Case 183. ⁵ Case 67. ⁶ Case 158.

so strong an affinity ; and which, probably, may have pre-disposed these persons to its development, from slighter and more temporary causes than would have given rise to it in persons of a more robust constitution.

In four or five cases the patients have referred their illness to physical over-exertion, in about the same number to nervous shocks, grief, or heavy anxiety, and in two or three cases to attacks of intermittent fever. The evidence in these cases is of course more or less vague and questionable ; and, due regard being had, both to the inadequacy of the supposed causes and to the occasional latent course of the disease, it may fairly be conjectured that the lesion in the supra-renal capsules existed antecedently to the supposed cause of the illness, which was only the immediate exciting cause of the manifestation of the symptoms. It is well, however, not to overlook any aspect of so obscure a subject, and therefore, without attaching undue importance to the supposed facts in the history of these cases, I think it as well to keep them in view.

There still remains a majority of the whole number of cases in which neither the clinical history nor the pathological reports afford any clue to the origin of the disease in the supra-renal capsules. In many cases, indeed, the previous history is, as I have said, either sadly defective, or altogether wanting ; but, in many others, the records, though apparently complete, show no trace of any antecedent cause. Good health, until the apparently causeless beginning of the fatal illness, is perhaps the most frequent history ; and, in typical cases, the usual report is that all other organs were healthy ; the exceptions to this rule being, as I have said, the frequent presence of small inactive tubercular deposits in the lungs.

In this absence of all internal conditions, and of all direct evidence of external injuries, which might serve to refer the

origin of Addison's disease, in these cases, to any of the causes which have been apparently its starting-point in the cases which I have discussed, we must fall back upon the indirect information to be derived from the very obvious influence of sex, age, and occupation on the development of Addison's disease.¹

Taking the one hundred and eighty-three cases,² which I have classed as unequivocal examples of the disease, I find, as regards sex, that in one hundred and nineteen of these cases the patients were of the male sex, whilst in sixty-four they were females.

As regards age, my analysis shows that by far the larger number of the sufferers were persons in the most active period of adult life. Of the one hundred and nineteen males, ninety-two died between the ages of twenty and fifty, whilst nineteen boys died under the age of twenty, and eight men over the age of fifty. The two youngest boys were aged eleven and thirteen years respectively, and the oldest man was fifty-eight years of age. Again, of the sixty-four females, forty-seven died between the ages of twenty and fifty, ten girls under the age of twenty, and seven women over the age of fifty. The two youngest girls were also aged eleven and thirteen years, and all the seven older women were under sixty, except one, who is stated to have reached the age of sixty-nine.

If we now look to the rank in life and occupations of the sufferers, we perceive that more than nine-tenths of the whole number have belonged to those classes which are engaged, throughout the active period of life, in physically laborious work. Only eight or nine of the male patients have belonged to the classes of gentry, professional men, or merchants; whilst not more than six of the females have

¹ See details on these points subjoined to cases in Appendix B.

² Comprised in Groups I.-III, Appendix B.

been in the position of ladies. With respect to the occupations of the men, and still more those of the women, the data are very deficient; but the fact that they were apparently, almost all, in the class of hospital patients speaks for itself, as to the probability of their having led a life of hard labour, in some form or other. Of the eighty men belonging to the working classes whose occupations are recorded, fifty-one were employed as agricultural labourers, blacksmiths, engine-men, stonemasons, bricklayers, carpenters, porters, sailors, or in other outdoor labour; about twenty were journeymen saddlers, bakers, shoemakers, tailors, or followed other indoor trades; whilst a few were publicans, shopkeepers, clerks, or had other miscellaneous occupations. With respect to the large majority of the women of the working classes, we have no information beyond their age. Of the sixty-four women, eight are stated to have been servants, maids-of-all-work, laundry-maids, or cooks; six, needlewomen; and three, outdoor labourers. Some, and in all probability very many, of the others were poor married women; and on no other class of their sex, perhaps, rests a heavier burden of labour.

Lastly, with respect to the great rarity of the disease in persons exempt from the risks and fatigues of bodily labour, I may quote my own experience. Although seven or eight cases have been referred to me in private practice, within the last five years, as supposed cases of Addison's disease, only two of these have been true cases; and I have met with no others among persons of the middle or higher classes. I believe, too, that in this respect the experience of all other physicians will be found to coincide with mine.

From these data therefore, imperfect as they are, the following deductions may safely be drawn:—

The occurrence of Addison's disease is exceedingly rare, excepting in persons employed in active manual labour.

The mortality caused by it is proportionably distributed over the laborious period of life, and to that period it is almost entirely confined.

The disease is comparatively much more frequent in persons of the male sex, whose employments naturally comprise the heaviest kinds of labour.

And, lastly, a preponderating number of the cases which occur in persons of the male sex are found amongst outdoor labourers, or amongst those other classes of workmen whose occupations are likely to expose them to injury from accident or over-exertion.

The facts thus brought out cannot fail to suggest the probability that, in many of these cases, external causes of local inflammation may have existed, similar to those which appear to have been the starting-point of the disease in the seven cases which I have quoted. Strains and falls which do not involve permanently disabling consequences are soon forgotten, and therefore seldom reported, by persons of the hard-working classes; whilst the very necessity, which such persons are under, of striving against the weakness induced by a strain or a blow, may tend to keep up an inflammatory process, which, in persons differently circumstanced, would probably subside under favourable conditions of rest.

Without, therefore, venturing to speak dogmatically on a subject which cannot be cleared up without much future investigation, I may yet say that I incline to believe the origin of Addison's disease in many of the unexplained cases to have been due to traumatic causes, although its development may probably have been favoured by certain constitutional proclivities.

At the same time, I must admit, that there are a certain number of the typical cases which afford no apparent ground for explanation on this hypothesis. A few ladies and gentlemen, in good circumstances, have suffered from Addison's

disease, although nothing in the history of their cases justifies the assumption of any local injury as the origin of the supra-renal disease. For the elucidation of these cases we must be content to await the result of further researches.¹

Very few words need be said here with respect to the diagnosis and prognosis of Addison's disease. The diagnosis is founded upon the constitutional symptoms, aided, in a large majority of cases, by the presence of more or less of the peculiar change of colour in the skin. It is not always unattended with difficulty, but, to those who have any practical acquaintance with the disease, it is not, I think, more difficult than the diagnosis of many other chronic diseases. The prognosis is invariably grave, as regards the ultimate result, for the disease is obviously incapable of cure; but it is, at the same time, in no small degree amenable to treatment in respect of delaying its progress; and, unless the illness have arrived at its latest stage, it is impossible to say to what extent life may be prolonged under favourable circumstances.

Rest, and scrupulous avoidance of bodily and mental excitement, and of all other causes of nervous exhaustion, form the most essential parts of the general management of the disease. Absolute confinement to bed during the paroxysms, and for some time afterwards, has appeared to contribute greatly to the restoration of those patients who have rallied under my observation.

The diet and therapeutic treatment must be carefully adapted to the varying phases of the disease. The profound asthenia by which the paroxysms are invariably characterised, and the distressing retching and vomiting which usually

¹ It is possible, however, that, if the significance of local injuries in such cases had been understood, closer investigation of the previous history might have brought out facts similar to the 'leap from a stage coach 'causing' internal ailments,' which is recorded by Dr. Monro in the case of a clergyman's wife. (Case xxvi., p. 172, Appendix A.)

accompany them, clearly demand the use of such therapeutic remedies as are calculated to mitigate these exhausting symptoms, and of such tonic treatment and nutritive diet as may tend to invigorate the system. For the relief of the irritability of stomach, ice, soda-water and brandy, creosote, bismuth, and effervescing medicines with citrate of iron, have each at times proved useful in my hands, whilst, at other times, each of them has failed to produce any good effects. After the sickness has abated, and during the periods of remission of the symptoms, great benefit is often derived from the use of chalybeates in combination with strychnia or glycerine. Cod-liver oil has not agreed well with any of the patients who have been under my care for Addison's disease; but glycerine, in doses of two drachms, given two or three times a day in conjunction with either the citrate, or the tincture of perchloride, of iron, has seemed to me more effectual than any other medicine for keeping up the general health and strength. Drastic purgatives should in all cases be scrupulously avoided. The bowels are usually more or less constipated; but, unless the constipation be extreme, I think it better to abstain from interference than to risk the dangerous depression which, in this disease, so often follows the administration of even mild aperient medicine.

With respect to diet, no rules can be laid down, except that all the food must be simple and nourishing and easy of digestion, and that it must be given of whatever kind the patient's stomach can best tolerate. This will be found to vary much in different cases, and also at different periods in the same case. When a stronger diet, such as meat or soup, cannot be retained, or digested, milk, either alone or with lime-water, eggs, jelly, oysters, and the like, will often be found to agree. A moderate amount of stimulants, wine or brandy, according to circumstances, seems to be almost always required.

It only remains for me to sum up, in conclusion, the objects I have had in view in the course of Lectures which I have had the honour to deliver before you.

In the first lecture, I believe that I delineated faithfully, all the principal clinical symptoms of Addison's disease and the remarkable varieties in their course, together with the true characters of the pathological lesions, in and around the supra-renal capsules, which have been found to co-exist with those symptoms.

In the second lecture, I endeavoured to show clearly, on the one hand, the concurrent testimony of facts in proof of the real connection subsisting between the clinical symptoms of Addison's disease and the one specific lesion in the supra-renal capsules; and, on the other hand, the baseless nature of the misconceptions which have prevented the general recognition of its reality.

In the third lecture I have trodden on more difficult ground. No one can feel more strongly than myself that the opinions I have been led to form, with respect to the obscure pathological and etiological processes in Addison's disease, rest, as yet, upon an inadequate basis of facts. I can only express the hope, that the suggestions I have ventured to make, regarding the probable mode of production of the symptoms, and the probable means of origin of the supra-renal disease itself, may lead to a thorough investigation, in future cases, of all the facts bearing upon these questions; and thus to the acquisition of knowledge which may, hereafter, justify positive conclusions, in place of the probable inferences, which, on many points, are all that I have been able to draw from my own necessarily limited personal experience, and from the insufficient materials at my command.

APPENDIX A.



CASE I.—*Addison's Disease. Typical Case.*¹

Mrs. W., a married woman, aged 31, by occupation a dress-maker, was admitted a patient of the Western General Dispensary, under the care of Dr. Greenhow, on January 18, 1859. She stated that five years before her present illness she had strained herself in turning a mangle, and believed that something had given way in her right side. For several days after the strain she was laid up with severe pain in the right side, and has never been so robust since as before the accident. Two years ago she began to fail in health more decidedly, but still presented no definite symptoms of illness, did not suffer from any pain, and was able to continue her usual employment. She became worse in September 1858, and her friends observed her becoming dark-coloured, or, as they believed, jaundiced, about October.

On admission she complained of great feebleness, of occasional vertigo, and also of pain in the loins and sickness. The catamenia had been irregular since September, and the patient was remarkably anæmic, the lining membrane of the eyelids, the lips, tongue, and gums being pale and bloodless. The conjunctivæ were clear and of a pearly hue. Pulse under 80 and exceedingly feeble; lungs healthy; skin cool; tongue clean; appetite impaired; heart feeble; urine normal. The patient felt quite unfit for any exertion, and complained of faintness on attempting to move about.

At first sight her complexion had a sallow, swarthy aspect; on closer examination, the whole of the uncovered surface—face,

¹ Case 24, Appendix B.

neck, hands, and arms—had a dusky hue, dashed, as it were, in places with a greenish bronze tint. This greenish colour was produced by a number of small specks or patches of deeper coloured integument, but was not of uniform intensity of hue. It did not altogether pervade, neither was it exclusively limited to, the exposed portions of skin. It was, however, most obvious upon the forehead, temples, back of the neck, and along the course of the trapezius muscles on either side. The discoloration on the body was of a dusky olive hue, and, with the exception of four patches of a darker shade in the dorsal region, did not present any appearance of patchiness. The folds of the axillæ were much darker than the surrounding surface, and several almost black spots, the size of large pins' heads, closely resembling nævi, were situated on the neck, arms, and sides of face. The patches on the dorsal vertebræ and the deeper-coloured integument in the axillæ, though at first sight apparently well-defined, had no definite margins, but faded insensibly into the colour of the adjacent skin. The hair had a dusky appearance, as though it had been dyed, and the patient asserted that it had become much darker within the last three months. There was an ill-defined dark brown line of discoloration running lengthwise along the lower lip near the junction of the skin and mucous membrane, and the buccal mucous membrane on each side was generally of a sallow hue, and was mottled with several light-brown stains.

The patient's state varied somewhat from day to day; sometimes she appeared to improve for a few days at a time; but, on the whole, she became progressively weaker. On February 10 she complained of extreme debility and breathlessness on exertion, of severe pain in the loins, and also of wakefulness at night. She also suffered much from almost constant retching and sickness.

February 17.—Staggers in walking; complains of excessive lassitude and of 'fluttering' of the heart and shortness of breath on exertion. Skin becoming darker; surface cold; pulse scarcely perceptible at the wrist. Says that she experiences a painful smarting in the darker portions of the face and neck when she becomes warm.

March 10.—Is now almost confined to bed; has gradually become darker coloured during the last month; suffers much

from nausea and retching, the matter ejected consisting not of food but of frothy fluid. On being raised up in bed for examination, she was seized with palpitation, præcordial oppression, and excessive faintness.

She now fell into a state of apparent dozing unconsciousness, but remained sensible to the last, although so prostrate as to dislike the effort of rousing herself to speak. During the last days of life a peculiar fetid odour was observed about her person. She died on March 12.

Post-mortem Examination.—Little or no emaciation; mammæ much atrophied; the whole body of a dusky mulatto colour, but the hue was darkest on the abdomen, and next to this on the face, neck, insides of the elbows, and folds of the axillæ. The abdominal parieties contained a layer of fat one inch in thickness, and the thoracic integument a layer half an inch in thickness. Muscular tissue normal in colour and appearance. Several firm adhesions existed between the pleural surfaces; the lungs were congested, but crepitant, and, with the exception of a very few yellow cheesy masses in the apices—the largest of which was the size of a small pea, and the next largest the size of a grain of wheat—were perfectly healthy. The heart weighed five ounces and three quarters, and contained a large fibrinous clot in the right cavities, extending into the pulmonary artery.

The omentum and intestines were very pale; the under surface of the omentum, the peritoneal lining of the diaphragm and abdominal parieties, and the peritoneal covering of the liver, were studded with opaque, yellowish, irregularly stellate-shaped bodies, which could be readily scraped off the serous surface, leaving the subjacent membrane apparently intact, but slightly opaque. The peritoneal coat of the small intestines was slightly roughened by the presence of innumerable small, perfectly transparent granular bodies, closely aggregated upon the serous surface. There was no enlargement of the mesenteric glands, and the peritoneum covering the stomach and large intestines was healthy, as were likewise the kidneys, liver, spleen, and pancreas. The stomach, also, was quite healthy, with the exception of some patches of congestion on the mucous surface of the cardiac portion of the greater curvature.

Both supra-renal capsules were converted into hard yellowish masses; on incision, the left capsule was found to consist entirely

of yellow cheesy matter; the right capsule was in a similar condition, but softened at the centre, from which oozed a few drops of thick creamy fluid when the capsule was divided. There remained no trace either of cortical or medullary substance. (GREENHOW, *Trans. Path. Soc.* vol. x. p. 269.)

CASE II.—*Addison's Disease. Pelvic Abscess.*¹

W. B., aged 24, engineer's labourer, married, was admitted into the Middlesex Hospital under the care of Dr. Greenhow, on April 12, 1864. Patient is a slight man, under middle height, naturally of dark complexion and black hair. Father died of phthisis at the age of 50, and two half-brothers born of the same mother died of the same disease. With the exception of an attack of fever eight years ago, had been always in good health, until between eight and nine months since, when he had an abscess in the left hypochondriac region. The abscess did not prevent him from following his usual occupation. In October 1863, a few weeks after the abscess healed, he was seized with severe pain in the left hip, shooting down the thigh towards the knee, which continued at the time of his admission and rendered him lame. From that time he began to lose strength, and had become very rapidly weaker during the last ten days. Said that he had lately suffered much from sudden attacks of breathlessness and faintness on exertion, and he did actually faint while under examination in the waiting-room. Had for some weeks been affected with loss of appetite, nausea, and occasional retching, with, for the last few days, vomiting of food. Bowels habitually constive; had become more so during his illness. Patient's wife and mother stated that they had first observed his complexion becoming darker at the beginning of the present year.

On admission the patient was so feeble and exhausted that he could scarcely bear to be raised up in bed for examination. Pulse from 90 to 100, small, feeble and compressible; heart's impulse feeble, and sounds exceedingly faint. Skin cool and soft. Tongue flabby, moist, injected at edges, furred on dorsum. Urine copious, rather high-coloured, highly acid, free from albumen, sp. gr. 1022. Skin generally of a dusky brown colour;

¹ Case 136, Appendix B.

face somewhat darker than body; back and sides of neck, from the hair downwards to shoulders, darker than face. Hands much darker than arms; knuckles sensibly darker than the surrounding surface, as are likewise the cicatrices of several superficial injuries. Nails of a clear pale pink hue. Here and there on the neck are a few well-defined dark specks. The skin over the spine for nine inches downwards, from the eighth dorsal vertebra, is much darker than the rest of the back. Over the left hip, where a blister had been applied four months previously, on account of the pain, is an oblong space of skin, nearly four inches by five in size, which is much darker than any other part of the body. It is abruptly defined, its margin apparently corresponding with that of the blistered surface. The skin, at some parts near the edges and centre of the patch, where apparently there has been superficial ulceration, is nearly as black as that of a negro. Nipples and areolæ very dark. The cicatrix of the abscess in the left hypochondrium is about an inch in length by two-thirds of an inch in breadth, puckered, of a dusky colour, and surrounded by a darker coloured ring. Axillæ scarcely darker than surrounding surface, but groins much darker than rest of abdomen; penis and serotum extremely dark. Thighs and legs much paler than trunk. Lips have each a dark, almost black stripe of varying breadth extending along their whole length. The buccal mucous membrane, with the exception of a few intervening paler spots, is also of a dark, almost black colour, and there are several well-defined dark patches on the gums of the lower jaw. The conjunctivæ are clear and perfectly white. The irides are said to have become darker of late, and there is evidently a darker ring of deep blue-black, nearly, but not quite, surrounding each iris, in all but colour closely resembling an *arcus senilis*.

Patient became progressively weaker from day to day; he had frequent retchings, and vomiting recurred after almost every meal; the pulse became quicker and nearly imperceptible; the heart sounds became almost inaudible; the feeling of faintness and extreme exhaustion was constant, and the surface of the body became cold to the touch two days before death, which took place on the afternoon of April 17. Intellect remained unimpaired to the last. During the last hours of life he complained of dimness of sight, and was unable to distinguish persons around his bed.

Post-mortem Examination.—Body spare, but not emaciated. General hue of body dusky, but much less so than it had been during life. Face and neck somewhat darker than the general surface. Skin of the axillæ, and of the left hip on the site of the blister, decidedly darker than the surrounding surfaces. Penis and scrotum much darker than any other parts of the body. Dark stains on lips, and discoloration of buccal mucous membrane remained as during life.

Both lungs were firmly adherent to the ribs. Lung-tissue slightly congested, but free from disease; no trace of tubercle. Heart had much fat upon its outer surface; muscular tissue somewhat pale; right cavities filled with a large, firm, yellow-coloured clot, entangled in the cords of the tricuspid valve, and sending a process into the appendix auriculæ. Many of the mesenteric glands were enlarged, some being of the size of beans; their surface was pale, and on section they appeared of a yellow colour, and had a somewhat dry cheesy texture. Microscopical examination showed them to be infiltrated with a finely granular substance, in which were numerous granular cells and nuclei, and many cells containing oil globules. Blood-vessels of the small intestines much congested. Peyer's patches enlarged, swollen, prominent, of a yellowish white colour, and remarkably opaque. The solitary glands scattered throughout the ileum were also enlarged. Blood normal; muscles of a normal red colour.

Supra-renal Capsules.—Both closely invested with very dense connective-tissue, which contained a good deal of fat. The left capsule measured longitudinally $2\frac{5}{4}$ inches, and transversely $1\frac{1}{4}$ inch. It was of very firm consistence, and on section no distinction was visible between cortical and medullary substance, the whole organ being converted into a mass of firm yellowish-white tissue, in parts semi-transparent. Scattered through this mass were numerous opaque yellow deposits, varying in size from a hemp-seed to a pea, of cheesy consistence, mixed with gritty matter. On microscopical examination, the matter of which these cheesy deposits was composed was found to consist of opaque amorphous granular material, mixed with granular shrunken cells and nuclei, and some oily matter. The intervening portions, in addition to similar granular material, consisted of fibrous tissue. Weight of the organ, six drachms. The right capsule measured longitudinally rather less than 2 inches,

and vertically $1\frac{1}{2}$ inch; in structure it closely resembled the left capsule, but one of the cheesy masses it contained was the size of a small bean. Weight, four drachms. On laying open the pelvic fascia, at the upper edge of the true pelvis, on the left side, about half an ounce of thick, creamy-looking pus escaped. The abscess communicated with carious bone at the left sacro-iliac synchondrosis.—(GREENHOW, *Trans. Path. Soc.*, vol. xv. p. 228.)

CASE III.—*Addison's Disease. Typical Case. Slight Discoloration of Skin.*¹

E. W., a girl, aged $12\frac{3}{4}$, became an out-patient of the Middlesex Hospital, under the care of Dr. Greenhow, on January 20, 1865. She had suffered from bronchitis in the summer of 1864, and had afterwards been sent into the country, where she was much in the open air. On her return home, after an absence of six weeks, her parents remarked that she looked sunburnt. This slight duskiess of complexion—which was limited to the face, neck, and hands—never left her, but she remained without any definite symptoms of illness until a few days before she was brought to the hospital, although her father had considered her as 'drooping' during the three or four previous weeks. On Sunday, January 15, she was sick for the first time, but continued to attend school until Wednesday, 18th, on which day she was again sick, and complained of feeling cold. Her mother then administered a strong cathartic powder, which was followed by copious purging and vomiting, and from that time intense depression supervened.

When brought to the hospital she was suffering from profound asthenia, and had an extremely languid, listless, exhausted aspect, a pallid countenance, and a remarkably small, feeble pulse. Her breathing was frequently interrupted by sighing and yawning, and the slightest attempt at exertion caused her to retch. Her eyes were large and prominent, and the conjunctivæ peculiarly white. The skin was cool, the tongue clean and moist; there was neither cough nor diarrhœa; and, no other disease being discoverable to explain her extremely asthenic condition, the existence of Addison's disease was at once diagnosed. The patient being unwilling to become an inmate of the hospital,

¹ Case 25, Appendix B.

she was attended at home for several days, during which she rallied slightly, the sickness abated, and she was able to take food. On January 22 she began to cough, and expectorated a small quantity of glairy mucus tinged with blood; the vomiting presently returned, and she was admitted into the hospital on January 26.

On admission the dusky hue of the face, neck, and hands, although still by no means very marked, was more evident than it had been in the out-patient room, and a slight duskiness was now also observed on the abdomen and about the knees and axillæ; the nipples also were rather dark. A single dark stain, about the size of a large pin's-head, was found upon the inside of the right cheek, but the amount and character of discoloration altogether was not sufficient to have justified the diagnosis of Addison's disease made from the constitutional symptoms. There was slight dulness on percussion, and bronchial breathing below both clavicles; but the patient had scarcely any cough and no expectoration after her admission into the hospital. The asthenia, however, increased; she always vomited soon after taking food, and retching, faintness, and failure of the pulse came on whenever she was moved. She scarcely slept at all in the hospital, became very restless on the 27th, and died rather suddenly on the evening of January 28, retaining her consciousness to the last.

Post-mortem Examination.—Mammæ undeveloped. Hair dark brown; complexion of face uniformly dusky. The neck was darker than the face, and presented a great contrast to the colour of the chest, which was natural. The mammary areolæ were slightly dark; the axillæ, abdomen, thighs, and knees dusky, but the legs and feet of natural colour. There were no dark moles nor other definite patches of discoloration; and save that the chest, feet, and legs were fair, the physical aspect of the body was that of a person with a naturally dark skin. There was a moderate amount of fat underneath the skin of the thorax and abdomen; the muscles were firm and of a normal red colour. There were firm fibrous adhesions at the apices of both lungs, and some small patches of pigmentation on the surfaces of the lungs. The apices of both lungs were puckered on the surface, and consolidated by the deposition of tubercle, chiefly of the grey semi-transparent kind; there were no cavities, but the

tubercle was beginning to soften at one or two points in the right lung. There were also two or three small masses of grey tubercle in the lower portions of both lungs. Nearly colourless clots of moderately firm consistence were found in all the cavities of the heart, adhering to the muscoli pectinati and chordæ tendineæ, and extending into the great vessels. In the stomach, near the pylorus, were a few small reddish patches of congestion, the rest of the mucous membrane being pale and normal, as was also that of the upper part of the intestines. In the lower part of the ileum Peyer's patches were more than usually prominent, and the mucous membrane was somewhat congested; the solitary glands were enlarged, and here and there one was opaque and slightly yellow. The mesenteric glands were enlarged, but in other respects appeared to be normal. The kidneys were somewhat hyperæmic.

The supra-renal capsules were both much enlarged. The fibrous envelope of the right capsule was much thickened and firmly adherent to the kidney, liver, and diaphragm. The organ itself was hard and somewhat nodulated, and when cut across no trace of the normal structure was visible, nor any distinction between cortex and medulla. It was chiefly made up of masses of opaque yellow matter, partly of cheesy consistence and partly friable, with here and there some gritty matter; in addition to these, and in part separating them, was a greyish semi-transparent tissue of tough consistence. In the upper part of the organ, beneath the thickened fibrous envelope, was a collection of puriform fluid.

The left supra-renal capsule also had its fibrous envelope thickened and adherent to the kidney and diaphragm. It was somewhat softer than the right one, but, like it, was nodulated. On section it showed no distinction of cortex and medulla, nor any trace of normal structure, but was composed of opaque yellow deposits, resembling those of the right capsule, but of smaller size, and separated from each other by greyish transparent tissue, which was more abundant in the left than in the right capsule.

The left supra-renal capsule was submitted to Dr. Burdon Sanderson for microscopical examination, who favoured me with the following report:—

‘The capsule, which is still attached to the kidney, is of the

size and shape of a walnut. It is closely invested with a covering of dense fibrous tissue, about half an inch in thickness, which is in some parts separable from the external surface of the organ, in others firmly adherent to, and, as it were, incorporated with it.

'In the section of the organ no distinction can be made out between rind and kernel; but it exhibits several varieties of structure and consistence, without definite arrangement. Some parts are of a pinkish colour, somewhat translucent, and of firm consistence; others are white, soft, of a consistence approaching to cream-cheese, and occasionally gritty. Between these there are various gradations; thus, in many parts the tissue has lost its translucency and colour, but not its consistence. Between the translucent parts and the opaque parts there is a great difference in structure, as shown under the microscope. The former exhibit (even without the addition of acetic acid, and much more distinctly after the addition of that reagent) nuclei which are embedded in a finely granular stroma (Plate IV. fig. 1). The granular appearance is owing partly to albuminous granules (which disappear with acetic acid), partly to fat granules. These nuclei are usually round or oval; but in some parts they are elongated, in a definite direction, into spindle-shaped bodies or nuclear fibres, as shown in the accompanying sketch (Plate IV. figs. 2 and 3). The opaque portions exhibit no nuclei nor cell structures, either with or without acetic acid. They exhibit, in fact, only albuminous, fatty granules, the latter being more abundant in proportion to the advance of the process of softening. It is tolerably evident that the change consists (1) in the development in the organ of the firm tissue, of which the structure is above described, viz. an albuminous exudation undergoing gradual transformation into fibrous tissue, and (2) in the fatty degeneration of this substance.'—(GREENHOW, *Trans. Path. Soc.*, vol. xvi. p. 247.)

CASE IV.—*Addison's Disease. Tubercle of Lungs and Abdomen.*¹

M. D., aged 55, labourer, was admitted into the Middlesex Hospital, under the care of Dr. H. Thompson, on Feb. 6, 1866.

He had had syphilis early in life, followed by buboes in either groin. Twice also he had had severe falls. He was strong and

¹ Case 139. Appendix B.

hearty until about three months previous to his admission into the hospital, but could not fix any precise date for the commencement of his illness. He first of all became weak and unable to work, was breathless on exertion, had nausea and pain in the epigastrium, and frequently vomited after taking food. The debility progressed rapidly, so that by Christmas he was obliged even to give up taking a short walk in front of his house.

On admission, his skin was of a dusky-brown hue, which was most obvious on the face, but more or less pervaded the whole body. The penis and scrotum were almost black; as were likewise the cicatrices of some burns received in early life upon the left arm and the inner aspect of the right elbow. This latter discoloration, however, was limited to the less deeply injured parts, and inside the left elbow in the midst of the dark surface was a well-defined, glistening, perfectly white cicatrix, where the burn had destroyed the deeper layers of the skin. There were several cicatrices on the back, of which the more superficial were discolored, while the deeper ones remained of normal hue. The cicatrices of the buboes in both groins were stained dark brown. On the upper surface of the tongue, near its border, were several bluish-black stains, with well-defined margins; the lips and buccal mucous membrane also presented distinct brown stains. The pulse was 60, very small and compressible, and varied little while he was under observation. The heart-sounds were faint, but free from murmur. The percussion resonance was slightly deficient over the upper and anterior part of the chest, especially below the right clavicle; the respiration was feeble, and accompanied by slight rhonchus and sibilus, and a few moist sounds; but there was nothing to indicate active pulmonary disease.

Whilst in the hospital the patient suffered much from retching and vomiting, and complained of pain in the loins and epigastrium, frequently accompanied by tenderness on pressure over the latter region. He often had cramps in the muscles of the abdomen and legs, especially when he retched, and he found it easier to lie with the knees drawn up, the cramps becoming more troublesome when his legs were stretched out. A few days after his admission the matter vomited became of a greenish colour and bitter taste. On Feb. 14 a faint systolic murmur was heard at the apex of the heart, and the pulse fell to 52 and became extraordinarily weak; but a day or two later, it rose again to 60.

On the 19th he was so weak that he fell down when he attempted to rise out of bed, and on that day the matter vomited consisted of mucus streaked with blood. He now slept badly, and by the 22nd had quite lost his appetite; the retching continued, and there was a distinct cadaverous odour about his person. On this day there was marked dulness on percussion over the upper part of the chest posteriorly; rhonchus and sibilus were heard all over the back of the thorax, and fine crepitation was audible below the left clavicle. He had raised some thick dark green sputa, several of them tinged with blood, and he complained of sharp pain in the region of the diaphragm on the right side. From this time he gradually sank and died on March 2, death being preceded by retention of urine, great restlessness, wandering of mind, and groaning.

Post-mortem Examination.—The lungs on both sides were firmly attached to the ribs by old fibrous adhesions; they were very dark coloured, and in the upper lobes of both were several deposits of yellow cheesy matter, around which the pulmonary tissue was consolidated and intersected by fibrous bands; there were no recent tubercles, and elsewhere the lungs were crepitant. There had been recent pericarditis; the pericardium contained an ounce of turbid fluid, and patches of granular lymph were scattered over the heart. The right cavities of the heart were filled with firm, yellow, semi-transparent clots of fibrine, adherent to the muscliculi pectinati and chordæ tendineæ, and extending into the pulmonary artery as far as the second division. The left ventricle also contained a clot, which passed for a short distance into the aorta.

The great omentum turned up over the liver, and was firmly attached to the under surface of the diaphragm; there were also fibrous adhesions between the gall-bladder and small intestine. The under surface of the diaphragm was thickly studded with greyish-yellow, semi-transparent, tubercular granules; and scattered over the mesentery and on the peritoneum, in front of the spine, were likewise several patches of similar granules, each surrounded by a deposit of black pigment. There were no traces of recent peritonitis. The mucous membrane of the stomach was somewhat congested. The surfaces of the kidneys were slightly granular.

Supra-renal Capsules.—The right supra-renal capsule was

much enlarged, and weighed one ounce and a half; its fibrous envelope was considerably thickened, firmly adherent to the organ itself, and attached by fibrous bands to the diaphragm. It was nodulated, and on section no distinction appeared between cortex and medulla. The greater part of the organ was converted into an opaque substance of the consistence of soft cheese, in some parts of a pale yellow, in others of an orange colour. Near the anterior end, and extending inwards from the hilus, was an irregularly shaped, semi-transparent, grey-coloured patch, which sent off prolongations partially separating the yellow cheesy substance into circular masses. This semi-transparent portion was itself studded with opaque yellow nodules. At one point in the yellow substance was a small cavity filled with puriform fluid. The left supra-renal capsule weighed about half-an-ounce; its envelope was much thickened, but did not adhere to the surrounding parts; its surface was much nodulated. On section, there appeared no distinction between cortex and medulla, the organ consisting of irregular roundish opaque masses of a yellow colour, separated by semi-transparent, grey, fibrous tissue. These masses were of a crumbling consistence, and in many places broken down into puriform fluid and granular detritus. Portions here and there were less opaque, and of an orange colour similar to that found in parts of the right supra-renal capsule.

Microscopical Examination.—Thin sections of various portions of the right supra-renal capsule were submitted to careful microscopical examination by Dr. Cayley, who kindly furnished me with the following report:—

‘The grey semi-transparent substance presented tracts of connective-tissue, with numerous fibre-cells and nuclei, interspersed with masses composed almost entirely of nuclei, and of irregular roundish cells, about the size of white blood-corpuscles, and distinctly nucleated; these were mixed up with little irregular roundish or oval corpuscles and much granular matter. Portions from the yellow substance presented, in parts, the tubular spaces of the cortex filled with cells containing much yellow pigment and oil; these, in many cases, formed islands, surrounded by tracts of connective-tissue. In other parts were tracts of opaque, oily, and granular matter, which sometimes showed indications of filling the tubular spaces, and sometimes appeared disseminated

without any structural arrangement. The fluid from the cavity consisted almost entirely of oil and granular débris, and did not appear to be true pus. The characters of the left capsule were very similar, but the tubular structure was much more obscured.

'Microscopical examination of slices from the discoloured patches on the tongue showed deposits of pigment in the form of irregular brown masses deposited in the papillæ, the superficial layers of epithelium covering them being quite free from colouring matter.'—(GREENHOW, *Trans. Path. Soc.* vol. xvii. p. 304.)

CASE V.—*Addison's Disease. Injury to Vertebrae. Lumbar Abscess.*¹

C. S., aged 32, coal-porter, was admitted into the Middlesex Hospital, under the care of Dr. Stewart, on Feb. 13, 1866.

He stated at first that his health had been good until about eight or nine months previous to his presenting himself at the hospital for admission. Upon enquiry, however, it was subsequently elicited, that, somewhat more than three years before, he had sprained his back severely in pushing a loaded coal-truck, and had experienced at the same time a sensation of something giving way in the spine. He had ever since suffered more or less constantly from pain in the region of the lower dorsal vertebrae, for the relief of which he had tried various remedies, including blisters. Eight or nine months before his admission he had begun to suffer from debility, sweating, headache, loss of appetite, and sickness, with breathlessness on exertion, followed by severe pain in the right lumbar region. Four or five months later his wife had observed a change of colour in his skin, which she thought had appeared first upon the face and hands, and which gradually deepened, and spread over the whole body. He had been compelled to give up work for about two months.

On admission, his skin was of a general olive-brown hue, especially on the face and neck. On the face were several almost black specks; there was a stain on the right side of the tongue, and the lips and buccal mucous membrane were mottled with brown. The upper part of the chest and the legs were lighter in colour than the rest of the body; the abdomen was darker than any part except the sites of blisters, which had been applied over the right flank and lumbar vertebrae some months previously.

¹ Case 138, Appendix B.

The nipples and areolæ, and the penis and scrotum, were very dark; the hands, and especially the knuckles, were much darker than the arms. The hair and beard were said to have become visibly darker during his illness. The white pearly hue of the conjunctivæ contrasted strongly with the dusky colour of the skin. The pulse was exceedingly feeble; he was breathless on the slightest exertion; had frequent retching and vomiting after food, and complained much of pain in the epigastrium. He was exceedingly weak, and had such a sense of stiffness and weakness in the back that when he sat down he felt almost unable to rise again; in fact, he said that his back felt broken. There was tenderness on pressure, and well-marked pain on percussion over the lower dorsal and upper lumbar vertebræ, and he complained of a sense of tightness round the abdomen, from the flanks to the groins, and of pain and difficulty in stretching out the legs, when lying on his back with his knees raised. The percussion resonance was somewhat deficient over the front of the thorax, especially below the right clavicle, and the respiration, which was everywhere a little harsh, was distinctly tubular in the apex of the right lung; but no moist sounds, nor other evidences of active pulmonary disease, were at any time discoverable.

From the time of his admission he very slowly, but steadily, declined. The retching and vomiting continued with brief intermissions. He suffered from vertigo when raised up in bed, became somewhat deaf and dim-sighted, and some days before death fell into a drowsy semi-comatose state, though still perfectly able to answer questions when roused. He died on March 28.

Post-mortem Examination.—Body moderately nourished; colour much as during life. Both lungs were firmly attached by old adhesions to the ribs, and at the base of the right side of the thorax a cyst the size of a walnut, filled with putty-like matter, was found in the adhesions, which contained also in several places calcareous deposits. In the apex of each lung was a dense solid mass, consisting chiefly of fibrous tissue, apparently the cicatrix of a former cavity. Embedded in these masses of consolidated lung were several opaque yellow nodules, partly cheesy and partly calcareous. The lungs were elsewhere crepitant, but dark-coloured and emphysematous around their free borders. The pericardium contained about an ounce of yellow serum, and

presented other traces of slight recent pericarditis. The heart was small and flabby, but its muscular tissue was normal. The right auricle and ventricle were filled by a large partially decolorized fibrinous clot. The left cavities contained a little fluid blood.

The right supra-renal capsule was much enlarged, and embedded in thick fibrous tissue, which was firmly adherent to the vena cava and diaphragm. The exterior was nodulated, and on section all distinction between cortex and medulla was lost. The surface of the section presented an intermixture of a greyish, semi-transparent, somewhat fibrous tissue, and of opaque, yellow roundish masses of cheesy consistence, some of which showed little calcareous patches. The left capsule was much smaller than the right; was likewise embedded in thick fibrous tissue and adherent to the diaphragm, and indeed closely resembled its fellow in all respects, except that it contained a larger proportion of crumbling calcareous matter.

The other abdominal organs were healthy, excepting that the kidneys were much congested and that the mucous membrane of the duodenum was studded with minute patches of injection.

Extending in front of the vertebræ, from the seventh dorsal to the third lumbar vertebra, was an abscess confined by fibrous investments, containing about two ounces of somewhat curdy pus. The bodies of the vertebræ covered by the abscess were bare and somewhat rough. The intervertebral substance between the last dorsal and first lumbar vertebra was separated, on the left side, from the upper surface of the latter vertebra for two-thirds of its depth, but the separation did not extend to the spinal canal. The upper surface of this vertebra was bare and rough, but the bone within seemed to be quite healthy. The spinal canal and cord were normal.

Dr. Cayley dissected out and compared the nerves of the diseased capsules with those of healthy capsules from two other bodies, and found that the nerves passing to the diseased organs from the semi-lunar ganglion, and especially a branch of the great splanchnic, were at least twice the size of the corresponding nerves of the healthy organs. On microscopical examination of these enlarged nerves, after they had been for some time in spirit, the only difference discoverable was an increase in the fibrous investment of the nerve-bundles.

Under the microscope, the greyish semi-transparent substance of the diseased capsules presented a fibrous basis, which was more or less obscured by dark granular matter, with irregular shrunken cells and nuclei. The opaque yellow portions consisted in parts of granular and oily débris, and in parts presented the tubular spaces of the cortex filled with dark oily and granular matter.

Sections of skin from the right flank, where a blister had been applied, were also examined under the microscope. The deepest layers of the epidermis were found to be of a rich, dark-brown colour, from the deposit of pigment in the form of little granular masses in the epidermic cells. The upper layers became gradually less coloured, until quite at the surface the colour was altogether absent. In some places similar pigment-granules were found in the true cutis, immediately below the epidermis. (Plate II, fig. 3). (GREENHOW, *Trans. Path. Soc.*, vol. xvii. p. 307.)

CASE VI.—*Addison's Disease. Typical Case.*¹

J. D., aged 43, park-keeper, became an out-patient at the Middlesex Hospital, under the care of Dr. Greenhow, on November 17, 1865. About seven years before, the patient had suffered from repeated attacks of ague, extending over a period of three years; but, with this exception, his health had been good until within a few months of his coming under observation. During this latter period he had suffered much from pain in the loins, especially on the right side, and also from pain in the epigastrium and left hypochondrium. He also complained of giddiness, loss of appetite, retching and vomiting.

On admission he had a strikingly languid, exhausted aspect; his pulse was extremely feeble; he was short of breath on exertion, and was obviously exceedingly ill. The area of splenic dulness was somewhat larger than natural. The urine was perfectly normal, and there was no emaciation, nor any apparent cause to account for the extreme asthenia from which he was suffering. He had, indeed, a troublesome catarrhal cough; but this had only recently supervened, and there was no physical evidence of any pulmonary disease.

¹ Case 27, Appendix B.

On examination of the surface of the body, the face, back of neck, hands and fore-arms, were found to be slightly dusky. The site of a small blister, which had been applied over the epigastrium three months previously, was deeply discoloured; and on the skin covering the left clavicle there was a yellowish-brown stain about an inch in length, evidently corresponding to the cicatrix of some slight wound. With these exceptions the skin was fair and free from discoloration; but the buccal mucous membrane presented several brown stains in places which had apparently been irritated by the teeth. The hair was of a sandy colour, and the beard and whiskers light brown.

The patient resided in Camden Town, and continued under observation for nearly two years. During this period he had several attacks of excessive prostration, accompanied by sickness and by pain in the epigastrium and left hypochondrium, with gasping, sighing respiration. These attacks were often referable to some definite over-exertion, but sometimes occurred without any discernible cause. During the intervals of improvement he usually walked to the hospital, a distance of three miles, once a week. Repeated examination throughout his illness failed to detect any pulmonary disease beyond slight and transient attacks of bronchitis. The heart's impulse was always very feeble, but the sounds remained perfectly clear.

He began obviously to sink in September 1867, and was then admitted into the hospital, where he died on the 17th of the same month. During the interval which had elapsed, between his first presenting himself at the hospital and his final admission as an in-door patient, the discoloration of skin had become much more marked, his hair had acquired a dark-brown hue, and his whiskers had become black. The stain in the cicatrix over the clavicle had also become deeper; but that over the site of the blister had gradually faded, and could scarcely be distinguished at the time of death. Meantime a streak of discoloration had appeared on either lip, as well as some dark patches on the gums, and two distinct inky-looking stains on the tongue. Many small specks like black freckles had also made their appearance on the face, neck, hands, and trunk.

The patient became delirious the night before his death, which was preceded by several days of uncontrollable vomiting. During the last few hours of life he lay apparently unconscious, with

his thighs drawn up, his arms crossed over his chest, and his fists clenched. Both the upper and lower limbs strongly resisted extension. The abdominal muscles were rigid, as were also the masseters, and the mouth was firmly closed. Whenever he was touched convulsive twitchings ensued, either of the face only, or of the whole body.

Post-mortem Examination.—A considerable layer of yellow fat was found in the abdominal parieties. The muscles were well nourished and of a healthy red colour. The brain was slightly congested, and its substance rather soft. The lungs were everywhere adherent to the ribs and somewhat congested, but free from tubercle. The only other signs of disease in those organs were some dilated and thickened bronchial tubes in the upper lobes, containing puriform and putty-like matter. The heart weighed $7\frac{1}{2}$ ounces, and its muscular tissue was rather pale-coloured. Both the mitral and tricuspid valves were much thickened at their edges; the chordæ tendineæ were also much thicker than usual. The aortic and pulmonary valves were normal. The liver was small, but healthy. The spleen was large, weighing $10\frac{1}{2}$ ounces, but in no other respect abnormal. The kidneys were perfectly healthy, but slightly congested. The dorsal and lumbar vertebræ were carefully examined, and were found to be quite free from disease.

The supra-renal capsules were of about their normal size and shape, but slightly thickened. They were hard and nodulated, and on section were seen to have wholly lost their normal appearance; the natural tissue being replaced by an almost calcareous yellow substance, embedded in a yellowish-white semi-transparent matrix. Sections of the capsules examined under the microscope presented the usual appearances characteristic of Addison's disease. (GREENHOW, *Trans. Path. Soc.*, vol. xix. p. 404.)

CASE VII.—*Addison's Disease. Angular Curvature of Spine.
Lumbar Abscess.*¹

Alfred H., aged 25 years, by occupation a carpenter, presented himself at the Middlesex Hospital on October 17, 1872; but, declining to enter the wards, was kept under observation as an out-patient until February 28, 1873, when he was admitted into Founder Ward, under the care of Dr. Greenhow. The

¹ Case 137. Appendix B.

patient came of a phthisical family, and had never himself been robust. He had always been more or less subject to cough, and had latterly been a free drinker of gin and beer. In the autumn of 1871 he began to suffer from pains in the lumbar region, which never left him, but continued to increase in severity until October 1872. He imagined that the pain had arisen from his taking cold, and had no recollection of having ever received any blow, or strain, or other injury in the loins.

On admission, the patient was thin and emaciated. The whole surface of the body, excepting the legs, had a dusky sepia-coloured hue; the brown colour of the face contrasting very markedly with the whiteness of the conjunctivæ. The flexures of the axillæ, knuckles and thighs, and the entire surface of the abdomen, were of a somewhat darker tint than the rest of the body; the areolæ of the nipples and the skin of the nates were almost black; but there were several white patches upon the scrotum. The mammæ were much atrophied. Upon the arms, chest and shoulders, were numerous dark stains, apparently in the sites of former eruption, and also here and there small black, or dark purple, specks resembling moles. Upon the arms were likewise several cicatrices of former injuries, each presenting an areola of pigment around the white central cicatrix, and also several small white leuco-dermic spots. Upon the lips were several patches of brown discoloration, and the buccal mucous membrane was mottled with similar spots; there was likewise a brown patch upon the left arch of the fauces, and there were two pale inky stains upon the border of the tongue.

There was slight flattening below both clavicles, and the percussion note was impaired in both infra-clavicular regions, especially the right. The breath-sounds in the same regions were harsh and dry, and expiration was prolonged. No crepitating nor other adventitious sounds were audible; the heart sounds were normal. There was angular curvature forwards of the dorsal vertebræ, but no pain was produced either by pressure or percussion over them. There was, however, slight tenderness on pressure over the flanks. The walls of the abdomen were rigid, and resisted pressure made on the hypochondria. Pulse 84, very small and feeble. Temperature 100·8°. Urine, sp. gr. 1013, acid, not albuminous.

Whilst in the hospital the patient complained only of great

pain in the loins and of weakness. His appetite was much impaired and very capricious, and he suffered from frequent retching and vomiting, sometimes after taking food, but sometimes also independently of having eaten. His bowels were habitually torpid. His aspect was listless, and his speech usually slow and monosyllabic, as though talking were a great trouble to him. He did not complain of breathlessness, either before admission, or whilst in the hospital, but during the latter period he remained continually in bed. For many days before his death he lay in a prostrate, semi-comatose state, as if unaware of what was going on around him; but he often sighed and groaned, and, although laid on a water-bed, he required to have his position frequently altered on account of pain in the loins. During the last few days of his life subsultus was observed, but his intellect was unimpaired to the last. He died on March 26, at 9 o'clock P.M.

Post-mortem Examination.—Body emaciated. Integuments everywhere of a dusky-brown hue, deepest in the loins, axillæ, and groins. The areolæ around the nipples and the scrotum were nearly black. On the scrotum were a few irregular patches, perfectly devoid of pigmentation. The brain was healthy. The right lung was bound down by old adhesions over the upper lobe. At the apex the pleura was thickened and puckered over the seat of a calcareous nodule, about the size of a hazel-nut, which was embedded in indurated lung-tissue. Several similar, but much smaller, nodules, situated immediately beneath the pleura, were scattered through the upper lobe. The left lung was also adherent at the apex, where fibroid induration and calcareous nodules similar to those found in the right lung likewise existed. The heart was small, its substance flabby and mottled, the fibres showing fatty granules under the microscope. The right cavities were filled with partly decolorised adherent clot; the left cavities also contained a smaller clot. The valves were healthy.

Abdomen.—After the liver and intestines had been removed, the semi-lunar ganglia and nerve plexuses were dissected out. Nothing abnormal could be seen in the nervous ganglia by the naked eye. The mesenteric and retro-perineal glands were all enlarged, somewhat firm and white on section.

Supra-renal Capsules.—The right capsule was slightly enlarged, firm, and nodulated on its surface. On section no distinction was apparent between cortex and medulla, but the whole sub-

stance was replaced by a new growth, in the form of tracts of semi-translucent substance of a slightly greenish tint and of firm semi-cartilaginous consistence. The largest of these tracts occupied fully one-third of the organ, and presented in its centre a perfectly white opaque calcareous nodule. A smaller mass of the same material was found near the lower border of the organ. The rest of the cut surface presented a coarsely granular appearance, from the section of firm translucent grey-coloured nodules, varying in size from a millet-seed upwards, and separated from one another by tracts of fibrous tissue continuous with the firm fibrous investment of the organ. The left supra-renal capsule was nearly twice the size of the right capsule, and presented a similar hard nodular surface.

Stomach.—The mucous membrane at the fundus was speckled with minute sub-mucous ecchymoses. Throughout the stomach the surface of the mucous membrane was mammillated, the mammillary elevations being most marked and most numerous towards the pylorus. The small intestines presented considerable enlargement of the solitary and agminated glands throughout the whole extent of the canal. The solitary glands were most enlarged at the lower end of the ileum, and appeared as bead-like processes studding the mucous membrane. Peyer's glands were prominent, their component follicles appearing as black dots on the surface of the patch. The largest patch was situated just above the ilio-cæcal valve, and measured $2\frac{1}{4}$ inches in length by $1\frac{3}{8}$ inches in width. The large intestines also presented slight glandular enlargements.

Vertebral Column.—After the removal of the abdominal viscera a large abscess of an oval shape, 4 inches in length, with thickened walls, was found on the left side of the lumbar vertebræ. It was contained within the sheath of the psoas muscle near its origin, and contained a large quantity of inodorus pus, in which floated flakes of cheesy matter. The sac of the abscess could be traced upwards to a level with the twelfth rib, but downwards it did not extend to the brim of the pelvis, the psoas muscle at its lower end being quite healthy. In front of the spine, across the bodies of the first and second lumbar vertebræ, the abscess was continuous, with a smaller sac situated on the right of the spinal column. The bodies of these two vertebræ were roughened and carious.

I am indebted to Dr. Sidney Coupland, Pathologist to the Middlesex Hospital, for the following report of the microscopical appearances :

‘*Supra-renal Capsules.*—Sections of the right organ showed the following appearances :

‘1. The large translucent semi-cartilaginous tract consisted of a perfectly homogeneous or very finely granular substance, quite structureless, and containing in its most central part a tract of calcareous granules and molecules, which could be dissolved out by dilute acetic acid, leaving behind, as a basis, the same material that formed the major part of the organ. Investing the mass was a layer of fibrous tissue, arranged in bundles, with small round cells between.

‘2. The nodulated portions exhibited here and there isolated masses of the characteristic large nucleated granular cells from the cell-columns of the gland ; but the gland-tissue was almost entirely replaced or destroyed by the new growth, which appeared as an infiltration of small round cells and tracts of fibrous tissue. Sections that had been shaken up in water to liberate the cell-elements showed that these, even where most thickly aggregated, were all contained in a delicate stroma, which formed a fine reticulum, in the meshes of which one, two, or more cells were contained. The cells were of the size and appearance of leucocytes stained deeply with carmine or logwood, were nucleated, and although mostly contained within the meshes of the reticulum, some were found in its substance at the point of junction of some of its fibres. In histological characters this new tissue was the counterpart of so-called adenoid or lymphoid tissue. It was freely traversed by capillaries, to the walls of which the reticulum appeared to be attached. Lastly, here and there occurred irregular granular protoplasmic masses, which in some instances contained several of the small round cells, and in others appeared quite destitute of them, sending prolongations to join the reticulum ; in fact, answering in every particular to the “giant-cell,” believed by Schüppel to be distinctive of tubercle. (Plate IV. fig. 4.) In other parts of the same section the cellular elements were much less numerous, but the reticulum had become proportionately thicker (Plate IV. fig. 5), whilst, in the more fibrous parts, more or less parallel bundles of fibres

freely interlaced, the round cells existing only between the meshes thus formed. (Plate IV. fig. 6.) In these more organised parts the blood-vessels were much thickened. The precise relations between this new growth and the original cell-elements of the organ could not be fully determined. Most of the sections showed the characteristic, large, nucleated, granular, and pigmented cells of the cortex occurring in the midst of the reticular tissue, either completely isolated or else in groups of three or four, occasionally in linear series. Other sections showed larger and more compact groups of these cells, surrounded by a zone of fibrous tissue, more or less infiltrated by the small round cells or nuclei. From this latter disposition the transition was easy to some small nodules, caseous and amorphous in the centre, with a coarse, fibrous network around the margins, the outer portions of which were closely crowded with small cells or nuclei. The resemblance of these nodules to miliary tubercle softening in the centre was very striking; here, however, the caseous material apparently arose from the death of the normal cell-elements.

‘*Skin.*—The cells in the deeper layers of the epidermis contained brown pigment-granules, those immediately above the corium being most pigmented. Pigment-granules, isolated and in groups, occurred also in the connective tissue of the dermis, at some distance from the epidemic layer. Sections of the pigmented patches on the tongue showed, under the microscope, that the colouring matter was deposited in the lower cells of the papillæ, the sub-epithelial connective tissue being quite free from pigment.

‘*Stomach.*—Vertical sections were made through the wall of the mammillated portion of the organ after hardening in spirit.

‘From these it would appear that the mammillation was due to enormous overgrowth of lymphoid tissue around and between the gastric tubules; here and there the tubules were displaced by what appeared to be an enlarged follicular gland, the central portion of which had begun to disintegrate, and here the mucous membrane was swollen—but the small cell infiltration extended throughout the whole mucosa.

‘*Small Intestine.*—Sections of the enlarged Peyer’s patches showed nothing abnormal.

‘*Mesenteric glands* also apparently normal.

‘*Semi-lunar ganglion* was examined after hardening in spirit. The oval and pyriform ganglion-cells, which contained a good

deal of pigment, were mostly separated from one another by wide intervals, which were occupied apparently by bundles of nerve fibres, their oval nuclei staining deeply with earmine; but there was no evidence of interstitial inflammatory growth.' (GREENHOW, *Trans. Path. Soc.*, vol. xxiv. p. 224.)

CASE VIII.—*Addison's Disease: Angular Curvature of Spine; Obsolete Lumbar Abscess.*¹

Mary S., aged 16 years, was admitted into the Middlesex Hospital under the care of Dr. Greenhow, on April 14, 1875. She had been attending at the hospital as an out-patient under the care of Dr. Cayley for some time with phthisis, and latterly with great weakness and occasional vomiting. She had also been subject for some time to diarrhœa. Her mother died four years ago of phthisis.

On admission the patient was found to be much stunted, thin, and ill-developed. Her hair was chestnut-brown, and her eyes were of a grey-brown colour. The whole surface was extremely dark, more particularly the trunk, the abdomen being darker than the face. The skin was of a sepia colour, and had, her father stated, been getting darker lately; but the girl herself said that she had always been very dark. There was a distinct line of pigmentation on the lower lip, and there were also some dark patches on the inside of the right cheek. There were the scars of several small burns upon the body, which remained white and uncoloured, neither were they surrounded by any areolæ of discoloration deeper than that of the surrounding surface. On the left side of the face were three small black specks, each about the size of a large pin's head; they were well-defined, and closely resembled moles, but had only recently made their appearance. The mammæ were atrophied, and the nipples were slightly darker than the adjoining skin. The patient's chest was much distorted, by reason of an extreme angular curvature of the vertebral column in the dorsal region. There was below the right clavicle marked impairment of percussion resonance, and on auscultation dry creaking sounds were heard, together with bronchophony. There was no tenderness on pressure, or percussion, over the spine, but pain was produced by pressure in the hypochondria. Pulse 95, very thready and feeble. Temperature

¹ This case has not hitherto been published.

98.4°. Urine, sp. gr. 1018, acid, not albuminous. In the evening the pulse rose to 108, and the temperature fell to 98°.

April 15.—Patient passed a comfortable night, and was seemingly well at 6 A.M. At 7.30 the nurse observed her to be sleeping heavily, and foaming slightly at the mouth. Mr. Lendon, the Resident Physician's assistant, then found her quite unconscious, the conjunctivæ insensible when touched, pupils contracted, equal, and immovable under the influence of light; arms and legs rigid and flexed. Pulse 90. Respiration 30. Temperature 98°. She was making efforts to vomit, and occasionally ejected a frothy fluid from the mouth. She remained unconscious, and died rather suddenly at noon.

Post-mortem examination made by Dr. Coupland 20 hours after death. Marked post-mortem rigidity. Extreme emaciation. Angular curvature of spine in lower dorsal region, with lateral curve in upper dorsal. Convexity towards right side.

Whole surface of the body more or less of a bronzed tint; the pigmentation was most marked on the abdomen, groins, and thighs, passing abruptly into a pale brown tint below the knees; streaks of darker brown at roots of toe-nails. On the upper half of the body the bronzing was most marked in the axillæ, where it was of a dusky bistre hue, and at the back of the shoulders; it was less marked on the thorax, and least on the face and arms. The dorsal surfaces of the fingers over the joints were of a darker colour than the rest of the hands, and a zone of deeper pigmentation bordered the roots of the nails. There were three well-defined vaccination marks on the right arm, without any excess of pigment around them.

The brain and its membranes were natural; the pituitary body was of the size of a pea. The thyroid gland was well developed and of unusually firm consistence; it weighed an ounce and a half. The thymus was also well developed, and weighed half an ounce.

The right lung was everywhere adherent to the chest wall; most firmly over the lower lobe. The upper lobe of the lung was fairly healthy, the middle lobe, adherent to its neighbours, was also natural. The lower lobe was invested by a layer of thickened pleura, and was wholly occupied by a large irregular cavity into which the bronchi opened freely on all sides; its walls were formed of dense pigmented fibrous tissue. The left lung was

bound to the walls of the chest by a single fibrous adhesion, but was in other respects quite healthy. The bronchial glands were pigmented.

The heart was healthy; its right cavities contained a firm semi-decolorised clot.

Abdomen.—Some adhesions existed between the liver, spleen, and diaphragmatic peritonæum.

The stomach was nearly empty; its mucous membrane was coated with a thin layer of mucus, on removal of which the following appearances were shown. At the cardiac extremity there was considerable vascular injection at the point of termination of the œsophageal epithelium; just below that point were a number of minute elevations or granulations, most abundant on the smaller curvature; there were also several minute sharply-cut ulcers, apparently formed by the breaking down of the white granulations. In the neighbourhood of the pylorus the mucous membrane was markedly mammillated, the mammillation being due to small rounded elevations of the mucous membrane, varying in size from a millet-seed downwards; they were very closely aggregated, and extended along the lesser curvature for about one-third of the distance between the pylorus and cardia; many of these elevations were opaque and white, and several were surrounded by minute circular pits of the size of pin-holes. This mammillation presented a most striking appearance. Other small opaque white dots, scarcely elevated above the surface, extended beneath the mucous membrane of the lesser curvature in linear rows as far as the cardiac orifice, while here and there a few similar opacities were to be seen on the general mucous membrane of the body and fundus. The mucous membrane of the small intestine for its whole extent, from the pylorus to the ileo-cæcal valve, was studded by small pellucid spheroidal bodies like sago grains, probably enlarged solitary glands. In the duodenum and jejunum they were very numerous between and upon the valvulæ conniventes, diminishing in number at the upper part of the ileum, but increasing in its lower half, and becoming very thickly grouped just above the ileo-cæcal valve. Some of them presented a central pin-hole-sized perforation. Peyer's patches were swollen, irregularly pitted and ragged-looking, and of a reddish colour, contrasting with the pale yellowish-white appearance of the rest of the mucous membrane. The development of

Peycr's glands was also most marked at the lower part of the ileum.

The mesenteric glands were enlarged and of a reddish tint. The liver was much engorged; the spleen was pale, firm, and large; the kidneys were normal.

An attempt was made to dissect out the semi-lunar ganglia and the nerve plexuses in connection with them. The dissection was commenced while the parts were *in situ*, and continued after their removal from the body. The matting together of all the tissues in the neighbourhood rendered this very difficult, and prevented a clear discrimination between the sympathetic nerves and the connective tissue. Some undoubted nerve fibres, forming the supra-renal plexus, were, however, distinctly dissected out; they were of the size and strength of cerebro-spinal nerves, and included a branch of the pneumogastric, which passed down by the side of the aorta and entered the left supra-renal plexus. This nerve was provided with a small bulbous swelling.

Supra-renal Capsules.—The right capsule was adherent to the liver and right kidney; it was enlarged, very hard, and nodulated on the surface. On section it was found to consist of a thick fibrous investment, glistening and vascular, surrounding irregular masses of opaque yellow material, of the consistence of cheese, and having mostly a gritty section, from the presence of calcareous granules. At one extremity this material was replaced by a collection of white mortar-like substance. These several masses, which wholly replaced the normal cortical and medullary substances, were of various sizes, and were separated from one another by transparent bands of fibrous tissue. In making the section a small quantity of opaque greenish fluid, of the consistence of cream, oozed out from one part, and was found on microscopical examination to consist of degenerate pus-cells. The left supra-renal capsule was almost the counterpart of the right, being in an equally advanced stage of degeneration. Numerous nerve-filaments were traced into the indurated tissue which formed the investment of the organ.

Spine.—The angular curvature was most marked in the lower dorsal and upper lumbar regions. The aorta was bent upon itself, at an angle of about 60°, in consequence of the spinal curvature, and here (just below the diaphragm) was the greatest amount of condensed fibrous tissue. In front of the spine, in the

lumbar and upper sacral regions, was situated a large collection of inspissated mortar-like material, but no recent pus. This matter was in great part seated beneath the anterior ligament, which was stretched over the firm wall of the sac of the obsolete abscess, to the formation of which it contributed. The bodies of several of the vertebræ at the back of the sac were denuded.

Microscopical Examination of the Stomach.—Vertical sections of the mammillated mucous membrane, taken from the neighbourhood of the pylorus, were examined under the microscope. The *mucosa* was greatly thickened by a wide-spread infiltration of small round lymphoid cells. This cell-growth had displaced the gastric tubules, leading to their atrophy, so that in most sections only the lowermost cells of the tubuli could be made out, while the rest of the tubule was represented by its thickened basement membrane, almost concealed by the round cells. The cell-growth was most abundant in the centre of each mammilla, where it had almost invariably broken down, forming either a closed sac filled with débris of cells, and lined by the exuberant lymphoid element or else a distinct open follicle, or ulcer (see Plate V. fig. 2). The cellular infiltration was almost limited to the *mucosa*, the sub-mucous tissue being furnished with large vessels and quite free from infiltration even in its uppermost layer. The muscular coat appeared to be unusually thick.

CASE IX.—*Addison's Disease. Typical Case.*¹

A gentleman aged 21, who had suffered in childhood from strumous ophthalmia, and several of whose maternal relations had died of phthisis, went abroad in the spring of 1863. He was then hearty and strong. About two years previously he had been treated for enteritis, for which he was leeches and salivated. After he had been abroad for about three months, he began to suffer from occasional attacks of prostration; that is to say, after a long day's walk he would be so exhausted that several days elapsed before he rallied, and each of these failures of strength seemed to be followed by less perfect reaction than the previous one. On his return to England in November his face was thin and pale, and somewhat resembled in colour that of a person recovering from jaundice, but there was no yellow-

¹ Case 28, Appendix B.

ness of the conjunctivæ. Early in February, after a so-called 'bilious' attack, he became much weaker, and on March 9 he came under the care of Mr. Charles L. Hodson, of Bishop's Stortford, who in a short time diagnosed the case as one of Addison's disease, from the discoloration of skin and the extreme asthenia, and the difficulty of accounting on any other hypothesis for the patient's steadily 'dying out' without any obvious disease.

The alternations of extreme feebleness and temporary rallying continued until April 4, when, after a short drive, he became so faint that he was carried upstairs to bed. A few days later distressing sickness supervened, and persisted until the patient died exhausted on April 16.

At the *post-mortem examination* several very dark moles were discovered on the arms and chest, and the areolæ round the nipples were as dark as those of a pregnant woman. The body was fairly covered with fat; the lungs and all the other organs, excepting the supra-renal capsules, were perfectly healthy.

Both supra-renal capsules presented a similar appearance; their surfaces were nodulated, and they were invested with very firmly adherent connective tissue. One of the capsules was considerably larger than the other, and measured rather more than three inches in its long diameter. On section, the capsules exhibited three appearances: some portions being semi-transparent and of fibrous consistence, others quite opaque and of cheesy material, and the intermediate parts being of firm consistence but also opaque. These different substances were so distributed that the most opaque and cheesy parts appeared as patches in the section, their margins passing insensibly into the semi-transparent portions. On examination under the microscope the semi-transparent portions presented the appearance either of fibro-cellular tissue—that is of nuclei, some round, others fusiform, embedded in a firmly fibrillated stroma—or else of more completely formed white fibrous tissue. In the most opaque deposits nothing could be seen but granular matter, the granules being highly refractive. In the intermediate portions the fibrous structure was rendered indistinct by the presence of granules similar to those of which the most opaque parts appeared to be altogether composed. The deposits of cheesy material were soft enough to admit of being easily squeezed out. (GREENHOW, *Trans. Path. Soc.*, vol. xv. p. 231.)

CASE X.—*Addison's Disease. Typical Case.*¹

Rebecca B., a married woman, aged 48, was admitted into St. Thomas's Hospital under Dr. Bristowe's care, on February 23, 1875. Her mother, one brother, and a sister, had died of phthisis. She had had no children, and the catamenia had been absent for the last eighteen years. Her general health had been good up to twelve months before admission. She then began to complain of gradually increasing weakness and occasional palpitation, but without shortness of breath. About the same time she observed a gradual change of colour in the hands and face. About six months ago she began to lose flesh, and about four months ago to suffer from sickness, unattended with other symptoms of indigestion, and coming on at irregular intervals, though often after food. Her weakness and loss of flesh have continued to progress up to the present time, but her change of colour, which had gradually become general and more intense, ceased, she thinks, to progress two months back. She has complained a good deal of coldness, especially in the hands and feet, the fingers and toes often becoming pale and shrivelled; she has complained also of occasional head-ache, of pain in the lower part of the back, but more especially of pain in the upper part of the abdomen, chiefly on the left side. Her breath has been very oppressive during the last six months. She gave up work two months ago.

The following notes were taken on March 3. Has improved somewhat since admission, and feels stronger. Suffered from sickness for a few days after admission, but this subsided, and she continued free until last night. The skin is universally dark, like that of a mulatto; the parts which are darkest are the face, elbows, backs of the wrists, hands, and fingers, knees, ankles, and dorsum of feet and toes. The palms and soles are comparatively pale, and the nails and sclerotics are of natural colour. The nipples, areolæ, and navel are not specially dark. Patches of pigment are scattered along the lips, and on the

¹ This case has not hitherto been published. I saw the patient during life, and was present at the *post-mortem* examination. I am indebted to Dr. Bristowe for the notes of the case during life, and to Dr. Greenfield for those of the autopsy.

buccal mucous membrane, and very large and well-marked patches stud the edges and tip of the tongue. The surface of the skin is neither dry nor moist, but it is covered with a very slight scurf. There are several superficial scars on the legs, which are very deeply pigmented.

Tongue clean, appetite poor, bowels regular. No sign of cardiac or pulmonary disease. Urine, sp. gr. 1020, free from albumen. No pain anywhere. Temperature on admission 100° ; pulse 96. Since then the temperature has ranged between 98.6° and 99.4° . The pulse is now 96, small and feeble, but regular. A very offensive odour is yielded both by the general surface and the breath.

March 10.—Has been very ill since the last note; has complained of pretty constant headache and nausea with occasional sickness, dryness of mouth and offensiveness of breath. She was retching all day yesterday and all last night, but is better in this respect this morning. Is extremely weak; tongue clean; bowels confined; passes little water; no pain. Heart's action regular, sounds weak; pulse 100, thready, scarcely to be felt. The temperature has varied from 98.4° to 98.6° .

13.—Is less sick than she was, but takes scarcely any food. Tongue clean; pulse 72, very small and feeble; temperature 98.4° . Is quite sensible, but has been gradually becoming remarkably dull and apathetic.

15.—Says she feels very ill. Rarely sick, but scarcely takes anything. Lips and teeth covered with sordes; tongue moist and clean; bowels confined; urine scanty; pulse 100, scarcely to be felt. The colour of the skin has become darker, and the smell of the patient is very offensive.

From this time she became progressively weaker; she suffered occasionally from sickness, headache, and giddiness; was extremely prostrate, took very little food, and was indisposed to take notice, or to make any effort. Her urine was scanty and deficient in urea. The pulse was almost imperceptible, and when noted was 120. The temperature ranged from 98.5° to 101.6 , being usually from 1° to 1.5° higher in the evening than the morning. She died on *March 23*.

Post-mortem Examination.—On opening the body a considerable amount of subcutaneous fat was found, a layer more than half an inch in thickness covering the abdominal muscles. The

pleuræ were generally and closely adherent ; the lungs free from any trace of disease. The heart was very flabby, the walls of the cavities thin, especially that of the left ventricle ; valves normal, muscular tissue of brownish colour and very friable.

The stomach was lined with a layer of tenacious mucus ; there were some slight mammillations, especially towards the middle of the greater curvature, and one minute follicular ulcer was discovered. Intestines healthy ; the liver, kidneys, and abdominal organs generally, were much engorged.

Supra-renal Capsules.—Left enlarged, firmly adherent to the spleen and left kidney. Surface slightly irregular and nodulated, and covered in some parts by a fibrous capsule formed by adhesions around it. On section the lower part was found to be much softened, and broken down into a greenish-yellow semi-caseous puriform fluid. The remainder was of a yellowish colour, and the cut surface closely resembled in appearance that of a fresh section of a horse-chestnut. (See Plate III. fig. 3.) In the centre of this caseous mass were one or two spots of translucent greyish colour, and surrounding the caseous mass was a layer of a similar pinkish gray colour, from which the central caseous mass separated readily. Right supra-renal capsule small ; surface irregular and nodulated. In some places the whole thickness of the organ seemed to have become destroyed, leaving only a small quantity of fibrous tissue. On section it consisted of nodules of grayish translucent substance, surrounded by pinkish fibrous-looking tissue. At one or two points there was also some caseous change.

The solar plexus and nerves leading to it were carefully examined. No obvious naked-eye change could be discovered, excepting in the branches of the coronary plexus, which appeared to be unusually developed and thicker than usual.

CASE XI.—*Addison's Disease. Typical case.*¹

John T., aged 20, upholsterer, was admitted into University College Hospital, under Dr. Ringer's care, on January 5, 1872.

For the last year his fellow-workmen had noticed that he

¹ Case 29, Appendix B. I was present at the *post-mortem* examination of this case, and am indebted to Dr. Ringer for the notes from which the report of the case and of Mr. Schäfer's microscopical examination has been drawn up.

looked ill, but he did not feel unwell, and continued at his work without interruption. Since July he had felt unwell, and had grown weaker. He caught a cold at that time, and attributed his weakness to that cause. About eight weeks ago a violent headache seized him, lasting three days, and accompanied by a good deal of vomiting; the vomiting continuing more than a week after the head-ache had ceased.

When admitted he was very thin, but stated that he had always been of spare habit, and did not think he was much thinner than before his illness. The skin of his whole body was of a dirty yellow tint, but neither the patient nor his friends had noticed any alteration in his colour. The discoloration was not uniform, being most marked over the forehead, and fading away towards the roots of the hair and the temples. The skin was deeply coloured over the eyelids, neck, axillæ and shoulders, around the nipples and umbilicus, over the penis and scrotum, the front of the knees, the nates, the lower part of the sacrum, and along the cleft between the buttocks. Along the dorsal part of the spine were a series of spots as large as the end of a finger, corresponding to the prominent spinous processes. On the belly was a dark sharply defined spot, produced by a mustard poultice. The discoloration was most intense around the nipples, over the scrotum and lower part of the sacrum, extending between the buttocks over the perinæum. The darker spots, with the exception of that produced by the mustard poultice, were not sharply defined, but faded gradually into the less deeply tinted skin. The palms of the hands and soles of the feet were of a natural colour, and there was no excess of discoloration on the backs of the hands. The conjunctivæ were very pale and in no part discoloured, nor was there any discoloration of the mucous membrane of the lips or mouth. He stated that his appetite had failed lately, but he suffered from no pain after food, and only occasionally from sickness. He felt very weak, slight exertion fatiguing him, and he had a constant feeling of lassitude and disinclination for work. He complained of cold hands and feet. Pulse small and compressible. Heart-sounds feeble.

After about three weeks in the hospital he had become much worse. On January 29 the discoloration had increased, especially round the nipples and in the skin of the scrotum. His appetite had been very bad, he had suffered from nausea and vomiting,

and he had for some days been too feeble to leave his bed. His bowels had been regular, but on this morning diarrhœa set in, which, however, was controlled after four or five motions. His breath was rather short on exertion; his pulse was very small and could scarcely be felt. On this day it was noticed that his temperature under the tongue was only 95.5° , and at 9 P.M. it was only 90.2° . He had had no headache nor delirium, but he now complained of feeling giddy, confused and sleepy, though he answered questions rationally. Previous to this day the temperature had varied from 97° to 98° , and the pulse from 72 to 86. The urine was free from albumen and sugar, was of natural colour, and had a specific gravity of 1016 to 1018. He continued to sink, his pulse became imperceptible, the temperature remaining about the same; he became delirious and then unconscious, perspiration broke out over his face, and he died at 4.40 A.M.

Post-mortem Examination.—Seven hours after death. The brown discoloration of the skin remains unaltered. There is very little sub-cutaneous fat, and no fat in the omentum. The heart is covered with less fat than usual, and is flaccid and empty, containing neither liquid nor clotted blood. The mitral valves are much thickened, and decidedly ‘beaded;’ the aortic valves are somewhat thickened, especially at their attached edge. In other respects, the valves are healthy; there are a few patches of atheroma in the aorta, a little above the heart.

There is one slight adhesion of the pleura at the apex of the left lung. The apex of both lungs is capped by thickened pleura the size of a five-shilling piece, and under this thickening one or two hard rounded bodies are felt. In the inferior lobe of the left lung close under the pleura is situated a hard cretaceous body the size of a big pin’s head, surrounded by pigment, with the lung-tissue puckered in its immediate neighbourhood. The lungs are otherwise healthy, and contain no tubercle.

The liver and gall-bladder are healthy. About ten feet down the small intestine the mucous membrane is highly congested, with some ecchymoses at the edges of the valvulæ conniventes. The congestion is more marked, and the hæmorrhages are more numerous as we descend, especially over Peyer’s patches, which are unusually prominent and very translucent. The mucous membrane of the large intestine is free from congestion and

hæmorrhage, but the solitary glands are large, prominent, and marked with a black central spot.

The stomach is pale and is dotted over with opaque, milky-white spots, very numerous at the lesser curvature close to the pylorus, and varying in size from a mere point to a pin's head, which project from the surface, and are marked by a central, rather depressed spot. These opaque spots are, no doubt, altered closed glands, for these latter are very distinct, and every gradation can be traced between the quite healthy ones and those most affected. The mesenteric glands are pale and rather milky; those in the neighbourhood of the head of the pancreas are rather enlarged and mottled, containing spots pale and translucent, sharply defined from the deeper coloured parts. The pancreas and kidneys are healthy. The brain and its membranes are healthy. The vertebræ are healthy, and there is no trace of lumbar abscess.

Supra-renal Capsules.—The envelope of the left capsule is greatly thickened, especially at one spot on the anterior surface, and, having numerous bands radiating from it, has a puckered look not unlike a cicatrix. Neither of the capsules is adherent to the kidneys. Both capsules feel unusually hard and nodular, the nodules feeling about as large as a moderate-sized pea. The left capsule is the larger of the two, and weighs 154 grains. On dividing it we see that the natural structure is completely lost. The gland is firm, almost cartilaginous. The section is smooth, and looks something like a section of horse-chestnut. The consistence is generally uniform, but the colour varies, being in most parts of a greenish-yellow tint and translucent, whilst at places it is white and opaque, these opaque spots being embedded in the more translucent structure. These light-coloured opaque portions are sharply defined, and some of them are distinctly cretaceous.

The right capsule weighs 98 grains, and is shaped like a cocked hat. It is apparently less diseased than its fellow, though none of the healthy structure can be detected. It is less thickened and less fibrous, but more nodulated than the left capsule. Its section is much like the other, but the firm portions are smaller and are held together by mere fibrous tissue, and it contains no cretaceous matter.

*Microscopical Examination.*¹ *Supra-renal Capsule.*—A section of this body appears pretty homogeneous to the naked eye, with the exception of some small yellowish pin's head spots, more or less hardened by calcareous deposit. In stained sections these spots remain entirely unstained.

Under the microscope no trace of the normal structure is to be found in the gland, with the exception of a few of the medullary cells, but it is seen to consist principally of coarse bundles of fibres, more or less parallel in direction in the same part of the gland, and, between the bundles, rows of lymphoid cells; so that the cross section of a bundle appears surrounded by a ring of these cells. In some parts the cells largely predominate, in others the bundles of fibres alone remain; in the yellowish spots above mentioned, and in some other places also, there is nothing to be made out but a mass of granular débris.

In some parts of a section one may see all these varieties of structure side by side, viz. first, and commonly nearest the exterior of the gland, lymphoid cells, then fibrous bundles with these cells intermixed at first, but gradually disappearing as we proceed further inwards; and finally a structureless, granular, more or less calcareous patch, the transition in this case being more abrupt. From the occasional presence of lymphoid cells around the structureless patches, it seems probable that these latter result from the degeneration and breaking down of collections of such cells.

Enlarged venous and lymphatic channels are here and there to be observed in sections of the gland in question.

Bronzed Skin.—The excessive pigmentary deposit is principally situated in the deepest layer of epidermic cells, the pigment being for the most part within the cells and accumulated around their nuclei; some of it, however, appears to exist in irregular patches between and amongst the cells. In the horny layer of the epidermis, in some places at least, it is the *nuclei* of the cells which are pigmented, the other parts being free, or almost free, from pigment.

With regard to the *cutis vera* there is only one fact here worth noting, and that is the presence, especially near the epidermis, of

¹ Reported by Mr. E. A. Schäfer, Assistant Professor of Physiology in University College, London.

a number of irregularly-shaped corpuscles, apparently wander-cells, some of them perhaps connective-tissue corpuscles, remarkable from the fact of their containing a considerable amount of pigment.¹

The *stomach* presents on the surface, to the naked eye, especially near the pyloric end, a number of small prominences, resembling in general appearance the solitary follicles met with in the intestine, but larger and more opaque; some of them have small depressions in the centre.

Microscopical examination of sections of the gastric wall brings clearly into view the cause of these appearances. Even with the unaided eye it may be observed, on bringing the sections up to the light, that the opacity at the spots in question is principally, in some cases almost entirely, situated in the mucous membrane, close to the internal surface of the stomach; and, with the instrument, the patches are seen to be composed of a dense mass of lymphoid cells. With regard to the depressions above noticed in some spots, sections show that they are due to a breaking down, and opening on to the surface, of the summit of the patch. In no case do these collections of cells rise up from the *submucosa* through the *muscularis mucosæ*, as is the case with the solitary follicles of the intestine; they may be continued down between and amongst the peptic glands as far as the *muscularis mucosæ*, through which a large artery and vein may commonly be traced opposite them. The follicular patches may either displace the gastric glandules, these then curving round them, or may exist merely as an extensively diffused infiltration of lymphoid cells, between the glandules, and chiefly near the surface.

The blood-vessels in the *submucosa* are considerably enlarged in the proximity of the patches in the *mucosa*, and their neighbourhood presents an unusual number of connective-tissue corpuscles; the veins are intensely congested, and there are one or two small patches of ecchymosis; otherwise this and the two remaining coats are normal.—(GREENHOW, *Trans. Path. Soc.*, vol. xxiv. p. 229.)

¹ A similar condition of the wander-cells of the corium has been noticed by Biesiadecki in conical condylomata.—*Stricker's Handbuch der Geweb.lchre*, p. 592.

CASE XII.—*Addison's Disease. Apparently Typical Case.*¹

James F., aged 32, applied for relief at the out-patient's department of University College Hospital, in October 1872. He had been ill about eighteen months, and had lost a good deal of flesh. He only complained of great weakness. The skin of his whole body was deeply discolored, the discoloration being most marked on the neck, round the nipples, in the axillæ and groins, over the penis, scrotum, and perinæum, and between the buttocks. There were also several inky-looking spots on the mucous membranes of the cheeks and tongue. The conjunctivæ were unnaturally pale. All the organs appeared healthy.

He continued in much the same state for several months, sometimes improving a little, but on the whole gradually growing weaker. With each slight improvement the discoloration of skin grew decidedly less, but on each relapse it became darker than before. For some weeks before his death, which took place April 3, 1873, he was confined to bed. His appetite throughout was very bad, and medicine and many kinds of food made him feel sick; but he never suffered much from sickness, nor palpitation, nor shortness of breath, until a few days before his death, which was caused by a sharp attack of diarrhœa. His temperature had always stood about 98°, but after the outset of the diarrhœa it fell to 94°, and though raised by stimulants, fell again to that point before death.

At the *post-mortem* examination the abdomen only was allowed to be examined. The liver, spleen, and kidneys were healthy. The intestines and stomach were not examined. The supra-renal capsules were strongly adherent to the neighbouring organs, and each of them was found to be converted into a semi-solid, mortar-like mass, which proved to be almost entirely calcareous. It was surrounded by a thick, firm, fibrous investment, white and shining on section, and separating from the contained calcareous mass after being left in spirit. Microscopically, the outer portion was found to be almost entirely made up of bands of fibrous tissue. No trace of the normal tissue of the organs remained.—(GREENHOW, *Trans. Path. Soc.*, vol. xxiv. p. 234.)

¹ Case 111, Appendix B.

CASE XIII.—*Addison's Disease without Discoloration of Skin.*
*Rapid Phthisis.*¹

Thomas P., aged 40, by occupation a porter, was admitted into the Middlesex Hospital, under the care of Dr. Thompson, on April 8, 1873. He had enjoyed good health until a month before his admission, when he began to feel languid, and noticed that he was losing flesh. His appetite failed, and he vomited after taking food; he also suffered from a short hard cough. A week before his admission he took cold from getting wet, and experienced sharp pains in the loins, followed by œdema of the feet and puffiness of the face in the morning. He had been a very temperate man, and had never spat blood.

On admission, there was œdema of the lower limbs and puffiness of face, but the urine was not albuminous. Patient had a severe cough, attended by a copious muco-purulent expectoration.

The whole right front of the thorax was markedly dull, and yielded, on strong percussion, a ringing resonance and cracked-pot sound at the third intercostal space. In the same situation there were coarse gurgling râles of high pitched metallic tone. Elsewhere the breathing was generally sonorous, and fuller on the right than on the left side. The pulse was about 120, and the temperature varied from 102° to 103°. He passed from 50 to 60 ounces of urine daily, but neither albumen nor casts were found in it at any time. He became rapidly worse, and died on April 20.

Post-mortem Examination.—The pericardium contained about eight ounces of fluid. The valves of the heart were all competent, with the exception of the tricuspid. Both sides of the heart were somewhat dilated.

The right lung was everywhere adherent, and the upper lobe contained one large ragged cavity. The remainder of the lobe was solidified; the cut surface being smooth, firm, and of the consistence of cheese. It was mainly composed of a large irregular tract of caseous matter, intermingled with tracts of grey translucent substance, apparently interstitial and peri-bronchial over-growths of fibrous tissue.

¹ Case 208, Appendix B.

The upper third of the lower lobe was solidified by the same opaque yellow material, and bounded off by a rather distinct line of demarcation from the rest of the lung. The bronchi in both lobes were much dilated and thickened. The left lung was emphysematous at its apex and anterior margin. The posterior three-fourths of the upper lobe were solidified by caseous material and recent grey hepatitis, and several caseous masses were also scattered through the lower lobe.

The solitary glands near the lower end of the ileum were enlarged and opaque, appearing as white nodules of the size of mustard-seeds; some of them were broken down in the centre. A group of lymphatic glands in the neighbourhood of the cæcum were calcified. The kidneys were much congested, and the capsule of the left kidney was partially adherent.

The *right supra-renal capsule* was nodulated and enlarged, weighing three-quarters of an ounce. It was completely disorganised, a strip of the cortex, one line in diameter, being all that remained of the normal structure. The rest of the capsule was transformed into a firm, smooth, opaque, yellowish-white material, which in the lower half of the organ was broken up into small areas, separated by grey translucent fibrous tissue. This capsule presented, in fact, to the naked eye precisely the appearances characteristic of Addison's disease. The left supra-renal capsule weighed half an ounce, and presented no abnormal appearances to the naked eye.

Microscopical Examination by Dr. Sidney Coupland.—By far the larger part of the organ was in a state of caseous metamorphosis—the change being limited to the variously-sized opaque areas seen by the naked eye. Microscopically it consisted of the usual finely granular amorphous material, with, in addition, numerous translucent bodies, more or less oval in shape, about $\frac{1}{200}$ ths of an inch in diameter, resembling the *corpora amylacea* found in degenerated nerve-tissue, but not yielding any reaction to iodine. There were also some longitudinal traces of the same highly refractile material. Here and there a small group of acicular crystals was collected, probably composed of stearine. Surrounding these areas of retrograde metamorphosis were grey translucent tracts, composed almost entirely of small round cells, or nuclei, together with a certain amount of fibrous tissue. No definite adenoid structure was made out. Finally, at one part,

where a narrow rim of cortex remained, the normal cell-columns persisted; encroached on below by the small-cell infiltration, which contained a few isolated and atrophied normal cells in its interior.—(GREENHOW, *Trans. Path. Soc.*, vol. xxiv. p. 235.)

CASE XIV.—*Addison's Disease. Typical Case. Bronzed Skin. Death after a few Days' Illness.*¹

W. P., aged 20, formerly a painter, but now a baker, was admitted into the Middlesex Hospital, under the care of Dr. Seth Thompson, on July 11, 1854. The patient's friends had noticed that the colour of his skin had been gradually changing for about six weeks, and that for a few days the change in colour had been more rapid. He, however, continued his work of baking up to Saturday, July 8. On Sunday the 9th he dined with some friends, and appeared in quite as good health and spirits as usual. On the following day (the patient stated) he first commenced to feel languid and unable to move about. He felt some soreness in the throat, but had no rigors. On Tuesday, July 11, he went in the afternoon to the house of a friend, and threw himself on the sofa, saying that he was unable to move; he was then brought to the hospital. Previously to this attack he had always enjoyed good health; he was of sober habits, and had had abundance of good food.

State on Admission.—Skin of a peculiar, dark, dirty-brown colour; conjunctivæ of a similar colour; skin covered with a cold clammy sweat; pulse scarcely perceptible; tongue clean; bowels generally regular; open with medicine this morning. He is restless and answers questions with difficulty, although he appears perfectly conscious.

On being placed in bed, warm fomentations, hot bottles, &c., were applied; brandy was administered; the pulse was partially restored. The bowels acted three or four times, the motions being dark and partly liquid. He stated that the only pain he had was deep-seated, and in the region of the liver. The same cold sweat continued, and he died at 4 A.M. the following morning.

Post-mortem Examination.—Body extremely muscular and well-formed; rigidity extreme; the entire surface is of a uniform

¹ Case 76, Appendix B.

peculiar brown colour; there is slight lividity of the lips and back.

The brain and its membranes healthy. The lungs healthy, with the exception of some slight congestion. Pericardium firm and universally adherent. The heart and its valves quite healthy.

Liver extremely tough and deeply congested. Bile in the gall-bladder liquid, of a pale yellow colour. The whole of the solitary glands of the small intestine enlarged, forming little solid eminences the size of millet-seeds. At the lower end of the ileum there are two spots of superficial ulceration. Peyer's patches are not affected. The mucous membrane of the colon quite healthy.

The kidneys tolerably firm and healthy, of natural size.

Both supra-renal bodies are enlarged, forming solid tumours of nearly half the bulk of the respective kidneys, but retaining their characteristic form. They are firm and dense. On section they are seen to be composed of tubercular-looking material, *i.e.* of an opaque yellow substance of the consistence of soft cheese. Portions of this substance appear to be tubercle, as seen in the brain, while other parts are soft and broken down, like the matter of a scrofulous abscess. In one or two places portions of the natural structure of the supra-renal bodies can be detected. (SIBLEY, *Med. Times and Gazette*, vol. xxxiii. p. 188.)

CASE XV.—*Addison's Disease without Discoloration of Skin. Psoas Abscess and Caries of the Lumbar Vertebrae.*¹

A mechanic, aged 30, was admitted into the Middlesex Hospital in September 1862, with pain and tenderness in the lumbar region of the spine, and a deep, fluctuating swelling in the left lumbar and inguinal regions of the belly, which communicated beneath Poupart's ligament with a large indolent abscess lying across the top of the thigh, between the common femoral vessels and the anterior superior spine of the ileum. These local signs were accompanied with emaciation, a degree of feebleness quite out of proportion with the loss of flesh, a very irritable stomach, and obstinate constipation.

It was plainly a case of spinal caries, with psoas abscess. A horizontal posture was enjoined, and small doses of strychnia

¹ Case 211. Appendix B.

were ordered. Under this treatment the stomach became less irritable, he was able to take more nourishment, and his condition improved slightly. The abscess during this time remained nearly stationary. November 6, at 9 A.M., on rising from his bed to go to the neighbouring water-closet, he became faint, grew weaker during the day, and expired at 8 o'clock the following morning. During this last attack his breathing was quiet, air entered his chest freely, but his lips became blue and his complexion dusky.

At the *post-mortem* examination, made thirty hours after death, an abscess, holding nearly a pint-and-a-half of pus, was found in the course of the left psoas magnus. Its source was a small cavity hollowed out in the bodies of the third and fourth lumbar vertebræ, which contained some small sequestra and thick curdy pus. The boundaries of this cavity were uneven and friable, and the bony tissue for some distance around was solidified by a lardaceous deposit in the cancelli. The sac of the psoas abscess was thick, particularly at its lower end, where it communicated with the abscess below the groin by a small circular opening beneath the outer end of Poupert's ligament. The mass of the psoas had disappeared, only a small quantity of pale muscular tissue in connection with the twelfth dorsal and two upper lumbar vertebræ remained, and contained many small circumscribed abscesses.

On the opposite side of the spine there was a second and smaller abscess, reaching as high as the twelfth dorsal vertebra, and turning below towards the left, across the front of the third lumbar vertebra, beneath the anterior common ligament, where it communicated with the cavity already described, and ended in the first abscess. The sides of the bodies of the first and second lumbar vertebræ were denuded and bathed in pus, and the bony surfaces were rough and had large vascular foramina, but were neither carious nor necrosed.

The abdominal viscera were healthy, with the single exception of the supra-renal capsules, which weighed 140 and 215 grains. They were hard and knobby. On section, they presented a homogeneous surface, mottled with a few yellowish, friable specks. In several microscopical preparations taken from them, traces of the tubular structure were discernible. The enlargement of the organs appeared due to infiltration with a material which was in a fresh state, nearly homogeneous and translucent,

but, after immersion in carbolic acid, finely granular. The apices of both lungs contained a few scattered depôts of tubercle. The right pleural cavity was almost entirely obliterated by old adhesions. The left side of the heart was nearly empty, whilst the right auricle was over-distended with a black, spongy, friable clot, and the right ventricle contained a mass of tough fibrine, wrapt about the muscoli papillares, and prolonged through the trunk and primary branches of the pulmonary artery into the small divisions of this vessel. (HULKE, *Trans. Path. Soc.*, vol. xiv. p. 254.)

CASE XVI.—*Addison's Disease. Typical Case.*¹

J. F., a native of Scotland, and formerly a maid-servant, applied to me (Dr. Burdon-Sanderson) as an out-patient on September 16, 1867. The nature of the case being obvious, she was at once admitted into the Middlesex Hospital, where she remained under my care until August 21, 1868. Until the commencement of her present illness she had enjoyed fair health, but had occasionally suffered from cough. It appears that in July, 1866, she fell down-stairs, after which, she says, she brought up some blood, and felt pain in her back for more than a week. Soon after this occurrence she began to lose her health. She states that she caught cold. In addition to a slight cough, which was of short duration, she became weak and listless, and was obliged to give up her situation. Then complete anorexia, with vomiting, came on, and continued for several months, becoming worse and worse. Early in 1867, however, she got better; the sickness ceased for two or three months, during which she was able to resume her duties. Again she took ill, and again recovered, so far as relates to the more urgent symptoms, but was now so much enfeebled that she was unfit for work. In this state she remained until a fortnight before her admission, when she had a third attack of vomiting, this time, however, of very short duration.

The patient's antecedents were pthisical. Her father had died of hæmoptysis at the age of forty, and of three brothers one had died of 'heart-disease.' She herself had had hæmoptysis

¹ Case 71, Appendix B.

three years before admission, and had since suffered occasionally from cough.

On admission she complained principally of drowsiness, feebleness, and breathlessness on exertion. The whole anterior surface of the body was of a brown mulatto hue, which was darkest on the front and sides of the neck and around the nipples. Whitish, or pale-coloured cicatrices, were noticed in various situations, and there were pale traces of an eruption and of scratching on the shoulders. A patch of discoloration was observed on the lower lip, and a smaller patch on the upper. Other patches existed on the mucous membrane of both cheeks. The tongue was free from discoloration. On examination of the chest it was noted that the right supra-spinous fossa was duller than the left, and that below both clavicles the resonance was defective, where the expiration-sound was harsh. No moist sounds could be detected. A patch of dulness was also made out in the axillary line, in which situation a few crackles with harsh breath-sounds were heard, near the lower pulmonary margin. A faint, soft, systolic bruit could be distinguished at the fourth left cartilage. Pulse, 84; respirations, 20, tranquil; tongue clean and bare; urine, sp. gr. 1,016, not albuminous.

Three days after her admission vomiting came on and occurred almost daily for the next six weeks. The vomited matter discharged during the night was alkaline and mucous, that after meals being acid. The attacks occurred indifferently after meals and during intervals; they were not preceded either by pain or nausea. During the whole period the patient was in a strikingly listless condition. She made no complaint, but seemed annoyed by interrogation. The pulse varied from 72 to 92; respirations 30, exceedingly inconsiderable. Towards the end of the period the vomiting of food ceased, but she continued to excrete mucus every morning in considerable quantity, which was often mixed with blood.

On October 25 a new group of symptoms presented itself. Her answers to questions became incoherent, and she complained of being annoyed by rats, which she said were creeping on her bed.

On the 27th the intellectual disorder increased. On my visit on that day I noted that the patient moved about constantly in

bed, as if in distress. There were constant rotatory motions of both eyeballs, the left usually squinting inwards, and the left eyelid dropping. During the observation she suddenly became excited, screaming out, 'These people are going to kill me!' her pupils at the same time becoming contracted. During the whole of the next two days she remained in a state of busy, talkative delirium, frequently endeavouring to get out of bed, making grimaces, singing, vociferating rapidly and incoherently, or shrieking out as if in terror; her condition in other respects was not materially altered. Her appetite was good, her pulse was unchanged either in frequency or character (small, varying from 80 to 88), and her skin cool. The urine, which was for the most part passed involuntarily, was of the same character as before.

During the night of October 29 she slept, and woke next morning rational, and awake to external impressions, but in the afternoon of the following day she suddenly became faint, and the respiratory movements, which had resumed their usual character again, became rapid and voluminous. Soon after she became once more excited and talkative, and began to squint and make grimaces, the delusions to which she referred being for the most part of the same nature as before. These phenomena were of short duration, but recurred several times, each attack being preceded by faintness. During the next week they gradually subsided, but she continued to wander occasionally. On November 6th a vaginal discharge appeared. This lasted till the 13th, when, concurrently with the appearance of the catamenia, she became more excited than usual, and for the first time refused to take her food, and gave other proofs of obstinacy and ill-nature. Towards the end of November her intellectual disorder ceased; she still, however, squinted slightly, and the respiratory movements were still irregular.

During the month of December she remained in the same state; the bowels were frequently confined, and she suffered from time to time from vomiting, and often complained of lumbar pain and of temporal head-ache. Pulse, 88 to 96; respirations, 24 to 26, respiratory movement remarkably limited; catamenia absent; occasional leucorrhœa.

From January 7 to March 18 the general condition of the patient varied inconsiderably, being, as regards the symptoms

previously described, as follows:—She complained, more or less constantly, of faintness and breathlessness. Both of these sensations were associated with frequent and irregular respiratory movements, and came on in paroxysms of short duration, which were more frequent during the day than during the night. From time to time there were severe muscular pains of the limbs, and particularly of the back of the neck. She was often sleepless, the want of sleep being ascribed either to the pains or to the 'faint sensation' above referred to. There was no night wandering, and she was entirely free from delusions. The skin presented the same aspect as before, but was thought to be paler. There was on one occasion transient œdema of the ankles. The temperature, which was taken daily, varied from 97·5° Fahr. to 95·4° Fahr.; the pulse from 82 to 92, and the respirations from 36 to 46. Excepting that the bowels were confined, and that she occasionally vomited, there were no signs of disorder of the digestive system. The urine was also examined daily, was always acid, and never contained albumen; it varied in specific gravity from 1,015 to 1,022, the mean being 1,020, and the mean quantity of urine passed daily being about 25 ounces. The catamenia were scanty, and appeared at irregular intervals.

After this the patient was kept under observation for several months, during which her state was as above described. On the evening of August 21, without any previous change for the worse excepting a recurrence of vomiting, she had a convulsive paroxysm. This, according to the account of the ward-sister, consisted in rigidity of the arms, grasping contraction of the hands, and distortion of the features, and was accompanied with foaming from the mouth and nose, and stertorous breathing. As the fit passed off she sweated profusely. It was succeeded by violent vomiting and retching, which subsided after a few hours, leaving the patient in a condition of collapse, which ended in death.

Post-mortem Examination.—The body well nourished, much yellow fat beneath the integument. Surface dusky brown; face, neck, arms, axilla, and inguinal folds being darker than the rest of the body. The areolæ round the nipples are nearly black. There are several pale patches on the legs.

Head.—Pia mater injected, sinuses of dura mater filled with dark blood, brain substance apparently hyperæmic, half an ounce

of clear serum in the ventricles. The corpora striata and optic thalami are somewhat macerated, while the septum lucidum and fornix are almost diffuent. On subsequent microscopic examination of the softened parts no compound granular corpuscles were found.

Thorax.—Both pleuræ adherent. Punctiform sub-pleural ecchymoses scattered over the posterior surface of the lower lobe. At the apex of the right lung a small cavity is found, having thick walls and surrounded with indurations. It contains cheesy matter. Near it is a patch of red and grey pneumonic consolidation. The apex of the left lung is puckered, and contains a similar cavity, but no recent consolidation. The greater part of the lower lobe is engorged. Here and there, where red hepatisation is commencing, the lung-tissue has lost its buoyancy in water. The heart and pericardium exhibit no abnormal appearances.

Abdomen.—The peritonæum is natural, and, with the exception of the supra-renal capsules, the abdominal organs are healthy, much fat being deposited in the omentum and other parts. The right supra-renal capsule could be felt very distinctly as a hard mass adherent to the under surface of the right lobe of the liver; the left one was made out with more difficulty, being indistinguishable from the kidney. While the organs were still *in situ*, the splanchnic nerves on either side were traced down to their connection with the plexus surrounding the cœliac axis; the trunk of the sympathetic nerve was also traced in both directions, and was seen to give off communicating branches to the same plexus. This having been done, the kidneys, the part of the liver to which the right supra-renal capsule was attached, the pancreas, the aorta and its branches, along with the parts lying in front of it, were removed *en masse*, for more complete dissection; the nerves forming the plexus already referred to were then dissected out, when it was found that each capsule was connected with the central plexus by a number of interlacing cords, consisting more or less of nerves. No evidence that the nerves were themselves diseased could be obtained by microscopic examination. It seemed, however, clear that they were so imbedded in induration that their function must, in all probability, have been seriously interfered with.

On making a section through the left kidney, in such a manner as to cut through the supra-renal capsule along with it, it was found that the latter was much altered in structure, and so firmly united with the kidney as to be wholly inseparable from it. The preparation shows that the organ forms an ill-defined mass of induration, the general contour of which resembles that of a large raisin. In the sectional surface it is seen that whereas the peripheral part of the tumour is of firm consistence and semi-transparent, the centre is softened, some parts being diffuent and of a yellow colour, while others are gritty, and exhibit cretaceous concretions. In the right capsule the disease is not so advanced, the centre is soft, resembling a lymphatic gland in process of caseation, the outside being hard and semi-transparent, although scattered with minute foci of softening. That part of the liver to which the capsule adheres is indurated and altered to such an extent that it is very difficult to distinguish its natural surface. The right capsule does not adhere to the kidney or any other organ, excepting the liver.

The diseased parts were subjected to careful microscopic examination after hardening in chromic acid. The semi-transparent induration was found, when it had not undergone caseation, to consist of a more or less fibrillated stroma, abundantly beset with spheroidal corpuscles, somewhat larger than blood-globules. This structure was found not only in the supra-renal capsules themselves, but also in the diseased parts of the liver and kidneys, in both of which it constituted the induration above described. The adventitious tissue spread around and among the glandular elements of these organs in such a manner that, in the liver particularly, sections of the indurated parts presented the same anatomical characters as are observed in the condition of the organ usually described as chronic interstitial inflammation.—(BURDON-SANDERSON, *Trans. Path. Soc.*, vol. xx. p. 378.)

CASE XVII.—*Addison's Disease. Typical Case.*¹

Thomas L—, aged 32, was admitted into Guy's Hospital under the care of Dr. Addison, on July 2, 1858, in an extremely debilitated condition, and died rather suddenly three days after-

¹ Case 92, Appendix B.

wards. The case was well known, as the patient had been under observation for more than two years. He lived at Walworth, and was employed as driver of a stationary engine in a seed-bleaching factory. He was first admitted into the hospital on October 10, 1856, under Dr. Habershon, having already been an out-patient under that gentleman's care for five months previously. He then stated that he had been rather a free liver, and had suffered from gonorrhœa and syphilis, and that about twelve months before he had observed that he was losing strength, and that his skin was becoming of a dark hue. He had sought medical advice in consequence, and was said to have liver disease; he also had at that time pain in his side. On admission he had a haggard, worn expression of countenance; he was of spare frame, and his skin was of a dark colour, resembling that of a mulatto, and almost black on the scrotum; the mucous membrane of lips and gums was also darkened in hue. Heart feeble; pulse 64; chest healthy; urine natural; his eye-sight was dim, and he suffered from faintness after the least exertion. The case was at once recognised as one of Addison's disease, and Dr. Habershon, in discussing what could be done for him, considering that the symptoms of asthenia were due to some loss of function of the semi-lunar ganglia and solar plexus, proposed the use of electricity. This was adopted, with the internal administration of iodide of potassium and bark, and the man left relieved after a few weeks. After leaving the hospital, he stated that he felt a little better, and was able to follow his employment until three weeks before his last admission, when he took cold and became much worse. He then stated that his strength had been good, but it was evident that he had become accustomed to an unnatural condition, for he would not admit his extreme weakness even then, although he could scarcely stand. The skin was of a dark brown colour, and of a deeper tinge at navel, nipples, and scrotum; mucous membrane of gums and mouth stained with patches of a leaden hue. He had dizziness and failure of vision on attempting to walk; no appetite. He after this got still weaker, and died rather unexpectedly on the morning of July 5.

Post-mortem Examination.—External appearance of body spare, but not wasted; an average amount of sub-integumental fat, and also fat to the usual amount in the abdomen. Muscles red

and of good size, as if they had been exercised of late. The colour of the body was most remarkable, resembling that of a mulatto, or one of dark blood, and contrasting with the white skin of another body which lay by its side, and which it had resembled three years before. The colour was of a slight greenish brown, and the subject would undoubtedly have been taken for a man of colour had not the previous history been known. The brown hue was universal, except on the lower parts of the legs, which were lighter, and was remarkably uniform, there being no lighter nor darker patches on any parts, excepting two black specks on the face. The axillæ, umbilicus, and genital organs, however, were of a darker shade. No distinct patches of pigment on the lips, but the margin next the skin of a dark hue. Hair darkish, but not black; eyes grey. Brain healthy; pituitary body healthy. Lungs healthy. The apex of the right lung contained a dry cretaceous mass, the size of a pea. This lung adherent by old cellular tissue. Heart small; muscle firm, red, and healthy; a small, loose coagulation on right side. Veins full of blood. Stomach.—Mucous membrane highly injected, and the surface covered with tenacious mucus, as if gastritis or a low form of inflammation had existed. Intestines healthy, with the exception of a remarkable prominence of Peyer's patches, and the solitary glands at the lower end of the ileum. Mesenteric and other lymphatic glands healthy. Liver, spleen, and pancreas healthy. Kidneys healthy, with the exception of one presently to be mentioned.

Supra-renal Capsules.—Both organs quite destroyed in structure by adventitious deposit, an albumino-cretaceous material. There appeared also to have been an inflammation of their investing capsules, as they were firmly united to the surrounding parts, and were with difficulty dissected out; thus, the right was adherent to the liver and top of the kidney, and the surrounding fat could not be stripped off in the ordinary way, but being adherent, the organs could only be rendered clean by scraping. The right supra-renal capsule was about the size of the healthy organ, but the left was puckered into a roundish mass, about the size of a walnut. When cut through they presented the usual appearance of the disease which so frequently attacks these organs, being converted into a whitish, amorphous matter, which was formerly called scrofulous. This consisted mainly of two

parts—a white, brittle, cretaceous matter, and a semi-translucent, soft, dry matter, resembling a dirty-coloured blancmange. The latter was probably the original or primary deposit, and the former the same having undergone degeneration. The right capsule, in addition, was softening in its middle, and contained about a drachm of a cream-like fluid. The disease on this side had slightly encroached on the kidney, the top of which contained a soft, whitish spot. The microscope showed the adventitious matter to be structureless; the softer, semi-transparent parts consisted of an amorphous substance, mixed with granules; the latter, being collected in small groups, put on the appearance of cells and nuclei, and probably they were such degenerating, but no cell or fibre-structure could be distinctly made out. The yellower, friable matter, consisted of little else than fatty and cretaceous granules. The white spot at the top of the kidney, in contact with the right capsule, contained some nuclei and nucleated fibre, and appeared to consist of a simple inflammatory product.

The semi-lunar ganglia appeared healthy, but their nerve branches ran quite into the diseased capsules, and were lost in them. The skin, when a section was made, showed most admirably the position of the pigment. It was situated beneath the epidermis, in the rete mucosum, following the course of the papillæ, and thus exactly resembling the integument of a black man. (WILKS, *Guy's Hospital Reports*, 3rd series, vol. viii. p. 42.)

CASE XVIII.—*Addison's Disease. Typical Case.*¹

Edward G., aged 18, a bookbinder, who had resided at Islington, was admitted into Guy's Hospital Sept. 9, 1863, under the care of Dr. Habershon.

At the Christmas of 1861 he had had an abscess in the neck from disease of the glands; discharge took place, and his health failed from that time. His skin had gradually assumed a deep mulatto tint, and his strength lessened; there had been slight irritability of the stomach, but neither cough nor diarrhœa had weakened him. On admission, the skin was generally of a deep colour, but

¹ Case 32, Appendix B.

in some parts it was nearly black ; thus, on the neck there were two narrow, almost black rings ; the axillæ also were dark. He was a spare young man ; the brain was clear, neither had he headache nor disturbance of the senses. The respiratory sounds were feeble, but there was no dulness on percussion, no cough, and no dyspnœa. The sounds of the heart were feeble ; the pulse was compressible. The abdomen was contracted, the appetite tolerably good, and there was no vomiting. There was slight abnormal deposit of pigment on the lips. His only complaint was a sensation of great weakness. He was ordered quinine gr. ij, with sulphate of iron gr. j, cod-liver oil, and full diet with eggs, &c. The cod-liver oil could not be taken, and set up irritability of the stomach, which with difficulty was quieted. Carbonate of ammonia, with tincture of bark, was then given, and wine and brandy as he could take them ; but the irritability of the stomach repeatedly recurred, and the prostration increased ; he sank on Oct. 28.

On Inspection.—The pleuræ were healthy, so also the lungs, with the exception of a small nodule of opaque low-organised product (tuberculous). The heart was small. The abdominal viscera were all healthy, except the supra-renal capsules ; no disease of the liver, spleen, kidneys, pancreas or intestine existed ; both supra-renal capsules were extensively diseased, and there was scarcely any healthy structure left in them. The left capsule was greatly enlarged, and infiltrated with low-organised product ; in some parts this deposit was cheesy, in others calcareous ; the enlargement extended towards the semi-lunar ganglion, and the branches of the nerves, as well as the ganglion itself, were surrounded with an unusual quantity of dense fibrous tissue. The right capsule was affected in a rather less degree, and the nerves could be traced to it more easily. On microscopical examination of the sympathetic ganglion, no alteration could be detected in the ganglion cells ; they contained a large quantity of pigment, and the deposit in the supra-renal capsules contained highly refracting granules and imperfect cell products. (HABERSHON, *Guy's Hospital Reports*, 3rd series, vol. x. p. 82.)

CASE XIX.—*Addison's Disease. Tubercle in Lungs. Disease of Tibia and Torsal Bones. Bronzing of Skin for Seven Years.*¹

William J., admitted under the care of Sir William Gull, Sept. 26, 1865.

He was first admitted under Dr. Gull's care Nov. 22, 1860. The case was then recognised as one of *Morbus Addisonii*. At that time the patient said that the darkness of the skin had been noticed *two years* before. For several months before his admission it had not increased. He had lost flesh very much; was extremely feeble; complained of pain in his limbs; at one time had sickness every morning. Sometimes his sight was dim after he first rose. He had had hæmoptysis, and cough, with puriform expectoration. The physical signs of phthisis were not decided. The face was 'of a brownish tinge,' and the lips were of a brownish hue where they touched. The upper extremities were paler. The abdomen was very dark. The legs were somewhat less dark than the thighs.

After this he was repeatedly admitted into the hospital. He had a disease of the left foot, which gave him much pain at the time. He was admitted for the last time Sept. 3, 1865. He was then very brown; the nipples especially were tinged; also the lower extremities, and particularly the legs. He was not emaciated.

Autopsy by Dr. Hilton Fagge.—The left lung was healthy, except a small cretaceous nodule. The right lung at the apex was puckered and contained chalky grains, scattered throughout its tissue. Lower down in the posterior border of the inferior lobe was small recent tubercle, which showed no tendency to break down.

Supra-renal Capsules.—They were small and contracted. The right was firmly adherent to the liver, seeming about to be embedded in its tissue. It was everywhere hard, and on section showed a quantity of fine white tissue, as well as calcareous matter. The left was so embedded in fat and attached by fibres passing through the fatty tissue, that its outline could not be defined. It also formed a hard mass, and contained calcareous matter, which, however, was mixed with a viscid fluid, contained

¹ Case 112, Appendix B.

in the interior of the capsule, and which escaped during removal of the organs.

The bones forming the left ankle-joint (the tibia and the astragalus) as well as others of the tarsal bones, were soft, and easily cut by the knife. On section they presented either a yellow (fatty) or a red appearance. None of the joints themselves were found to be in any way diseased. The ankle-joint was healthy. (*Med. Times and Gazette*, 1865, vol. ii. p. 441.)

CASE XX.—*Addison's Disease. No Discoloration of Skin.*¹

John B., aged 36, admitted into Guy's Hospital under the care of Dr. Owen Rees, April 18, died 23rd, 1866. The following history was obtained from his wife:—He is a carman to a leather-dresser. He has been married nine years. She had always regarded him as delicate, but he never complained until about six months ago, when he began to grow very feeble, and he complained of pain in his back, in his limbs, and of occasional sickness. On April 4 he was so weak that he was obliged to give up his work and take to his bed. He remained in bed for the greater part of the time until his admission into the hospital on April 18. He had been during the time constantly sick, bringing up almost everything. He had often had a cough, and this becoming worse, his wife thought he was in a consumption. She had never observed any change in the colour of his complexion. Dr. Wilks' attention was drawn to him by the sister as being very ill. It was observed that he was expectorating some purulent matter, and on listening to his chest, over the right apex, crepitation was heard, denoting an early phthisical condition. But there was not apparently enough in the state of his chest to account for his great prostration; for although he was able to converse and answer questions, his pulse at the wrist could scarcely be felt. His intellect was clear, but he was restlessly moving his head about. Dr. Wilks remarked that the condition of the patient was very much like what is seen in Addison's disease. On examination of the body, no discoloration was seen, but on the outside of the lower lip a small patch of pigment was found. Whilst he was in the hospital he frequently vomited.

¹ Case 229, Appendix B.

Autopsy by Dr. Moxon.—Body well built, high cheek bones, and aquiline nose. Long features, a slight brownish or tawny tinge of surface (not very striking), a dark patch within the mouth and lips. Face looks sunken, especially the eyes. Abdomen retracted, pretty well nourished, and has about the average covering of fat. Pleura.—Old adhesions about the apices. Lungs.—Slight induration of the apices, with a few small groups of recent tubercle in the left lung. Two small cavities, the larger at the apex; one cavity seemed of older date than the other. Right lung: all the small bronchi full of pus, but no trace of this condition in the left bronchi. Heart very small, soft, and flaccid; clot on the right side large and black. Microscope showed no fat granules in the fibres. Intestines.—Solitary glands prominent in both small and large intestines; Peyer's patches well marked. Liver, 54 ounces, apparently healthy. Spleen, 7 ounces, dark.

Supra-renal Capsules.—Right, shrunken and converted into a cheesy-looking mass. There were, however, two colours—one a light fawn-colour, the other white; scarcely any softening. Left, large and almost everywhere softened into a semi-tenacious material, like pus in colour. In one corner of the organ a small piece, which yet showed a little of the structure of the organ, and was somewhat like the right capsule in appearance and consistency. The covering of the organ was generally, although slightly, thickened and compressed. Kidneys weighed 13 ounces; large, very deep coloured, evidently highly engorged. (*Med. Times and Gazette*, 1866, vol. ii. p. 313.)

CASE XXI.—*Addison's Disease of one Supra-renal Capsule.*
*Apparently Typical Case.*¹

(ABSTRACT.)

The capsule had been sent to Dr. Murchison for exhibition at the Pathological Society by Dr. Bruce of Crimond, near Peterhead, and was accompanied by the following report of the case by Dr. Strichen:—

'R. J., working engineer, aged 27 years, consulted me in April 1863. Frame of body slight; complexion swarthy. Com-

¹ Case 114. Appendix B.

plained of a constant pain over the crest of the left ileum, a little to the left of its junction with the sacrum. Strength less than usual; in other respects did not complain. Skin was then of a dusky hue, not more than is often seen, and not such as to attract marked attention. He left this place some weeks afterwards, and was absent about a month. He returned, suffering from an attack of modified small-pox. From that he speedily recovered; but the colour of his skin now particularly drew my attention. It had become much darker, and the contrast between the colour of the cicatrices of the pox and the general tint of skin made the circumstance more marked.

‘He left this place soon afterwards. I was called upon to visit him on the 20th of March last, 1865. He had returned to his father’s house, evidently dying. He was much emaciated; appetite completely gone; stomach irritable; frequent vomiting; fits of coughing, with purulent expectoration. His skin was of a dirty blackish-brown colour, very dark about the eyes, the areolæ of the nipples, and the genitals; memory weakened. His pulse, never very quick, gradually became weaker, and was almost imperceptible some hours before death. His bowels were very constipated. His mouth was parched, so that he could with difficulty articulate, and he complained of a feeling of fulness and soreness in the throat and mouth. For a few hours before he died he had low muttering delirium. He died on the 19th of April.

‘His father informs me that his son was thrown violently on his back when shoeing a horse, four or five years ago. He dates his illness from that time. As a child, R. J. suffered from a chronic abdominal affection with ascites. He had a sister who died, while yet a child, of pulmonary consumption.’

R. J. was more than once during his illness a patient in the Edinburgh Royal Infirmary, where he was seen by Drs. Dyce Duckworth and Pye-Smith, both of whom diagnosed his case as one of Addison’s disease. He was also exhibited to the Medico-Chirurgical Society of Edinburgh as a case of Addison’s disease.¹ Dr. Duckworth took the following notes of his case in July 1864:—

‘He states that he was a strong and healthy man up to March 1862. At that time he began to complain of pain across

¹ See *Edinburgh Medical Journal*. April 1866, p. 953.

the back, which has never quite left him. He sought medical advice for this pain, and was treated with repeated blistering, but without deriving relief. In March 1863 he went from Edinburgh to Aberdeen, took small-pox there, and was laid up with it for six weeks. Continued to suffer pains in the back. In the spring of this year, 1863, he first noticed his skin to be somewhat darker than formerly, and his attention was drawn to this from the presence of light spots on the places which had been occupied by small-pox pustules. His brother states that he has observed the patient's skin becoming darker for the last three months.

'Is a fairly-nourished man. The whole skin is bronzed in various degrees of intensity. Areolæ of nipples and the genitals are the darkest parts, being of a sooty-bronzed tint. Extensor surfaces of fore-arms are darker than flexor, and the colour deepens on the hands and fingers. Nails pinkish-white. The trunk is mottled with dark spots, and a few leucopathic spots are likewise seen. These are most probably due to the variolous pustules, the white spots corresponding to parts where the derma had sloughed out. Conjunctivæ pearly and anæmic. Hair dark-brown, with a sort of metallie lustre. Tongue clean; brown pigment is deposited on each side of it, corresponding to indentations. The buccal mucous membrane is likewise pigmented in patches, and so are the palate, fauces, and uvula.'

On examination, the supra-renal capsule presented the following characters:—It was greatly enlarged, measuring three inches in length, one inch and a quarter in width, and half an inch in thickness along its convex border. It was much harder than natural, and in cutting into it all the natural tissue had disappeared, and its substance was found to be made up of two distinct materials, viz. a firm, grey, semi-translucent substance, presenting under the microscope a fibrillated structure, and enclosing masses of a soft, opaque, white substance, having at some places the consistence of cream-cheese, and at others liquifying into a puriform fluid. This opaque matter was composed of abortive cells, granular matter, and oil-globules. Nothing like pus corpuscles could be distinguished anywhere; but at several places this cheesy matter was quite gritty from the presence of calcareous deposit. The appearance and structure of this cheesy deposit resembled in every respect old tubercular deposit in the

lungs. The other supra-renal capsule was stated to be healthy. The *post-mortem* examination was conducted under rather unfavourable circumstances, and in some haste. No other organs, except the kidneys, which seemed to be healthy, were examined. (MURCHISON, *Trans. Path. Soc.*, vol. xvii. p. 396.)

CASE XXII.—*Addison's Disease. Typical Case.*¹

William A., aged 16, engaged at a druggist's, was admitted into St. Thomas's Hospital under Dr. Bristowe's care, September 30, 1867. He stated that he had enjoyed perfectly good health up to the previous Christmas, when he accidentally fell through a trap-door, and injured the lower part of his back. He injured himself, however, so slightly that he continued at his work as usual. To this accident he attributed his present illness. It seems that pain in the sacral region came on about three weeks after the accident, and has continued, off and on, though never very severely, ever since. Somewhere about this time a change began to be observed in the colour of his skin. From that time until his admission into the hospital his skin had been progressively getting darker, and he had been suffering from various other indications of ill health, which had also gradually increased. He had been getting weaker and weaker, had had to give up work very shortly after the commencement of his illness, and had for the most part kept his bed ever since; he had suffered from frequent head-aches, with attacks of nausea and sickness. His appetite had, however, been pretty good all along, and his bowels regular; he had had no cough or night sweats.

On admission he presented a general very dark-brown hue, not patchy, but varying in depth and, in some degree, in tint, in different parts. On the face the discoloration had a tinge of yellow; on the loins and buttocks (where the colour was deepest) the skin closely resembled that of a negro. A few slight scars, or marks resembling scars, were themselves paler than the surrounding skin, and presented very dark margins. He complained of some pain and tenderness in the sacral region, but there was no distinct point in which tenderness existed, and no swelling. He was manifestly very weak, and was particularly weak upon

¹ Case 10, Appendix B.

his legs, but there was no paralysis. His tongue was clean, and his bowels regular. There was no evidence whatever of heart, lung, liver, or renal disease. Pulse 96. He was thin, but far from emaciated.

On the day of admission he caught a slight cold, and for two or three days afterwards he had a little sore throat and cough, with some wheezing at the chest.

During his residence in St. Thomas's Hospital his symptoms were very much as they were stated to have been before admission. He was extremely weak, complaining especially of weakness in his legs, and being rarely able to remain up for more than a few hours a day; sometimes, however, seeming to regain a certain amount of strength for several days together, and every now and then keeping his bed entirely for a week or more. His sickness continued, but varied greatly; sometimes he was for days, and even for two or three weeks, without any feeling of nausea; at other times he suffered from attacks of sickness every day, or every day or two, and occasionally he had severe attacks, lasting for several days together. The severe attacks were always associated with great occipital head-ache; and, indeed, some degree of head-ache attended all his attacks of nausea and vomiting; his tongue was always perfectly clean; his appetite generally good (even when he was suffering from sickness); his bowels for the most part regular, and his urine normal in quantity and quality; his pulse always very small and weak, varying between 80 and 100 in the minute. After the slight attack of bronchitis on admission, he at no time had cough or other indications of pulmonary disease. The heart's sounds were quite normal.

On several occasions he had attacks in which his life was despaired of. During these he complained of severe occipital head-ache, great nausea and some sickness, extreme depression, both mental and bodily, with coldness of surface (especially of the hands and feet), and lividity of the nose. He complained also at these times of a sense of coldness, of a feeling of inability to move his legs (but without paralysis), and once or twice of pains in the thighs and calves. His pulse, too, was quicker than at other times, and scarcely perceptible. These attacks appeared to be relieved by brandy and diffusible stimulants.

Early in December he had a sharp attack of diarrhoea, which

lasted a day or two only; late in October, and again towards the latter end of January, he suffered from severe pain in micturition; occasionally he was unable to pass water in the recumbent position.

The colour of his skin increased but little in depth while in the hospital; it was thought by the sister of the ward and by others that it varied (in the face at least) occasionally. This is a point, however, in regard to which I never entirely satisfied myself. In order, however, to see whether the colour was modified by excess or deficiency of blood in the capillaries of the skin, one or two spots were treated with Richardson's ether spray. The final result was curious; the epidermis over each frozen patch gradually detaching itself from that around, contracted itself into a kind of black corrugated button, which still adhered to the central part of the patch several weeks after the freezing process, leaving a broad white ring around it, corresponding to the newly-formed epidermis. There were observed a few small, and not very distinct, brownish patches on the buccal mucous membrane.

While in the hospital he increased considerably in height. He was weighed at frequent intervals, and found to vary within narrow limits only. His weight a month after admission was 6 stones 10 pounds; at the end of November it was 6 stones 8 pounds, and it was never less than this. About the end of February he weighed 6 stones $13\frac{1}{4}$ pounds. Actually, therefore, his weight would seem to have increased while he was in the hospital, but, doubtless, relatively to his height, there was some slight diminution.

His temperature was occasionally tested, and was found to vary in the axillæ between 97.4° and 98° . His pulse was remarkably small and feeble at all times. His urine was examined both chemically and microscopically. It presented no crystalline matter or other microscopic element, even at the time when he had pain in passing it; it contained no albumen; it was, however, at times very pale, copious, and of low specific gravity.

On March 19 he was sent to the Convalescent Hospital at Walton. The journey there seems to have fatigued him very much, and he was seized immediately on reaching Walton, if not on his way there, with all those symptoms of depression, sickness, &c., which have been previously described. These symptoms

continued without intermission; and as, after remaining there five days, there was no sign of improvement, he was sent back again to St. Thomas's Hospital. He was then miserably depressed, excessively weak, with an imperceptible pulse at the wrist, congested nose, and cold extremities; suffering from frequent sickness, with inability to take food, and severe pain in the head and back. He was, however, perfectly sensible, and his tongue was, as it had been almost invariably, quite clean and moist. For a day or two he appeared to rally slightly; but on March 26 all his unfavourable symptoms became aggravated; hiccup came on; he passed a very restless night, sank gradually, and died quietly at ten on the following morning (27th).

Post-mortem Examination.—*Head.*—Brain and its membranes healthy.

Chest.—Lungs crepitant throughout, but somewhat congested and œdematous below. Pleuræ healthy, with the exception of a few old adhesions on the left side. Larynx, trachea, and bronchial tubes healthy. The heart weighed 6 ounces, but seemed healthy in all respects; there were small, pale, firm coagula in all its cavities.

Abdomen.—Peritonæum healthy. The liver weighed 33 ounces, and its vessels contained a good deal of blood. The spleen weighed 8 ounces, and was firm and healthy-looking. The kidneys weighed together 7 ounces, and were healthy. The urethra and bladder, œsophagus, stomach, intestines, and mesenteric glands, were all quite healthy. There was no appearance of disease in connection with the bones of the lower part of the spine or pelvis.

The left supra-renal capsule was plump and rounded, and evidently somewhat enlarged. It weighed 86 grains. On section it was found to present no trace of healthy structure, but consisted of a kind of tough fibroid substance, in which were imbedded lumps of cheese-like tuberculoid matter.

The right supra-renal body had more of the normal shape, but was greatly atrophied, weighing 16 grains only. It contained, like the other one, a few cheesy lumps, but consisted in a great measure of a tough, slightly translucent fibroid substance. This capsule also presented no traces of healthy structure. (BRISTOWE, *Trans. Path. Soc.*, vol. xix. p. 410.)

CASE XXIII.—*Addison's Disease. Typical Case.*¹

E. A., aged 31, first came under observation in October 1870, when she appeared to be suffering from symptoms of great general debility, with a certain sallowness of the face, but with no marked discoloration of the skin. She dated her illness from the beginning of the same year. In the early part of December she again presented herself, with the same complaint of great weakness. Her face had now the look of a person sunburnt; the skin on the back of the neck and shoulders, in the folds of the axillæ, over the elbows and outer aspect of the fore-arms, being browned as if by exposure to the sun. In the mouth two spots of pigment were detected on the buccal mucous membrane. The pulse was very feeble. The appetite was reported to be very bad, but there had been no sickness. She was warned of the serious nature of her disease, and advised to come into the Radcliff Infirmary, which she refused to do. On January 11, 1871, she came staggering into my out-patient room, and sank down moaning in a chair, with the body bent almost double, the feet and hands cold, and the pulse imperceptible. She was at once carried to bed, and slowly recovered. On visiting her the next morning, I found her tossing restlessly about in bed, yawning frequently, and indisposed to answer questions. A peculiarly fetid odour came from her breath. The skin was on the whole darker than when the last note was made. On the forehead were some distinct pigment patches, with irregular outline, gradually fading off into the normal skin, and exactly recalling what is commonly seen in chronic diseases of the uterus. The lower lip was streaked with a dark line. On the gum, beneath the right lower outer incisor, was a large spot of pigment. On the buccal mucous membrane were several spots of the same kind, some round, some stellate. The face and neck were dingy brown in colour, the sclerotis being quite white. The areolæ round the nipples were dark, and there was one black spot on the right nipple. On the lower part of the abdomen, extending down to the groins, were numerous streaks and spots of pigment, some of the latter stellate and others triangular in shape. Over the

¹ Case 82, Appendix B.

patellæ and front of the thighs, in their lower half, was a yellowish-brown staining. On the neck, arms, and thighs there were also small deep black spots of various sizes, scattered over the brown skin, looking somewhat as if an inky pen had been spluttered over the part. The hair was peculiarly rough and coarse. Pulse scarcely perceptible. Temperature in axilla 97.6° Fabr. Hands and feet cold and dusky. Constant complaint was made of severe pains at the pit of the stomach and of aching in the legs. She lingered on till January 16. Two days before death she vomited and retched frequently, and for the last day of her life she lay in an unconscious state.

Autopsy.—The thorax and abdomen were covered with a thick layer of subcutaneous fat. The muscles were ruddy and well nourished. Both lungs were everywhere bound to the chest-wall by old and tough adhesions. In the left apex was a hard mass the size of a walnut, composed of tough cicatrix tissue, with two or three chalky deposits. Two other similar masses were present in the same lung, one in the upper and the other in the lower lobe. In the right apex was a smaller mass of exactly the same kind. In the abdomen the great omentum was adherent in its upper half to the abdominal wall. The liver was everywhere firmly fixed to adjacent parts by old and tough false membranes. These adhesions extended from the left lobe across to the spleen, which was similarly bound to the diaphragm. The mesenteric glands were enlarged, this glandular hypertrophy being especially marked in the neighbourhood of the supra-renal capsules. The peritonæum covering the intestines was everywhere healthy. The kidneys were pale and their capsules in parts adherent, but there was no interstitial nor other disease. There was no evidence of tubercle in any of the above-mentioned parts, nor any vertebral disease. The supra-renal capsules were both enlarged—the left more so than the right—hard and nodulated; their surfaces covered with much thick fibrous tissue. The right was at once sliced, and found to have a tough fibrous section, with a dull white surface, dotted over with small bright yellow spots. The white tissue was particularly abundant in the nodular prominences with which the organ was beset. The yellow spots were of the consistence of cheese, and could in some parts be shelled out with the point of a knife. The left capsule was removed with a part of

the diaphragm, the aorta, and the semilunar ganglion for the purpose of dissection. Considerable difficulty was experienced in preparing the branches of the supra-renal plexus. The adhesions surrounding the liver and spleen extended down among the plexuses, and made their dissection unusually troublesome. Not only was this the case with the supra-renal plexus, but the semilunar ganglion and great splanchnic nerve were similarly beset with thick connective-tissue. It is also worthy of notice that just at the upper and inner border of the capsule, the very point where the bundle of nerves enters the organ, was a large nodule projecting from the surface into which the nerves directly passed. The left capsule was found on section to be converted into a moderately firm substance, in parts whitish, in parts of a dirty-brown colour, dotted and marked here and there with small spots and streaks, which in the recent specimen had a yellowish tint.

Sections taken from the right capsule, after hardening in chromic acid, showed the following microscopical characters:—

1. Fibrous tissue permeating the organ in the form of bands and displacing its natural structures, especially prevalent towards its surface.
2. Crowds of small cells and nuclei—the former resembling, but rather smaller than, lymph-cells, and containing for the most part one nucleus which nearly filled the cell, the latter round or oval—lying heaped together in a delicate matrix of connective-tissue; not arranged like miliary tubercle in definite groups or clusters, but irregularly distributed in certain parts or districts of the organ, and seemingly more abundant in the deeper-seated parts than towards its surface. There was no evidence of any further development of this tissue into fibrous tissue, but the two seemed to be distinct, and each in its turn to undergo a retrograde or fatty change.
3. Fatty granules, some in circular clusters corresponding to the round yellow spots seen with the naked eye, others in large streaks or patches. The former plan of arrangement was chiefly met with in those parts where crowded cells and nuclei predominated; the latter showed itself in the more strictly fibrous parts of the disease. A thin section made right through the organ from the cortex towards what should be the medulla, and examined with a low power, showed well the curious intermingling of the above changes, and how the tissues were, so to speak, blurred and disfigured by the

opaque patches of fatty degeneration. No trace of healthy structure could anywhere be detected. (TUCKWELL, *St. Bartholomew's Hospital Reports*, vol. vii. p. 73.)

CASE XXIV.—*Addison's Disease. Typical Case.*¹

Mr. Sayle, surgeon, of Lynn, in the commencement of 1847, was the subject of right lumbar abscess, and was in a most precarious state of health. At the end of May he was able to leave for Downham, his native neighbourhood, where he remained six weeks, when he left for Margate, seeing *en route* Sir B. C. Brodie. Here he resided until September, when he returned to Lynn, 'fat, stout, and in good health,' shunning, however, any walking exercise for the next eight or nine months, the lumbar abscess continuing to discharge during that time. From this period the abscess became soundly healed, and his health so established that, in addition to his professional duties, he joined warmly and actively in public business, and for three or four seasons entered into the pleasures of shooting.

In November 1854 a sudden and marked change in the complexion was observed; this had been preceded by occasional periods of distressing *ennui* and constipation, although in general he was extremely hearty, and in his usual light-hearted spirits. The change in his aspect daily became more striking, and now followed violent palpitation, distressing periods of depression, and sense of sinking, troublesome vomitings, and 'dreadful hiccups,' numbness of fingers, &c., which continued until March 1855, when he left for Portsmouth. From Portsmouth, certainly not worse, but dead with *ennui*, he returned, after a short stay, again to Lynn, where he remained until the following Christmas, 'ailing, and occasionally very ill,' when he again became worse, and caused considerable renewed anxiety, until April 1856. He then improved, and in somewhat better health started for Hastings. Here he resided for upwards of two months, regaining his health wonderfully; having had but one attack of his 'frightfully depressing symptoms,' and that his worst, during the first week's residence.

¹ Case 15, Appendix B.

After leaving Hastings, a tour of a few weeks was made among his friends, 'who were astonished at observing him, in spite of his singular look,' in so good a state of health. He then returned to Lynn and resumed his professional duties, and when not occupied with public business he amused himself with gardening or genealogical researches. At this period he was elected Coroner for West Norfolk. In spite of his pinched look and peculiarly bronzed countenance, Mr. Sayle lately had quite relieved his friends of further anxiety on the score of his ultimate recovery, though at times he had a breathless manner of address, and suffered occasionally from annoying hiccup and fits of depression, which were always aggravated when following any great exertion in public business.

A fortnight prior to his death Mr. Sayle took a severe cold on returning a long distance from an inquest. From this, however, though looking very haggard and ill, he was recovering, when he again exposed himself, contrary to his habit, in an open vehicle, and presided at another inquest five miles distant from Lynn. On returning home he felt 'shivering and unwell.' This was on April 3; he was attended by Mr. Coulcher until the 5th, when Dr. Cotton was also consulted, and found him suffering from prostration and frequent sighing; pulse weak, 120 to 130; low fever. He complained of his throat and windpipe; had a hoarse, painful, occasional cough, and expectorated a quantity of greenish, gelatinous phlegm. The fauces were of a pink hue, and the stethoscope indicated a mucous râle confined to the larynx and trachea. With these other symptoms he had return of hiccup. On the morning of the 7th he was very desponding, and suffered from extreme prostration. The intellect was clear, but there was slight wandering when dozing, and he sank quietly in the afternoon.

Post-mortem Examination.—The surface of the body was of a dusky yellowish bronze tint, darker on the face, neck, chest, front of thighs, and back of arms and hands, and interspersed with several dark brown freckles and blackish mole-spots. The scrotum, &c., and the areolæ around the nipples, were of a deep sooty colour. A prominent cicatrix was observed near the spine in the right loin. The supra-renal capsules were both very massive and firmly adherent. On removing the right, with its corresponding kidney, a portion of the liver with which it was con-

nected was torn off; the adhesions posteriorly at the seat of the former abscess were very firm; a whitish fibrous-looking, obliterated sinus, was afterwards found proceeding upwards from the cicatrix to the site of the structures in which the supra-renal body was embedded. On cutting through the right supra-renal mass, the surface of the capsular body was observed of a dark pinkish colour, and apparently 'puckered' at different points; throughout it was studded with encysted collections of yellow tubercular matter of cheesy consistence, varying in size from a millet-seed to a large horse-bean. Some pus, on pressure, could be squeezed out of the smaller ones; but the cysts, with their contents, were apparently in a quiescent state, and could easily be turned out. The left supra-renal capsule was larger than the right, and more regular and plump in outline; a section gave nearly similar appearances, though from its more vividly pink colour and less firm cystic contents the changes were considered of more recent origin. (COTTON, *Medical Times and Gazette*, vol. xxxvi. p. 33.)

CASE XXV.—*Addison's Disease. Typical Case.*¹

(ABSTRACT.)

James —, aged 33, pattern-designer, came under the care of Dr. Finlayson in October 1870. Had been strong and active, and had enjoyed good health until his last illness, which commenced in April 1870, and lasted nearly a year. For some months previously he had been seriously depressed by family cares and anxieties. The first symptoms were cold and an unusual feeling of weakness, followed in a month or two by yellowish-brown discoloration of the face and backs of hands; the pigmentation was limited to the exposed parts. Six months later *shiveriness* and severe pain in the left sacral region supervened, with shooting pains in the course of the crest of the ilcum; these pains gradually diminished, and left him in the course of a month, during which he rested from work. He then returned to work for six weeks, at the end of which there was a marked failure

¹ Case 22, Appendix B.

in his appetite and strength, and a deeper discoloration of face and hands. On December 23 he took to his bed on account of feebleness. From this time he had occasional spontaneous vomiting without nausea. He again improved in strength, and worked short hours from January 3 to February 19, but during this period he became breathless on exertion, was troubled with hiccup and occasional giddiness on rising. A slight brown discoloration appeared in the axillæ, on the inside of thighs, and on dorsum of feet, and small round spots were also now seen on the lips and mucous membrane of the mouth. On March 2 he returned from a fortnight's stay in the country much worse, and took to bed. Complained much of giddiness, with mistiness, amounting sometimes to blindness, on sitting up. Pulse very feeble, first heart sound very faint. Had pain in face from cold, followed by discharge of blood and pus from the right ear. He became very feeble and drowsy, felt faint after a loose motion, and was much troubled with hiccup. His mind became weak and wandering, and he died quietly on March 6.

Post-mortem Examination.—Sub-cutaneous fat at least moderately abundant. Heart soft; pale firm clots in both ventricles. Lungs slightly adherent at apices. Several distinct cheesy patches, generally about the size of horse-beans, near the surface of the right lung. More deposit in left lung, and at one point softening had produced a small cavity. Rest of lung tissue healthy; no tubercular granulations in either lung. Spleen, liver, and left kidney soft. Right kidney and pancreas normal. Brain, stomach, and intestines not examined.

Right supra-renal capsule weighed two drachms and a half, and was scarcely above the normal size. On section, no distinction between cortical and central parts. The more central part was generally of an opaque white colour, with several opaque yellow spots scattered throughout. Greater part of the tissue and all the periphery grey-coloured and somewhat transparent. Under the microscope the grey parts were seen to be almost entirely composed of innumerable round cells, with a few spindle-shaped elements, and now and then gigantic cells. Paler central parts in an advanced stage of fatty degeneration; in fresh section nothing but fatty granules, after hardening in alcohol, a nearly structureless granular mass. Gradual transition from infiltrated external part to fatty internal.

The left supra-renal capsule was very much larger than the right, and weighed one ounce and three-quarters. On section it was seen to be in great part made up of a yellow cheesy opaque mass, divided chiefly into two portions, one about the size of a flattened walnut at one end of the capsule, and the other about the size of a hazel-nut at the other end. These masses were in some parts of pretty firm consistence, but presented central and peripheral collections of degenerate pus. On microscopic section a thin layer was seen just at the periphery of the organ infiltrated with round cells, as in a much larger area of the right capsule. The cheesy central mass showed fatty degeneration, the fatty parts being arranged in an irregular reticulated network, composed chiefly of oil granules, but interspersed in which were several large brownish granular bodies, which presented some resemblance to the granular bodies that form the main constituents of the normal capsule; these bodies were irregularly scattered, and only in rare cases showed a slight approach to the arrangement in rows.

The disease was obviously much more recent in the right than in the left capsule. The primary process would seem to be extreme infiltration of the entire tissue of the capsules with round cells, which subsequently undergo fatty degeneration. Such an infiltration might be the result of chronic inflammation. On the other hand, it might be the result of a local tuberculosis, the objection to this being that the round cells are not, as a rule, aggregated into the form of distinct miliary nodules, but assume the form of a general infiltration. While this is the case, it must, however, be added, that in many cases there is a distinct approach to this mode of grouping; nodules of about one-ninetieth of an inch in diameter being detected in considerable abundance. These nodules present all the characters usually ascribed to tubercular nodules, being composed chiefly of round corpuseles, arranged so as to form a distinct object. In the centre of these nodules were found in almost every case very large cells of an average diameter of about 1-300th of an inch. (FINLAYSON, *Glasgow Medical Journal*, August 1871, p. 433.)

CASE XXVI.—*Addison's Disease. Typical Case. Discoloration of Skin developed long before Constitutional Symptoms.*¹

(ABSTRACT.)

Mrs. B., aged 40, a clergyman's wife, first observed, about eight years before her last illness, a dark-coloured spot on her forehead, which gradually increased in size, whilst other parts of her head, face, and neck, became similarly affected. At that time her health was pretty good, though she had suffered from some internal complaints in consequence of having had to leap from the top of a stage-coach some years previously. Eight months before Dr. Munro saw her, whilst undergoing great mental anxiety and bodily fatigue in attendance on her husband, who was seriously ill, she noticed that the discoloration of her skin became much deeper and more general.

The patient was much emaciated, and in colour nearly resembled a Lascar. She felt great weakness, sinking, and prostration, increased by an attack of diarrhœa. She was much troubled by cough, to which she had been subject since she had had the measles in childhood. Pulse 100, small and compressible; very little appetite; no pain. Catamenia and bowels regular; urine normal. She continued to sink, and died after she had been under observation nine days, remaining sensible to the last.

Post-mortem Examination.—The body was greatly emaciated, and the skin was universally of a dark bronze hue; many patches of a darker brown colour were conspicuous, particularly on the sides and back of the neck, over the knees and elbow-joints, and round the mouth. Both lungs were adherent with some tuberculous deposits in the apices. The abdominal organs were generally adherent, but the only seats of marked morbid change were the supra-renal capsules and the mucous membrane of the alimentary canal.

The right supra-renal capsule was of an irregular, tuberculated form, about four times the normal size, and firmly adherent to the vena cava, and to the substance of the liver. The sympathetic nerves on the right side from the lesser splanchnic were greatly increased in size, and so were also some of the branches, as well as the ganglia of the solar plexus of nerves on that side, and in

¹ Case 60, Appendix B.

contact with the morbid organ. The texture of these nervous parts was of a rosy hue, as if under the influence of vascular excitement. No other change could be observed in them. The left capsule was an oblong rectangular body, preserving somewhat of its original shape and relations to surrounding parts; a similar, but less vascular, condition of the nerves was apparent on this side also. In the stomach, the solitary gastric glands were remarkably prominent, whilst the mucous membrane generally was atrophic. The tubular glands of the mucous membrane were almost entirely gone, and their place was supplied by a granular amorphous material. (MONRO, *Assoc. Med. Journ.*, 1856, p. 848.)

CASE XXVII.—*Addison's Disease. Typical Case.*¹

(ABSTRACT.)

A tradesman's apprentice, aged 16, was admitted into the Rostock Hospital on Oct. 5, 1868, under the care of Prof. Thierfelder.

Patient was stated to have been strong and healthy until the previous June, when he had suddenly, without apparent cause, begun to suffer from debility, dyspnoea, and palpitation. Three weeks' treatment in an infirmary had relieved these symptoms and enabled him to return to work, but loss of appetite and frequent vomiting had soon come on, and a long fainting fit had been followed by transitory blindness, difficulty of speech, and paralytic affection of the right arm and leg. These symptoms of cerebral disturbance, which were attributed to embolism, had quite passed away, but the patient had remained mostly in bed up to the time of his admission, suffering from great debility, loss of appetite, feeling of oppression in the epigastrium, occasional bilious vomiting and constipation. His guardian said that from almost the beginning of his illness the boy's complexion had become darker, and 'liver-spots' had been noticed on his skin.

On admission, the whole skin was of a dirty-brown colour, most intense on the face, neck, hands, and dorsum of feet, and also in the folds of the axillæ, in the hypogastric region, and round the knee-pans. The areolæ of the nipples and the navel

¹ Case 103, Appendix B.

were not darker than other parts. On the dark brown ground were two kinds of pigment-spots: blackish nævus-like spots, from the size of a pin's head to that of a lentil, and other, much more numerous, spots, in size, colour, and indistinct margins resembling dark freckles; both kinds of spots were chiefly on the face, neck, and arms. There were some deep smoke-coloured patches on various parts of the body and limbs. On the inner surface of the lips, on the free margin of the gums, and on the right half of the hard palate, there were yellow-brown deposits of pigment.

This marked discoloration of the skin, together with the muscular debility, gastric ailments, small, compressible pulse, and pain on pressure in the epigastrium and lumbar region, led to the diagnosis of Addison's disease.

The further course of the illness, until just before the close, differed little from that in many previously recorded cases. The gastric symptoms caused most suffering to the patient, and want of appetite, fulness in the epigastrium, flatulence and bad taste in the mouth, were daily complaints. There was frequent nausea, but after the first few days no actual vomiting until shortly before his death. The bowels were somewhat confined. The pulse was always quick, small, and compressible, and was much accelerated by the slightest exertion. On the other hand, the average of the respirations was very low. Towards the end of November the patient began to improve, and in December and part of January was strong enough to get up for some hours daily. During this period of improvement it was noticed that some of the nævus-like spots on his face became of a lighter colour, but without quite disappearing. No general paling of the skin, however, and no formation of new pigment patches, was observed during his residence in the hospital.

On Jan. 22 the patient had a sudden shivering fit followed by fever, whereas until then his temperature had been as a rule below the normal. These attacks recurred daily and increased in severity, the temperature varying from 36.8° to 40.2° (Cent.). Head-aches, vomiting, and coma supervened, and the patient died on Jan. 26, with a temperature of 40.6° (Cent.). Respiration 45, pulse too small and quick to count.

Post-mortem Examination.—Muscles small, subcutaneous fat thick. Brain substance pale, œdematous. A few old adhesions,

and one cretaceous nodule in lungs. Yellow clots in left auricle and right side of heart. Liver full of blood. Spleen enlarged, of a dark purple colour. Kidneys normal. Pyloric portion of stomach mammillated. Brunner's glands and solitary glands enlarged. Peyer's patches mostly very prominent.

Both supra-renal capsules were at least three times the normal size, with irregular knobs, and exceedingly hard to the touch; their fibrous envelopes much thickened. On section they were seen to consist of separate nodules, surrounded by thick connective-tissue fibres, and partly converted into cheesy masses. Under the microscope some portions of the capsules consisted only of fibrillar connective-tissue, enclosing spindle-shaped cells, showing no traces of the normal gland-tissue. In other parts the connective-tissue was scanty, and many round or irregular cells, with nuclei, were embedded in it, resembling the normal medulla-cells. Here and there in the central portions were cells three times the size of the others, which probably represent the sympathetic ganglia-cells of the supra-renal capsules.

The nerves of the solar plexus, as also those of the semilunar ganglia, and the nerve-branches going to the supra-renal capsules, were surrounded by an envelope of hard connective-tissue. Some nerves of the solar plexus, at their place of entrance into the corresponding semilunar ganglion, presented ampulla-shaped enlargements. Microscopical examination showed most of the ganglia-cells to be quite normal, with a distinct nucleus; a few only were partly filled with fat-molecules. Remak's fibres and the true nerve-fibres in the ganglia presented nothing abnormal. On the other hand the increase of connective-tissue in the ganglia was most striking, when compared with the semilunar ganglion from a patient who had not died of Addison's disease. The connective-tissue was fibrillar, enclosing spindle-shaped cells. The ampulla-like enlargements of the nerves, before their entrance into the semilunar ganglia, were seen under the microscope to be themselves small ganglia, with well-formed ganglia-cells, between which the hyperplasia of the connective-tissue was as distinctly seen as in the semilunar ganglia.

The pigmentation of the skin corresponded exactly with the description recorded on admission. Microscopical examination showed that it was produced by a deposit of yellow-brown pigment, most abundant in the cells of the Rete Malpighii, and

rendering their nuclei mostly invisible. In the lower layers of cells the pigment was more scanty, and ceased altogether in the epidermis cells. At the nævus-like spots the pigment was dark-brown, most intense in the cells immediately surrounding the papillæ, and in the depressions between them. The pigmentation was, however, not entirely limited to the rete mucosum, but extended here and there into the papillæ themselves, and into the horizontal layers of the cutis. The pigment in the papillæ was mostly enclosed in cells, with a few larger heaps of free pigment. In the cutis beneath the nævus-like spots the pigment was partly in spindle-shaped, partly in branching cells. (WOLFF, *Berlin Klin. Wochenschr.*, 1869, p. 174.)

CASE XXVIII.—*Addison's Disease, without Discoloration of Skin.*¹

(ABSTRACT.)

J. E., tailor, aged 38, was admitted into the Amsterdam Hospital on May 12, 1869, under the care of Prof. van Geuns.

Patient stated that he had always enjoyed good health until the previous September, when he had caught cold and had suffered for several weeks from quartan fever. From that time his strength had begun to fail, he had kept the house for some months, complaining of general debility and mental depression, and during the last three weeks before his admission he had experienced great weakness in the limbs and walked very unsteadily.

On admission his skin was everywhere of normal colour, his eyes were dull and sunken, his voice was tremulous and his gait unsteady; he complained of lassitude, pains in the back, and oppression on the chest. Pulse small and soft; appetite moderate; mind depressed; nights sleepless. Bowels confined; urine of high specific gravity, free from sugar and albumen.

May 16.—Patient was anxious and excited, complaining of tension and pain in the gastric region.

May 17.—Nervous symptoms the same, but increased towards mid-day. Pulse rapid, small and thready; respiration thick, irregular, and laborious; great restlessness, anxiety and trembling;

¹ Case 226, Appendix B.

distressing pains in the præcordial region ; vomiting of greenish, bilious matter ; bowels not open for some days past.

May 18.—Face covered with cold sweat ; breathing difficult ; tremulous movements of upper limbs ; complains of pain and tension in the gastric region. Pulse 132, small, thready, scarcely to be felt. Temperature had increased during the last two days from 38·6° to 43° (Cent.). Extreme restlessness, collapse and death.

Post-mortem Examination.—Body fairly nourished ; skin and mucous membrane everywhere of normal colour. Muscles dark-red, layer of fat beneath skin deep yellow.

Nothing abnormal of any importance in the substance of brain, lungs, heart, liver, spleen, or kidneys.

Some recent ecchymoses on the mucous membrane of the large curvature of the stomach, and scanty mucous serum in the stomach, duodenum and intestines. Brunner's glands slightly enlarged, and solitary glands, in the upper part of the jejunum and lower part of the ileum, much enlarged. Mesenteric glands much enlarged. On microscopical examination no change in the normal gland elements.

Both supra-renal capsules were converted into hard nodular masses, embedded in thick fatty tissue ; their fibrous envelopes were greatly thickened. On section both organs consisted of a firm cartilaginous, greyish-white, homogeneous substance, in which were embedded numerous yellow masses of irregular shapes, varying from the size of a barley-corn to that of a pea ; some solid, others softened, or of a friable consistence. These masses could for the most part be easily enucleated from the cartilaginous matrix. There remained no trace of any distinction between cortex and medulla.

The nerves of the celiac plexus, especially both semilunar ganglia, were enclosed in hard connective-tissue, and the latter were much reddened both on surface and on section. The separate ganglia-cells were so filled with granular pigment as almost entirely to hide the nucleus. No changes were discoverable in the enclosed nerve-fibres ; but, between them, large numbers of oval and spindle-shaped cells, with distinct nuclei, were embedded in homogeneous or slightly fibrillar connective-tissue, like that of the capsules and fibrous envelopes. There was considerable thickening of the connective-tissue sheaths of the nerve-fibres

going off from the ganglia, and in these also many spindle-shaped cells were embedded.

On opening the spinal canal, the dura mater in the lumbar region was seen to be of a deep rose-colour. The vessels of the pia mater and of the dura mater were much congested, even in their smallest branches, and the nerve-substance in the same region was reddened and visibly softened. The nerve-fibres of the cauda equina were thickened and reddened; the blood-vessels much dilated. (HERTZ, *Virchow's Archiv f. Pathol. Anat. &c.*, vol. xlix. p. 4.)

CASE XXIX.—*Addison's Disease. Typical Case.*¹

A man, aged 43, who had always previously been strong and healthy, but had been exposed to all weathers and to much over-exertion, began to suffer, in March, 1869, from pain in the stomach and vomiting of mucous fluids after eating. These symptoms frequently recurred, but disappeared at the end of a month, when mucous diarrhoea came on, and about the same time the colour of his skin was observed to darken. During the summer he lost flesh, and had a constant feeling of sinking at the stomach, with a tendency to fainting and pains in both hypochondria. In September he was admitted into the hospital, but was discharged at the end of nine days, much relieved. During the winter he became much worse, and was re-admitted in February 1870.

On admission the whole skin was mulatto-coloured, the darkest parts being on the face and hands, the nipples, axillæ, and inguinal regions, the navel, sexual parts, and inner surfaces of the thighs. There was a blackish stripe on the middle of the tongue, and two similar stripes on the sides of the arch of the palate. The pulse was very small and weak; the heart's impulse could not be felt. Addison's disease was diagnosed. The patient's skin continued to darken, he suffered from pains in the abdomen, loins, and hypochondria, from attacks of fever (38° to 39° Cent.), relieved by diarrhoea, from nausea, and antipathy to food, and died on May 4 in a fit of violent convulsive excitement.

¹ Case 12, Appendix B.

Post-mortem Examination.—Body fairly well nourished, thick layer of sub-cutaneous fat. Skin somewhat less dark than it had been during life. A few obsolete tubercles in apices of lungs. Heart normal. No changes of importance in liver, spleen, or kidneys. Chronic catarrh of stomach. Solitary glands and Peyer's patches enlarged.

The left supra-renal capsule was double the size of the right one. Both were hardened and cartilaginous, shining white externally, and embedded in thick layers of fatty cellular tissue. On section the parenchyma consisted of a yellow semi-solid mass, enclosed in the thickened fibrous capsule; it did not grate under the knife. The central part was seen under the microscope to be made up of fat granules and globules in a fibrous network, whilst the envelope was formed of thick, coarse, fibrous tissue, of the character of connective-tissue. The lymphatic glands in the neck, breast, abdomen, groins, &c., were enlarged and hardened, showing on section a thickened capsule and yellow or reddish gland-tissue, with increased development of blood-vessels and of connective-tissue, in the meshes of which fat-masses were enclosed.

The sympathetic nervous system presented striking alterations. The semilunar ganglia were considerably enlarged, especially the left one; the nerve-fibres forming the solar plexus were likewise thickened, and, under the microscope, the ganglia-cells, particularly on the left side, were more granular and opaque than usual, with no trace of nucleus; the neurilemma was hypertrophied.

Professor Tigri also found the whole sympathetic nervous system reddened and swollen; both upper cervical ganglia, especially the left one, enlarged, more cylindrical; the neurilemma hypertrophic, the enclosed nerve-marrow very small.

Under the microscope both ganglia and nerve-cords showed the remains of old and recent hæmorrhages, consisting of numerous yellow granular corpuscles, &c., of small, roundish, or irregular bright red molecules, together with some still normal red blood-corpuscles; the smallest blood-vessels showed aneurismal and varicose dilatations; the nerve-sheaths were hypertrophied. (BURRESI, *Meissner. Schmidt's Jahrbuch*, vol. cliv. p. 39.)

CASE XXX.—*Addison's Disease: Typical Case.*¹

(ABSTRACT.)

H. S., bricklayer, aged 33, was admitted into the Elberfeld Hospital on July 10, 1868.

Had been strong and healthy in early years, but seven years before admission had suffered from intermittent fever, and since then from frequent diarrhœa, and also from a feeling of cold, especially in his hands and feet, and from numbness in his fingers, so that a pin could be stuck into them without giving him pain. He had, however, gone through the whole Austro-German campaign of 1866, and it was only after labouring under a very hot sun in the summer of 1867 that he had first begun to suffer from debility and headaches. He had remarked a little later that his face and hands were becoming discoloured, which his friends attributed to sun-burning, but the discoloration had spread to other parts covered by his clothes. He had also felt about the same time a dull pain in the region of the left kidney, which was enhanced by pressure. The debility had gradually increased till he had been unable to continue his work, and had latterly been confined to bed.

On admission, the uniform grey discoloration of the face contrasted strongly with the pearl-white hue of the conjunctivæ. The neck and upper part of the chest were of the same colour as the face, but here the discoloration ended in an irregular line, only a few grey points projecting beyond the nipples; both hands were of the same grey colour, but the discoloration ceased rather abruptly at the wrists. It was visible in a less marked degree in the bend of both thighs, from which some dark grey lines extended up the abdomen and down the thighs. The mucous membranes were very pale. Patient only complained of prostration; had no fever, fair appetite, and scarcely any remains of the pain in the left lumbar region. Bowels loose; urine light-coloured, normal.

After some weeks of tonic treatment, with good nourishment, patient was discharged, at his own desire, much relieved. The

¹ Case 50, Appendix B.

discoloration had made no progress. His strength soon failed again, but by the use of the same means he rallied once more, so far as to be able to take a walk daily. On November 7, without any apparent cause, he was seized with a shivering fit, followed by high fever, and accompanied by shooting pains in the region of the right kidney, which were rendered more intense by pressure. Pulse small and quick; great thirst. After some days the pains became less intense, but the fever persisted; the patient sank from day to day, and died in collapse on November 20.

Post-mortem Examination.—Grey-brown discoloration, as described; the other parts of the body of a dirty-white hue. No emaciation; muscles on section deep red; layer of fat on thorax moderate, on abdomen thick. Some calcified tubercles in upper lobe of left lung. Right lung, heart, liver, spleen, and kidneys normal.

The left supra-renal capsule was shrivelled, and its tissue degenerated; there was no distinction between cortex and medulla, and here and there were grey deposits of the size of barley-corns.

The capsule of the right supra-renal body was thickened, cartilaginous, and adherent by its upper part to the liver, into which it seemed to have grown. On section of the capsule a quantity of whitish-yellow liquid pus flowed out. The tissue of the organ was entirely destroyed, and converted into a uniform grey mass, resembling tubercle.

The microscopical examination made by Professor Rindfleisch showed tuberculosis of the supra-renal capsules. 'The cheesy nodules,' he stated, 'had destroyed the greatest part of the organs; nevertheless, at a single spot there remained some of the normal tissue, so little changed that the small cellular infiltration of the septa, with which the process begins, could be distinctly seen. The capsule was enormously thickened and attached to neighbouring parts by old adhesions; in these adhesions we succeeded in verifying the presence of two largish nerve-trunks, the fibres of which were in a state of partial fatty degeneration.' (KUHLMANN, *Berlin, Klin. Wochenschr.*, 1869, p. 481.)

CASE XXXI.—*Addison's Disease. Typical Case.*¹

(ABSTRACT.)

A married woman, without children, who had always enjoyed good health, suddenly became anæmic and began to lose flesh. She remarked at the same time that the skin of her face and hands was growing darker. In January 1859, and in the summer of 1860, she had had intercurrent attacks of jaundice, which had passed off entirely without producing any effects on the pigmentation of her skin.

On her admission in March 1861, patient presented a general bronze colour of skin, with deeper black spots on the face, lips, tongue, and upper arms, which latter were otherwise, like the thighs, of normal colour. The finger-tips and the dorsal surfaces of the hands were almost black; the conjunctivæ of a transparent bluish-white colour. Skin cool; digestive functions deranged; bowels irregular; menstruation intermitting.

After a short period of improvement, pain in the abdomen, with diarrhœa, and constant lumbar pains supervened, and the debility and emaciation rapidly increased. She had been three months under treatment. She was suddenly seized with vomiting and syncope, and died in convulsions.

Post-mortem Examination.—Discoloration of skin, as already described. In the apices of the lungs some obsolete cretaceous tubercles, surrounded by recent deposits. The peritonæum presented on its free surfaces some dark swellings and pigmentations, such as are commonly left by hæmorrhages. There was purulent catarrh of the uterus, which was adherent to surrounding parts, but all the other organs were normal, excepting the supra-renal capsules.

Both supra-renal capsules were in a state of complete degeneration, by means of chronic tuberculosis. Tubercles in the most various stages were found embedded in a fibrous stroma, whilst the normal tissue and bloodvessels had totally disappeared. Microscopical examination showed, moreover, atrophy of the sympathetic and of the solar plexus, with almost entire disappearance of the medullary cells, and brown pigmentation of the

¹ Case 86. Appendix B.

ganglia-cells, in which the nuelei could only be distinguished by their corpuseles.—(A. VAN ANDEL, *Meissner. Schmidt's Jahrbuch*, vol. cxlii. p. 114.)

CASE XXXII.—*Addison's Disease. Angular Curvature of Spine.*¹

A crooked, lump-backed shopman, aged 47, was admitted into the Königsberg Hospital February 2, 1867, under the care of Professor Leyden.

The patient, who was of sedentary habits and given to drinking, had been suffering for nearly a year from gastric and rheumatic complaints. His skin had also, at the beginning of his illness, taken first an ash-grey, and then a yellow hue, and had from that time grown gradually darker.

On admission he complained merely of rheumatic pains in the right arm, and, beyond great emaciation and intense bronze discoloration of the face and whole body, there were no signs of disease about him. His condition remained unchanged until February 9, when he was seized with repeated shiverings. On the following day there was no rise of temperature, numerous liquid stools were unconsciously passed, and death took place in profound collapse.

Post-mortem Examination.—Brown atrophy of the heart; some fatty degeneration of liver; a few small ulcers in the stomach. No changes of importance in any other organs of the body, with the exception of the supra-renal capsules.

Both these organs were hard and nodular, but the right capsule was double the size of the left. On section, the left capsule was seen to be largely composed of a number of roundish cheesy nodules of various sizes embedded in soft whitish-grey tissue. The appearance of the right capsule was somewhat different; the peripheral portion of the anterior half being chiefly occupied by a tough cheesy layer, part of which had crumbled down, whilst in the posterior half were several various-sized nodules. The cheesy parts, when fresh, were of a pale greenish-yellow colour, and showed on close examination dense opaque striæ. The intervening tissue was of a reddish-grey colour and moist consistence, and knotty on section. The separate knots

¹ Case 124, Appendix B.

had mostly cheesy centres, with a reddish-grey semi-transparent periphery.

Microscopical examination showed scarcely a trace of the normal parenchyma of the supra-renal capsules. The tissue enclosing the cheesy masses consisted partly of fibrous connective-tissue studded with fat-granules, and partly of small round granular cells, between which ran rows of large spindle-shaped cells in layers. In the central parts of the capsules were numerous large round bodies filled with brown molecules, exactly resembling the ganglia-cells hereafter described, and some of them showing a distinct nucleus.

The semilunar ganglia were of normal size, of greyish-red colour, and of rather soft consistence, and were embedded in a thick mass of fatty connective-tissue.

On microscopical examination it was seen that the whole of the ganglia-cells were almost entirely filled with brown molecules, very few of them distinctly showing a nucleus. After treatment with acetic acid, the long oval nuclei proper to Remak's fibres were seen to be markedly deficient, and the substance of the ganglia was found to be chiefly composed of fibrous connective-tissue, enclosing numerous small, strongly refractive molecules, and a few long, slender nuclei. The true nerve-fibres, embedded in this tissue, presented nothing remarkable in their appearance or distribution. (BARTSCH, *Central-Blatt f. Med. Wiss.*, Jahrgang v. p. 397.)

CASE XXXIII.—*Addison's Disease. Ulcers of Colon and Strumous Abscesses.*¹

(ABSTRACT.)

J. R., labourer, aged 34, was admitted into the Tübingen Hospital in April 1866, under the care of Professor Niemeyer.

Patient stated that he had been strong and healthy, and had done much heavy work. While serving in the army as a youth, a bad kick from a horse on the shin-bone had laid him up for four months, and splinters had come away with much suppuration, but he had quite recovered, and had continued to labour hard without difficulty until about eighteen months before his admission; when he had a sudden, and apparently causeless, attack of general indisposition, debility, loss of appetite, vomiting.

¹ Case 169, Appendix B.

and diarrhœa, which lasted for a week, and then left him well for six months. In the spring of 1865 similar symptoms returned, with great lassitude, giddiness, and faintings, and during the summer his friends began to notice that he looked jaundiced. The debility and discoloration of skin continued to increase, and an abscess and fistula formed in the right testicle before his admission. Patient continued under occasional observation for more than two years, suffering from successive abscesses and fistulæ in both testicles, on the right fore-arm and near the anus, and from occasional epileptiform attacks, as well as from debility, nausea, lumbar pains, and shortness of breath on exertion. At times he was well enough to resume work. Addison's disease was diagnosed from the first.

During the last year of life he was kept mostly in the hospital, was well fed, and did light work. His whole skin had gradually become of a deep smoke-brown, his face and neck dark bronze-colour, and the flexures of joints (except the axillæ) and some parts exposed to pressure, were as black as negro-skin. Latterly he had frequent epistaxis and diarrhœa, followed by increased debility and giddiness, but got up as usual to his work on the morning of his death, when he was seized with sudden speechlessness and powerlessness, being able only to move his hands and feet. Dyspnœa, vomiting, and cyanosis supervened, and he died in a few hours.

Post-mortem Examination.—Brain-substance œdematous; cortices very dark and full of blood. Lungs adherent, in apices hard grey knots, containing one or more yellow pea-sized masses. Heart, liver, spleen, and right kidney dark-coloured, but otherwise normal. The right supra-renal capsule was firmly embedded in thick fatty tissue, and formed a hard mass, about the size of a damson plum, of nearly the normal shape of the organ, and consisting of firm, grey, semi-transparent tissue, resembling cicatricial tissue, in which were contained numerous solid, cheesy nodules, up to the size of a small pea. At the apex there remained a trace of the normal gland-tissue.

The left supra-renal capsule and the left kidney were found blended into one mass with the neighbouring portion of the descending colon, by means of an overgrowth of firm tissue traversed by tough, fibrous threads. The involved portion of the colon was so much contracted that the little finger could not

be introduced. The colon was at this part the seat of an extensive cicatrix of an old ulcer, which had involved the whole circumference of the tube. The mucous membrane at the margin of the ulcer was swollen and deeply pigmented, the edge of the cicatrix was deep red and sharply defined, whilst the cicatricial tissue was of a whitish grey, showing some small islands of mucous membrane. The wall of the colon was at this part much thickened by muscular hypertrophy, and was adherent to the pancreas by the same overgrowth of tissue which attached it to the left kidney and supra-renal capsule. The pancreas and left kidney were otherwise normal.

The left supra-renal capsule was enclosed in a mass of hard lobulated tissue, and was of the size of a large walnut. On section it presented the same morbid appearances as the right capsule, but no traces of the normal structure could be discovered. The mesentery was thickened; the stomach presented nothing abnormal.

In one of the coils of the small intestine there was an irregular ulcer in process of healing; and, in the ascending and transverse colon were four smaller ulcers, presenting the same general character and appearances as the larger one already described. There were several blind fistulous openings in the scrotum, and the tissue of the testicles showed proliferation of connective-tissue, with a hard, grey, semi-transparent nodule containing some dry, yellow, cheesy spots. There was no history of syphilis and no appearance of tuberculosis. (Clinical history reported, during the patient's lifetime, by AVERBECK, *Die Addison'sche Krankheit*, Erlangen, 1869, p. 20; *post-mortem* examination by SCHÜPPEL, *Archiv der Heilkunde*, 1870, p. 87.)

CASE XXXIV.—*Addison's Disease. Typical Case.*¹

A servant girl, aged 16, was admitted into the town hospital at Rotterdam. She had always been weakly, of a pale brownish complexion, and had been subject to palpitation on the least over-exertion. About five months before her admission she had had a great fright; and, from that time, the catamenia had ceased, she had suffered from lassitude, debility, vertigo and shooting pains

¹ Case 73, Appendix B.

in the right side, and brown stains had appeared on various parts of her skin.

On admission her complexion was light brown, and on her forehead, eyelids, left cheek and arms, were small, round, sharply defined, almost black specks, somewhat larger than freckles. On the neck and backs of the hands, in the flexures of the elbow, knee, and shoulder-joints, and on certain parts which had been pressed by strings, were seen irregular sepia-brown patches without defined margins, which faded gradually into the normal skin. Her condition was very anæmic; she had pains in the lumbar region and also in the back and head, but she felt palpitation only after exertion.

At first she improved under the use of iron, but later the stomach would not bear it, and she complained of pain and oppression in the epigastric region and of want of appetite. She had frequent vomiting or diarrhoea, and occasional fits of hiccup, giddiness, and drowsiness. Latterly the anæmia and debility increased, and the brown stains spread so that the face had a dark repulsive appearance. At length sleep became constant, the pulse gradually stopped, and death took place.

Post-mortem Examination.—Skull not opened. Thick subcutaneous layer of fat; blood thin and small in quantity. Lungs healthy. Great follicular enlargement in both small and large intestine; mesenteric glands all much enlarged and hard, but not tuberculous, exhibiting on section a smooth, glistening, lardaceous appearance; spleen somewhat enlarged, with large follicles. Kidneys healthy. Supra-renal capsules much enlarged, with hard tubercular nodules, embedded in a grey semi-transparent substance, but confluent towards the centre, and here and there beginning to soften. Dr. Boogaard found, on microscopical examination, that there were some traces of the cortical and medullary substance of the capsules, and that the sympathetic nerve 'in the neighbourhood of the abdominal aorta' was in an advanced stage of atrophy. (J. J. SCHMIDT, *Virchow. Canstatt's Jahresbericht*, 1859. Pt. iv. p. 288.)

CASE XXXV.—*Addison's Bronzed-skin Disease. Typical Case. Reported as Addison's Disease and Cancer of the Supra-renal Capsules.*¹

(ABSTRACT).

A. F., married woman, aged 36, was admitted into the Hospital St. Gatien, at Tours, November 4, 1862.

Patient had led a very active life, and had suffered from no illnesses but occasional intermittent fever. She stated that about ten months previous to her admission, after a period of heavy work as laundress in the open air, her skin had begun to take a brownish hue, which she had attributed at first to the effects of sun and wind. About the same time she had begun to suffer from debility, which had progressively increased till all exertion had become impossible; the catamenia had gradually disappeared, and the whole surface of her body had become smoke-coloured with black-brown patches in certain parts.

On admission her appearance was precisely that of a mulatto. The entire surface had a blackish hue, but on the back of the neck, in the right groin, left axilla and other parts, there were more or less absolutely black patches, identical in colour with negro-skin. The buccal mucous membrane was marbled with blackish stains, resembling those seen in the mouths of certain kinds of dogs. The teeth were surrounded by the areolæ which are frequently observed in lead-poisoning. The pharyngeal mucous membrane and the conjunctivæ presented nothing abnormal. The nails showed at their roots a narrow bluish stripe similar to that on the nails of negroes.

The patient walked somewhat bent forwards, a posture which she attributed partly to her weakness, and partly to a fixed and constant pain which she experienced in the loins.

Under tonic treatment and generous nourishment she at first considerably improved, and began to entertain hopes, which, taught by Addison's experience, Dr. Duëlos did not share. She had even fixed a day for leaving the hospital, when one morning, about five weeks after her admission, she was suddenly seized with a total loss of power, followed by repeated and persistent vomitings, under which she sank and died in a few hours.

¹ Case 293. Appendix B.

Post-mortem Examination.—Lungs perfectly sound; no trace of tubercle nor of any other lesion. Heart, liver, stomach, spleen, kidneys, perfectly normal. No mesenteric disease. No enlarged glands.

The two supra-renal capsules, on the contrary, were in a state of complete cancerous degeneration. They formed two large tumours of the size of eggs; irregular in shape, much nodulated and very hard. On section, they grated against the scalpel, and presented exactly the appearance of lardaceous tissue—the most perfect scirrhus. There was no cavity in either capsule. (DUCLOS, *Bulletin Général de Thérapeutique*, vol. lxiv. p. 98).

CASE XXXVI.—*Addison's Disease. Reported as Addison's Disease and Cancer of the Supra-renal Capsules.*¹

(ABSTRACT.)

On Aug. 28, 1853, Dr. Mettenheimer was present with several colleagues at the autopsy of a man aged 47, whose case had presented several inexplicable features. His illness had lasted several years. The most prominent symptoms had been great debility, loss of appetite, obstinate constipation, constant pain in the region of the loins, which prevented his walking, and a peculiar grey-brown discoloration of the skin. The heart-sounds and heart's impulse were always very feeble, and the debility gradually became so extreme that the patient spent the last months of his life in bed. The urine was latterly very scanty, thick, and ammoniacal, and at last coma supervened in which the patient died.

The discoloration of the skin had struck the physicians in charge as very remarkable, and had been compared by them to the change of colour said to be produced by the long-continued internal use of nitrate of silver. This remarkable discoloration was very obvious after death, but was most strongly marked on the face and hands, which, in his notes made at the time, Dr. Mettenheimer described as being of a mulatto-brown colour, with a blackish-grey, smoky, or metallic tinge. The discoloration on the rest of the body approached nearer to the usual hue of jaundice, without exactly resembling it.

¹ Case 295, Appendix B.

Post-mortem Examination.—Left lung entirely adherent; in the lower lobes some scattered nodules of tuberculous or cancerous nature. Heart small, flaccid; in the right ventricle a large, pale, fibrinous clot. The coronary artery, with all its branches, ossified, and some of the branches partly obliterated. Nutmeg liver, larger than normal. Spleen enlarged, softened, and pale red, as in typhus. Kidneys hyperæmic and seen under the microscope to be in the earlier stage of Bright's disease.

At the upper end of the right kidney, between that organ and the liver, was situated a hard cancerous tumour the size of a child's fist. A similar tumour lay in the corresponding position above the left kidney. The tumour on the left side presented on section some softened patches of greenish appearance, which consisted of fat-globules, aggregations of fat-granules and cholesterine crystals; the tissue of the tumour itself consisted of free-nuclei and extremely long spindle-shaped cells.

Out of the tumour on the right side a creamy fluid could be pressed, the elements of which were shown by the microscope to be delicate, finely-granular cells of irregular shape. No trace could be discovered of the normal tissue of the supra-renal capsules.¹ (METTENHEIMER, *Deutsche Klinik*, 1856, p. 483.)

CASE XXXVII.—*Addison's Disease. Supposed Cancerous Disease of Supra-renal Capsules.*²

Dr. Gage, early in Feb. 1862, was called, in consultation with Dr. Heywood, to see Mrs. Currie, a tall, fleshy, fine-looking lady, aged 51; light complexion, blue eyes, and dark-brown hair. Her disease was scirrhus of the right breast, of several years' growth, with no lymphatic glands affected. Breast amputated Feb. 13. Patient made a good recovery, and her health remained good for eighteen months.

In Sept. 1863 her health began to fail, the first symptoms being occasional paroxysms of pain and distress in the epigastric

¹ This case occurred before the publication of Addison's monograph. When three years after his notes had been recorded, Dr. Mettenheimer read the accounts of Addison's disease, he was delighted to find that his almost-forgotten case perfectly corresponded, both in clinical symptoms and pathological characters, with the description of that disease by Addison and Hutchinson.

² Case 294, Appendix B.

and right hypochondriac regions, shooting round to the back, attended with tenderness, soreness, and occasional vomiting. These symptoms increased during the winter, so that when she walked her body was bent forwards, and to the right side.

In March 1864 she came again under Dr. Gage's care. He thus records her state:—

April 4, 1864.—Patient anæmic; not much emaciated; flesh soft and flabby; is very feeble. Pulse weak, rapid, sometimes almost imperceptible; she is faint and breathless on the slightest exertion; walks in a stooping posture because of pain and soreness in the epigastrium. She lies upon her right side, with her limbs drawn up, and head and shoulders depressed. Lying upon the back or left side causes a distressing tearing and pulling sensation in the right hypochondrium. The cicatrix in the breast is healthy. Nothing abnormal is perceptible in the region where pain is complained of. *But there is a great change in her complexion, viz. a bronzed discoloration of the skin, most marked upon the backs of the hands and fingers, flexures of all the joints, and on the face. Spirits depressed; appetite unusually good. Bowels regular. Urine nearly normal. Sleep natural.*

May 20.—Since last note has had almost daily paroxysms of acute gastric distress, with sensations of flatus in stomach, sometimes lasting for hours, generally relieved by eructation or vomiting. Bronzing of skin much increased, both in quantity and extent of surface. Local and general symptoms unchanged.

June 17.—Health and strength much failed; confined to bed fourteen days; lying still on right side with legs drawn up and body bent much forward. She thinks that food increases her gastric distress, and lately has refused it a great deal. Bronzing much deeper; her hands look like a mulatto's.

June 18.—After an unusually severe paroxysm of distress, violent vomiting has come on, relieving entirely the pain, but causing great exhaustion and inability to take or retain food.

June 30.—Vomiting has been mainly controlled, but inability to take food has continued, and at 6 P.M. patient died of exhaustion. Mind clear to the last. Bronzing of skin steadily increased and deepened up to the last moment. The bronzing is like that of a bronze statue, without lustre.

Autopsy.—Not much emaciation; flesh soft and flabby. Discoloration somewhat faded, but well-marked. One inch of fat

overlies sternum and abdomen; much fat inside abdomen. On removal of stomach and intestines two large, almost spherical, tumours are observed, occupying the place of the supra-renal capsules, joined together across the vertebræ, by a thickened, corrugated mass of enlarged and diseased lymphatic glands. Tumour on the right side somewhat larger than that on the left, being two and a half inches in diameter, and adherent by a strong and broad attachment to the under surface of liver. From this point of attachment several broad lines of reddish-white soft deposit radiate into the substance of the liver for one and a half inches, resembling soft cancer, as sometimes seen infiltrated in that organ.

The tumours, externally, present a soft uniform glistening surface.

On section, a dense, firm, fibrous texture, making a smooth surface, at first white, but soon covered by a bright, orange-yellow exudation, which, after exposure to the air, became a dingy, greenish-brown. The diseased lymphatic gland was of a very similar texture, but gave, on section, none of the yellow fluid. Nothing else abnormal in thorax or abdomen. Head not examined. (GAGE, *Boston Medical and Surgical Journ.*, vol. lxxi. p. 69.)

A P P E N D I X B.



THE three hundred and thirty-three cases referred to in the Lectures are here numbered continuously, from first to last, as they stand; they are classed in groups corresponding with those into which they are divided in Lecture II., and the groups are placed in the order in which they are discussed.

Each group is headed by a description of the character of the cases which it comprises. For convenience of reference, the cases in each group are arranged under the names of their respective reporters in alphabetical order; but, whenever the reporter has not himself been in charge of the case, the name of the medical attendant is placed in brackets immediately after that of the reporter.

A full bibliographical reference is given to the publication from which each case was extracted; and, lastly, the age and sex of the patient, and the principal facts adverted to in the Lectures, as bearing upon the etiology of Addison's disease, are subjoined to the reference, in every case in which they were recorded.

The following synopsis shows the character and number of the cases comprised in each group:—

	Cases.
GROUP I.—Typical cases of Addison's disease, in which the characteristic constitutional symptoms and discoloration of skin were more or less fully developed, and in which there was no co-existing disease	103
GROUP II.—Cases of Addison's disease apparently typical, but in which either the state of other organs is not reported, or the constitutional symptoms and discoloration of skin are not fully described	16

	Cases.
GROUP III.—Cases of Addison's disease, in which the characteristic constitutional symptoms and discoloration of skin were more or less fully developed, but in which there was some co-existing disease	64
GROUP IV.—Cases of Addison's disease imperfectly recorded	19
GROUP V.—Cases of Addison's disease without discoloration of skin, in which there were serious co-existent wasting diseases, and, generally speaking, no characteristic constitutional symptoms	18
GROUP VI.—Cases of Addison's disease without discoloration of skin, in which there was no co-existing disease of importance, and which were typical as to constitutional symptoms, but of short duration	10
	230
GROUP VII.—Cases of 'Bronzed Skin' without any disease of the supra-renal capsules	21
GROUP VIII.—Cases of Cancer of the Supra-renal Capsules without any discoloration of skin	24
GROUP IX.—Cases of Miscellaneous Affections of the Supra-renal Capsules without any discoloration of skin	12
GROUP X.—Cases of Cancer (or so-called Cancer) of the Supra-renal Capsules with some discoloration of skin	9
GROUP XI.—Cases of Miscellaneous Affections of the Supra-renal Capsules with some discoloration of skin	5
GROUP XII.—Cases in which the lesion in the Supra-renal Capsules is imperfectly described, or of doubtful nature	32
	103

GROUP I.—TYPICAL CASES OF ADDISON'S DISEASE, in which the characteristic constitutional symptoms and discoloration of skin were more or less fully developed, and in which there was no co-existing disease.

1. ADDISON. On Disease of the Supra-renal Capsules. Lond. 1855. p. 12. *Male, aged 35; tidewaiter.*
2. ADDISON. On Disease of the Supra-renal Capsules. p. 19. *Male, aged 22; stonemason.*
3. ADDISON. On Disease of the Supra-renal Capsules. p. 25. *Male, middle-aged; barrister.*
4. ADDISON. (*Bright.*) On Disease of the Supra-renal Capsules. p. 22. *Female.*
5. ADDISON. (*Wilks.*) Med. Times and Gazette, vol. xxxvi. p. 539. *Female, aged 18; lady.*
6. ANDREW. (*Black.*) Trans. Path. Soc. of Lond., vol. xvii. p. 395. *Male, aged 23; corkcutter.*
7. BAEHR. Virchow u. Hirsch, Jahresbericht f. 1872, vol. ii. p. 305. *Male, aged 17; tanner.*
8. BACON, MACKENZIE. Med. Times and Gazette, vol. xl. p. 132. *Male, aged 15; plasterer.*
9. BALY. Trans. Path. Soc. of Lond., vol. viii. p. 325. *Male, aged 21; baker.*
10. BRISTOWE. Trans. Path. Soc. of Lond., vol. xix. p. 410. *Male, aged 16; druggist's assistant.*
11. BRISTOWE. (Unpublished case.) Appendix A, p. 131. Case x. *Female, aged 48.*
12. BURRELL. Meissner. Schmidt's Jahrbuch, vol. cliv. p. 39. *Male, aged 43.*
13. CHILD. Lancet, 1865, vol. i. p. 176. *Female, aged 37.*
14. CHOLMELEY. Med. Times and Gazette, 1869, vol. ii. p. 219. *Female, aged 27.*
15. COTTON. Med. Times and Gazette, vol. xxxvi. p. 33. *Male; surgeon.*
16. DALTON. New York Journ. of Med., 1860. p. 304. *Male, aged 17.*
17. DARIN. Meissner. Schmidt's Jahrbuch, vol. cxxvi. p. 114. *Female, aged 34.*
18. DE LA PORTE. Virchow u. Hirsch, Jahresbericht f. 1869, p. 272. *Male, aged 28; cavalry officer.*
19. DICKINSON. (*Pitman.*) Trans. Path. Soc. of Lond., vol. xvi. p. 243. *Female, aged 39; straw-plaiter.*

20. ELLIS. Boston Med. and Surg. Journ., vol. lxvi. p. 31.
Male, aged 37; lawyer.
21. FAURE. (*Barthez.*) Union Médicale, 1866. p. 266. *Male, aged 14.*
22. FINLAYSON. Glasgow Med. Journ., 1871. p. 434. *Male, aged 33; pattern designer.*
23. FRESNE. Gazette des Hôpitaux, 1857. p. 317. *Female, aged 30.*
24. GERHARDT. Meissner. Schmidt's Jahrbuch, vol. cxlii. p. 109.
Male, aged 30.
25. GREENHOW. Trans. Path. Soc. of Lond., vol. x. p. 269.
Female, aged 31.
26. GREENHOW. Trans. Path. Soc. of Lond., vol. xvi. p. 247.
Female, aged 13.
27. GREENHOW. Trans. Path. Soc. of Lond., vol. xix. p. 204.
Male, aged 43; park keeper.
28. GREENHOW. (*Hodson.*) Trans. Path. Soc. of Lond., vol. xv. p. 231. *Male, 21; merchant.*
29. GREENHOW. (*Ringer.*) Trans. Path. Soc. of Lond., vol. xxiv. p. 229. *Male, aged 20; upholsterer.*
30. GUTTMANN. (*Hirschberg.*) Berlin. Klin. Wochenschr. 1870. p. 197. *Female, aged 11.*
31. HABERSHON. Guy's Hosp. Reports, 3rd Series,¹ vol. vii. p. 232. *Male, aged 23; lighterman.*
32. HABERSHON. Guy's Hosp. Reports, vol. x. p. 82. *Male, aged 18; bookbinder.*
33. HABERSHON. (*Webb.*) Guy's Hosp. Reports, vol. x. p. 80.
Female, aged 32; dressmaker.
34. HARDWICK. Trans. Path. Soc. of Lond., vol. xv. p. 223.
Male, aged 52.
35. HARDWICK. Trans. Path. Soc. of Lond., vol. xv. p. 224.
Female, aged 69.
36. HAYDEN. Dub. Quart. Journ. of Med. Sci., May, 1865. *Male, aged 16.*
37. HECKFORD. Lancet, 1867, vol. i. p. 299. *Female, aged 14.*
38. HESLOP. Lancet, 1870, vol. i. p. 600. *Male, aged 21; tin-plate worker.*
39. HIRZEL. (*Griesinger.*) Inaug. Diss. Zurich, 1860. p. 1.
Male, aged 21; journeyman locksmith.
40. HITCHCOCK. Boston Med. and Surg. Journ., New Series, vol. iii. p. 148. *Female, aged 25.*
41. HOLT. Lancet, 1865, vol. ii. p. 454. *Male, aged 43.*

¹ All references to Guy's Hosp. Reports are to the volumes of the 3rd series.

42. HOUGHTON. *Lancet*, 1870, vol. ii. p. 119. *Female, aged 17.*
43. HOUSELEY. *Lancet*, 1860, vol. ii. p. 8. *Male, aged 33; farm labourer.*
44. H. S. TO READING HOSP. *Med. Times and Gazette*, vol. xxxix. p. 265. *Male, aged 26; travelling musician.*
45. HUBER. *Deutsch. Archiv f. Klin. Med.*, vol. i. p. 635. *Male, aged 52; publican.*
46. HUGHES. *Dub. Quart. Journ. of Med. Sci.*, 1865. p. 363. *Male, aged 45; herdsman.*
47. HUTCHINSON. (*Risdon Bennett.*) *Trans. Path. Soc. of Lond.*, vol. ix. p. 414. *Male, aged 11.*
48. JACKSON. (*Howe.*) *Boston Med. and Surg. Journ.*, vol. lxiv. p. 308. *Female, aged 50.*
49. JEAFFRESON. *Brit. Med. Journ.*, 1857. p. 22. *Male, aged 40; labourer.*
50. KUHLMANN. *Berlin. Klin. Wochenschr.*, 1869. p. 481. *Male, aged 33; bricklayer.*
51. LITTLE. (*Mackenzie.*) *Trans. Path. Soc. of Lond.*, vol. xiii. p. 247. *Female, aged 18.*
52. LITTLE, STROMEYER. (*Parker.*) *Trans. Path. Soc. of Lond.*, vol. xvii. p. 301. *Female, aged 15; servant.*
53. LÖWE. *Meissner. Schmidt's Jahrbuch*, vol. cliv. p. 37. *Female, aged 27; cook.*
54. MACKER. *Meissner. Schmidt's Jahrbuch*, vol. cxxvi. p. 114. *Female, aged 27.*
55. MARSHALL. *Trans. Path. Soc. of Lond.*, vol. xxiv. p. 221. *Female, aged 28.*
56. MARTINEAU. (*Cornil et Vast.*) *De la Maladie d'Addison*, Paris, 1864. p. 43. *Female, aged 48; labourer.*
57. MARTINEAU. (*Frémy.*) *De la Maladie d'Addison*, p. 30. *Male, aged 27; farrier.*
58. MEYER U. RECKLINGSHAUSEN. *Deutsche Klinik*, 1864. p. 78. *Female, aged 43.*
59. MINOT. *Boston Med. and Surg. Journ.*, vol. lxxvii. p. 40. *Female, aged 40.*
60. MONRO. *Assoc. Med. Journ.*, 1856. p. 48. *Female, aged 40; clergyman's wife.*
61. MONTGOMERY. (*Barker.*) *Trans. Path. Soc. of Lond.*, vol. xiii. p. 246. *Male, aged 14.*
62. MOORE, J. *Lancet*, 1864, vol. ii. p. 475. *Male, aged 30; clerk.*
63. NICHOLSON. *Brit. Med. Journ.*, 1872, vol. ii. p. 120. *Male, aged 14; baker's lad.*

64. PAGE. *Brit. Med. Journ.*, 1859. p. 717. *Male, aged 17; saddler.*
65. PAYNE. (*Sieveking.*) *Trans. Path. Soc. of Lond.*, vol. xxii. p. 281. *Male, aged 32.*
66. REID, SEATON. *Med. Times and Gazette*, 1861, vol. ii. p. 32. *Female, aged 28.*
67. RISEL. *Deutsch. Archiv f. Klin. Med.*, vol. vii. p. 42. *Male, aged 20; brickmaker.*
68. ROBERTSON. *Med. Times and Gazette*, vol. xxxiii. p. 646. *Male, aged 26; labourer.*
69. ROOTES, SYMONDS. *Med. Times and Gazette*, 1866, vol. ii. p. 637. *Female, aged 32; laundrymaid.*
70. ROWE. *Med. Times and Gazette*, vol. xxxiii. p. 190. *Male, aged 20.*
71. SANDERSON, BURDON. *Trans. Path. Soc. of Lond.*, vol. xx. p. 378. *Female, aged 30; servant.*
72. SCHMIDT. *Virchow. Canstatt's Jahresbericht*, 1859, Pt. IV. p. 288. *Male, aged 23; sailor.*
73. SCHMIDT. *Virchow. Canstatt's Jahresbericht*, 1859, Pt. IV. p. 288. *Female, aged 16; servant.*
74. SEITZ. (*Möhl.*) *Deutsche Klinik*, 1866. p. 125. *Female, aged 27; milkman's wife.*
75. SEVERINI. *Meissner. Schmidt's Jahrbuch*, vol. cxlii. p. 109. *Female, aged 38.*
76. SIBLEY. (*Seth Thompson.*) *Med. Times and Gazette*, vol. xxxiii. p. 188. *Male, aged 20; house painter.*
77. SPENDER, KENT. *Brit. Med. Journ.*, 1857. p. 274. *Female, aged 21.*
78. STURGES. *Lancet*, 1864, vol. ii. p. 569. *Male, aged 32; engine cleaner.*
79. STURGES. *Lancet*, 1864., vol. ii. p. 569. *Male, aged 30; costermonger.*
80. TAYLOR, ISAAC. *Med. Times and Gazette*, vol. xxxv. p. 36. *Male, aged 22.*
81. TUCKWELL. *Trans. Path. Soc. of Lond.*, vol. xix. p. 420. *Male, aged 55; blacksmith.*
82. TUCKWELL. *St. Barthol. Hosp. Reports*, vol. vii. p. 73. *Female, aged 31.*
83. TUCKWELL. (*Gray.*) *Trans. Path. Soc. of Lond.*, vol. xix. p. 419. *Male, aged 47.*
84. ULRICH. *Deutsche Klinik.*, 1862. p. 25. *Male, aged 24.*
85. VALENTINE. *Med. Times and Gazette*, 1861, vol. ii. p. 33. *Male, aged 30; marine store dealer.*

86. VAN ANDEL. Meissner. Schmidt's Jahrbuch, vol. cxlii. p. 114.
Female, aged 27.
87. VAN DEN CORPUT. Gazette Hebdom. de Méd., 1863. p. 493.
Female, aged 37; servant.
88. VECCHIETTI. Archives Gén. de Méd., 1867, vol. i. p. 23.
Female, aged 28; newspaper hawker.
89. WALLACE. Assoc. Med. Journ., 1856, p. 1035. *Female, aged 48.*
90. WHITEFORD. Edin. Med. Journ., vol. xii. p. 27. *Female, aged 54.*
91. WILKS. Trans. Path. Soc. of Lond., vol. xv. p. 218. *Female, aged 22.*
92. WILKS. (*Addison.*) Guy's Hosp. Reports, vol. viii. p. 42.
Male, aged 32; engine driver.
93. WILKS. (*Addison.*) Guy's Hosp. Reports, vol. viii. p. 52.
Male, aged 13.
94. WILKS. (*Dyster.*) Lancet, 1864, vol. i. p. 22. *Female, aged 32; lady.*
95. WILKS. (*Pavy.*) Guy's Hosp. Reports, vol. viii. p. 47.
Female, aged 26.
96. WILKS. (*Ranking.*) Guy's Hosp. Reports, vol. viii. p. 34.
Female, aged 59; lady.
97. WILKS. (*S. Rootes.*) Med. Times and Gazette, 1866, vol. ii. p. 313. *Female, aged 57.*
98. WILKS. (*Stedman.*) Guy's Hosp. Reports, vol. viii. p. 59.
Male, aged 32; farm labourer.
99. WILKS. (*Strange.*) Guy's Hosp. Reports, vol. xi. p. 35.
Male, aged 26.
100. WILKS. (*Toulmin.*) Guy's Hosp. Reports, vol. viii. p. 56.
Female, aged 37.
101. WILKS. (*Truman.*) Trans. Path. Soc. of Lond., vol. xiv. p. 253. *Male, aged 26; grocer.*
102. WILKS. (*Welford.*) Trans. Path. Soc. of Lond., vol. x. p. 273. *Male, aged 21.*
103. WOLFF. Berlin. Klin. Wochenschr., 1869. p. 174. *Male, aged 16; apprentice.*

GROUP II.—CASES OF ADDISON'S DISEASE APPARENTLY TYPICAL, but in which either the state of other organs is not reported, or the constitutional symptoms and discoloration of skin are not fully described.

104. AVERBECK. (*Isermeyer.*) Die Addison'sche Krankheit. Erlangen, 1869. p. 19. *Male, aged 19; labourer.**
105. BORLAND. Boston Med. and Surg. Journ., vol. lxxvi. p. 151. *Female, aged 19.**
106. BOWDITCH. (*Gage.*) Boston Med. and Surg. Journ., vol. lxi. p. 165. *Female, aged 31.**
107. CLARK, A. (*Halsted.*) Boston Med. and Surg. Journ. vol. lxi. p. 238. *Female.†*
108. CLARKE. (*Fleaman.*) Lancet, 1869, vol. ii. p. 336. *Male, aged 38.†*
109. DOWN, LANGDON. Trans. Path. Soc. of Lond., vol. xx. p. 388. *Male, aged 20.†*
110. DUNCAN. Dub. Quart. Journ. of Med. Sci., 1863. p. 450. *Female, aged 40.**
111. GREENHOW. (*Ringer.*) Trans. Path. Soc. of Lond., vol. xxiv. p. 234. *Male, aged 32.**
112. HENOCH. (*Oppolzer.*) Wien. Med. Wochenschr., 1866. p. 1501. *Male, aged 14.†*
113. HERMANN. Virchow u. Hirsch, Jahresber. f. 1869. p. 272. *Male, aged 39; compositor.**
114. MURCHISON. (*Gavin Strichen.*) Trans. Path. Soc. of Lond., vol. xvii. p. 397. *Male, aged 30; blacksmith.**
115. ROOTES, SYMONDS. Med. Times and Gazette, vol. xxxiii. p. 581. *Male, aged 54; solicitor.**
116. VALENTINE. Med. Times and Gazette, 1861, vol. ii. p. 33. *Male, aged 35; mason.**
117. WAGNER. Virchow. Canstatt's Jahresbericht, 1858. Pt. IV. p. 273. *Male, aged 16.†*
118. WILKS. (*Barlow.*) Guy's Hosp. Reports, vol. viii. p. 39. *Male, aged 24; carpenter.**
119. WILKS. (*Gilbertson.*) Guy's Hosp. Reports, vol. xi. p. 36. *Female, aged 50.**

* State of other organs not reported.

† Case not fully described.

GROUP III. — CASES OF ADDISON'S DISEASE, in which the characteristic constitutional symptoms and discoloration of skin were more or less fully developed, but in which there was some co-existing disease.

120. ADDISON. On Disease of the Supra-renal Capsules, Lond., 1855. p. 9. *Male, aged 32; baker. (Pneumonia and pericarditis.)*
121. ADDISON. On Disease of the Supra-renal Capsules, p. 15. *Male, aged 36; carpenter. (Psoas abscess and vertebral disease.)*
122. AVERBECK. (*Liebermeister.*) Die Addison'sche Krankheit. Erlangen, 1869. p. 10. *Male, aged 47; carpenter. (Red softening of brain.)*
123. AVERBECK. (*Späth.*) Die Addison'sche Krankheit. p. 15. *Female, aged 29. (Kidney disease.)*
124. BARTSCH. (*Leyden.*) Central Blatt. f. Med. Wiss. Jahrgang v. p. 397. *Male, aged 47; shopman. (Angular curvature of spine.)*
125. BROADBENT. Trans. Path. Soc. of Lond., vol. xiii. p. 246. *Female, aged 23. (Tumour on spinal cord.)*
126. BÜHL. Wien. Med. Wochenschr., 1860. p. 20. *Male, aged 38; journeyman. (Spleen and all lymphatic glands much enlarged.)*
127. BÜHL. (*Vogel.*) Wien. Med. Wochenschr., 1860. p. 6. *Male, aged 20. (Tubercle of lungs.)*
128. CHATIN. Virchow u. Hirsch, Jahresber. f. 1867. vol. ii. p. 306. *Male, aged 46. (Tubercle of lungs.)*
129. COURVOISIER. Virchow u. Hirsch, Jahresber. f. 1872. p. 305. *Female, aged 47. (Lung disease.)*
130. EDWARDS. Med. Times and Gazette, vol. xxxvi. p. 350. *Male, aged 48; tailor. (Tubercle of lungs and kidney.)*
131. ERICHSEN. Meissner. Schmidt's Jahrbuch, vol. cxxvi. p. 110. *Female, aged 21. (Disease of brain.)*
132. FERNIE. (*Cowan.*) Brit. Med. Journ., 1857. p. 581. *Female, aged 14. (Tubercle of lungs.)*
133. GLOVER. Edin. Med. Journ., 1859. p. 116. *Male, aged 39; furnace-man. (Psoas abscess and caries of spine.)*
134. GOULD. Boston Med. and Surg. Journ., vol. lvi. p. 40. *Male, aged 44; farmer. (Large cretaceous nodule in brain.)*

135. GRAY. (*Rolleston.*) *Med. Times and Gazette*, 1860, vol. i. p. 237. *Male, aged 47; labourer. (Phthisis.)*
136. GREENHOW. *Trans. Path. Soc. of Lond.*, vol. xv. p. 228. *Male, aged 24; engineer's labourer. (Sacro-iliac abscess and caries of bone.)*
137. GREENHOW. *Trans. Path. Soc. of Lond.*, vol. xxiv. p. 224. *Male, aged 25; carpenter. (Psoas abscess and vertebral disease.)*
138. GREENHOW. (*Stewart.*) *Trans. Path. Soc. of Lond.*, vol. xvii. p. 307. *Male, aged 32; coal-porter. (Psoas abscess with caries of spine.)*
139. GREENHOW. (*Thompson.*) *Trans. Path. Soc. of Lond.*, vol. xvii. p. 304. *Male, aged 55; labourer. (Tubercle of lungs and abdomen.)*
140. GROMIER. *Gaz. Méd. de Lyon*, 1857. p. 257. *Female, aged 51; silk-worker. (Caries of ribs and tubercles in lungs.)*
141. GUBIAN et TEISSIER. *Gaz. Méd. de Lyon*, 1857. p. 204. *Male, aged 36; labourer. (Disease of lumbar vertebræ.)*
142. GULL. *Med. Times and Gaz.*, 1865, vol. ii. p. 441. *Male. (Tubercle in lungs, and disease of tibia and tarsal bones.)*
143. GUSSMANN. (*Griesinger.*) *Archiv der Heilkunde*, vol. iv. p. 570. *Male, aged 33; shoemaker. (Tubercle of lungs and right testicle.)*
144. GUTTMANN. *Virchow u. Hirsch, Jahresber. f. 1868*, vol. ii. p. 277. *Female, aged 31; sempstress. (Tubercle of lungs.)*
145. HARDWICK. *Trans. Path. Soc. of Lond.*, vol. xv. p. 221. *Male, aged 29; tanner. (Psoas abscess and caries of spine.)*
146. HARLEY, G. (*Mackenzie.*) *Trans. Path. Soc. of Lond.*, vol. ix. p. 402. *Female, aged 33. (Tubercles on liver, ovarian cyst.)*
147. HARRINSON. *Brit. Med. Journ.*, 1860. p. 959. *Male, aged 35; baker. (Tubercle of lungs, abscess of kidney.)*
148. HEDENIUS. *Virchow u. Hirsch, Jahresber. f. 1867*, vol. ii. p. 308. *Male, aged 27; student. (Disease of spinal cord.)*
149. HESCHL. *Wien. Med. Wochenschr.*, 1873. p. 765. *Male, aged 34; geologist. (Tubercle of lungs; abscess of kidney.)*
150. HESCHL. *Wien. Med. Wochenschr.*, 1873. p. 765. *Female, aged 23; sempstress. (Tubercle of lungs.)*
151. HOLMES, T. (*Page.*) *Trans. Path. Soc. of Lond.*, vol. ix. p. 405. *Male, aged 45. (Phthisis and abscess at sternum.)*
152. HUTCHINSON. (*Burrows.*) *Med. Times and Gazette*, vol. xxxii. p. 59. *Male, aged 24; hawk. (Spinal disease and healed spinal abscess.)*
153. HUTCHINSON. (*Farre.*) *Med. Times and Gazette*, vol. xxxiii.

- p. 233. *Male, aged 37; licensed victualler. (Abscess of liver.)*
154. KIRKES. *Med. Times and Gazette*, vol. xxxv. p. 35. *Male, aged 21. (Tubercle of lungs and large intestine.)*
155. KUSSMAUL. Meissner. *Schmidt's Jahrbuch*, vol. cxxvi. p. 115. *Male, aged 19. (Tubercles in lungs and liver. Diseased thyroid.)*
156. LAVERAN. *Gaz. Hebdom. de Méd.*, 1873. p. 606. *Male, aged 25; soldier. (Abscess and fistula in right hip.)*
157. LEEMING. *Med. Times and Gazette*, 1860, vol. i. p. 83. *Female, aged 47. (Tubercle of lungs, spleen, and pancreas.)*
158. LONDON. Meissner. *Schmidt's Jahrbuch*, vol. cxxvi. p. 111. *Male, aged 52. (Chronic bronchial disease.)*
159. MALHERBE. *Gaz. des Hôpitaux*, 1856. p. 427. *Female, aged 43. (Tubercle of left kidney.)*
160. MARTINEAU. (*Moissenet.*) *De la Maladie d'Addison*, Paris, 1864. p. 46. *Male, aged 42; hall porter. (Angular curvature of spine and healed abscess.)*
161. MEINHARDT. *Virchow u. Hirsch, Jahresber. f. 1866*, vol. ii. p. 279. *Male, aged 52; miller. (Tubercle of lungs.)*
162. MEINHARDT. *Virchow u. Hirsch, Jahresber. f. 1866*, vol. ii. p. 280. *Female, aged 38; servant. (Tubercle of lungs.)*
163. MINGONI. *Gaz. Med. Ital., Lombardia*, 1856. No. 42. *Male, aged 36. (Tubercle in lungs, softening of brain.)*
164. MURCHISON. (*Bantock.*) *Trans. Path. Soc. of Lond.*, vol. xviii. p. 258. *Female, aged 35. (Disease of left kidney and ureter.)*
165. MURCHISON. (*Gairdner.*) *Trans. Path. Soc. of Lond.*, vol. xv. p. 224. *Male, aged 15; paper-stainer. (Tubercle of lungs and peritoneum.)*
166. PEACOCK. *Trans. Path. Soc. of Lond.*, vol. xi. p. 278. *Male, aged 20; shoemaker. (Hip-disease with abscesses some years before.)*
167. PLOSS. Meissner. *Schmidt's Jahrbuch*, vol. cxxvi. p. 110. *Male, aged 40; factory manager. (Brain soft, arachnoid thickened.)*
168. POWELL, DOUGLAS. *Trans. Path. Soc. of Lond.*, vol. xx. p. 386. *Male, aged 42; engine driver. (Chronic tubercle of lungs.)*
169. SCHÜPPEL. *Archiv der Heilkunde*, vol. xi. p. 87. *Male, aged 37; labourer. (Ulcers of colon; strumous abscesses.)*
170. SEITZ. (*Möhl.*) *Deutsche Klinik*, 1860. p. 113. *Male, aged 58; labourer. (Emphysema of lungs and dilated heart.)*

- 171 SEVERINI. Meissner. Schmidt's Jahrbuch, vol. cxlii. p. 111. *Female, aged 23. (Incipient phthisis.)*
- 172 SIBLEY. (*Hancorn and Buss.*) Trans. Path. Soc. of Lond., vol. x. p. 266. *Male, aged 43; shoemaker. (Angular curvature of spine.)*
- 173 SILVER. Trans. Path. Soc. of Lond., vol. xxii. p. 280. *Male, aged 24; solicitor's clerk. (Softening of brain.)*
- 174 SOUTHEY. Trans. Path. Soc. of Lond., vol. xxiii. p. 283. *Female, aged 39. (Tubercle of lungs.)*
- 175 STARK. Meissner. Schmidt's Jahrbuch, vol. cxxvi. p. 118. *Male, aged 22; miner. (Cheesy tumours on diaphragm.)*
- 176 TROUSSEAU. Gaz. des Hôpitaux, 1856. p. 365. *Male, aged 30; coachman. (Tubercle in lungs and kidneys.)*
- 177 VAN DEN CORPUT. Meissner. Schmidt's Jahrbuch, vol. cxlii. p. 116. *Female, aged 30. (Phthisis.)*
- 178 WILKS. Guy's Hosp. Reports, vol. viii. p. 44. *Male, aged 25. (Acute eczema. Old abscess in abdominal walls.)*
- 179 WILKS. (*Addison.*) Guy's Hosp. Reports, vol. viii. p. 40. *Male, aged 28; coachman. (Tubercle in lungs, softening of brain.)*
- 180 WILKS. (*Harris.*) Guy's Hosp. Reports, vol. viii. p. 60. *Male, aged 46; painter and glazier. (Phthisis.)*
- 181 WILKS. (*McDonogh.*) Guy's Hosp. Reports, vol. viii. p. 61. *Female, aged 26. (Vertebral disease and old vert. abscess.)*
- 182 WILLIAMS, C. T. Trans. Path. Soc. of Lond., vol. xxiii. p. 281. *Male, aged 18; cabinet-maker. (Tubercle of lungs.)*
- 183 WORKMAN. Brit. Med. Journ., 1863, vol. ii. p. 605. *Male, aged 33; labourer. (Tubercle in lungs.)*

GROUP IV.—CASES OF ADDISON'S DISEASE, imperfectly recorded.

- 184 BAKEWELL, HALL. Med. Times and Gazette, vol. xxxiii. p. 62. *Male, aged 28.*
- 185 BALY. Trans. Path. Soc. of Lond., vol. viii. p. 330.
- 186 BAZIN. *Léçons sur la Scrofule*, Paris, 1861. p. 45. *Male.*
- 187 BREHME. *Deutsche Klinik*, 1857. p. 284. *Male, about 60.*
- 188 DAVEY. Med. Times and Gazette, vol. xxxix. p. 30. *Female, aged 18.*
- 189 FRAENKEL. (*Traube.*) *Virchow u. Hirsch, Jahresbericht f.* 1870, vol. ii. p. 288.

190. HALDANE. Edin. Med. Journ., vol. viii. p. 1036. *Male*.
191. HESCHL. Wien. Med. Wochenschr, 1873. p. 789. *Male, aged 48.*
192. KIRKES. Med. Times and Gazette, vol. xxxv. p. 35. *Male, aged 25.*
193. KIRKES. Med. Times and Gazette, vol. xxxv. p. 35. *Male, aged 34; hostler.**
194. KIRKES. Med. Times and Gazette, vol. xxxv. p. 35. *Male, aged 47.**
195. MARKHAM. Trans. Path. Soc. of Lond., vol. x. p. 268. *Male, aged 36; painter.*
196. MARTINEAU. (*Worms.*) De la Maladie d'Addison. Paris, 1864. p. 70. *Male.*
197. RISEL. (*Neide.*) Deutsches Archiv f. Klin. Med., vol. vii. p. 56. *Male, aged 43.**
198. RISEL. (*Schotte.*) Deutsch. Archiv f. Klin. Med., vol. vii. p. 46. *Female, aged 15.**
199. ROCKWELL. New York Med. Record, 1872, Jan. 15. *Male.*
200. SAVIOTTI. Virchow's Archiv f. Path. Anat. &c., vol. xxxix. p. 524. *Male, aged 39.*
201. WILKS. (*Bright.*) Guy's Hosp. Reports, vol. viii. p. 33. *Female, aged 38.**
202. WILKS. (*Inglis.*) Guy's Hosp. Reports, vol. xi. p. 33. *Male.*

GROUP V.—CASES OF ADDISON'S DISEASE without discoloration of skin, in which there were co-existent wasting diseases, and, generally speaking, no characteristic constitutional symptoms.

203. ARNOTT, H. (*Shaw.*) Trans. Path. Soc. of Lond., vol. xix. p. 419. *Male, aged 13. (Spinal abscess with great discharge of pus.)*
204. BENNETT, HUGHES. Clin. Lect. on Pract. of Med., Edin. 1865. p. 714. *Male, aged 52. (General tuberculosis.)*
205. BRITAN. Brit. Med. Journ., 1858. p. 107. *Male, aged 19. (Hæmoptysis and Bright's disease.)*
206. BRITAN. Brit. Med. Journ., 1858. p. 107. *Male, aged 31. (Phthisis of lungs and cirrhosis of liver.)*

* Before Addison's discovery. No bronzing of skin mentioned.

207. COOTE. Trans. Path. Soc. of Lond., vol. x. p. 271. *Male, aged 23. (Lumbar abscesses from caries of vertebræ.)*
208. GREENHOW. (*Thompson.*) Trans. Path. Soc. of Lond., vol. xxiv. p. 235. *Male, aged 40. (Rapid phthisis.)*
209. HARLEY, G. Trans. Path. Soc. of Lond., vol. ix. p. 410. *Male, aged 35. (Acute phthisis.)*
210. HOLMES, T. Trans. Path. Soc. of Lond., vol. ix. p. 414. *Male. (Phthisis and strumous abscesses.)*
211. HULKE. Trans. Path. Soc. of Lond., vol. xiv. p. 254. *Male, aged 30. (Psoas abscess and incipient phthisis.)*
212. LAWTON. Boston Med. and Surg. Journ., vol. lxxvii. p. 16. *Male, aged 34. (Tubercles and vomiceæ in both lungs.)*
213. MURCHISON. Trans. Path. Soc. of Lond., vol. x. p. 268. *Male, aged 36. (Acute general tuberculosis.)*
214. OGLE, J. W. Trans. Path. Soc. of Lond., vol. viii. p. 330. *Female, aged 14. (Rapid phthisis and strumous disease of kidneys.)*
215. OGLE, J. W. Trans. Path. Soc. of Lond., vol. viii. p. 332. *Male, aged 36. (Phthisis.)*
216. OGLE, J. W. Trans. Path. Soc. of Lond., vol. ix. p. 407. *Male, aged 62. (Extensive disease of brain and kidneys.)*
217. POWER. Lancet, 1869, vol. ii. p. 801. *Male. (Tubercles throughout both lungs.)*
218. SCHMIDT. Virchow, Canstatt's Jahresbericht, 1859, Pt. IV. p. 288. *Male, aged 48. (General tuberculosis.)*
219. TRAUBE. Wien. Med. Wochenschr., 1860. p. 699. *Male, aged 48. (Acute tuberculosis.)*
220. WOODHOUSE. Brit. Med. Journ., 1863, vol. ii. p. 605. *Male, aged 63. (Liver disease and ascites.)*

GROUP VI.—CASES OF ADDISON'S DISEASE without discoloration of skin, in which there was no co-existing disease of importance, and which were typical as to constitutional symptoms, but of short duration.

221. BRISTOWE. Trans. Path. Soc. of Lond., vol. xi. p. 276. *Male, aged 18; printer. (Four months.)*
222. BRUCE. (*Russell Reynolds.*) Trans. Path. Soc. of Lond., vol. vii. p. 401. *Male, aged 31; printer. (Sixteen months.)*
223. CROSSMAN. Brit. Med. Journ., 1860. p. 359. *Male, aged 59; gardener. (Eight months.)*

224. GULL. *Med. Times and Gazette*, 1863, vol. i. p. 83. *Male, aged 31; publican. (Four months.)*
225. HESCHL. *Wien. Med. Wochenschr.*, 1873. p. 765. *Female, aged 23; sempstress. (Three weeks.)*
226. HERTZ. *Virchow's Archiv f. Path. Anat., &c.*, vol. xlix. p. 4. *Male, aged 38; tailor. (A few months.)*
227. MURCHISON. *Trans. Path. Soc. of Lond.*, vol. xix. p. 406. *Female, aged 19; servant. (Several months.)*
228. REES, OWEN. *Guy's Hosp. Reports*, vol. viii. p. 38. *Male, aged 38; wheelwright. (Nine weeks.)*
229. REES, OWEN. *Med. Times and Gazette*, 1866, vol. ii. p. 313. *Male, aged 36; carman. (Six Months.)*
230. TUCKWELL. *Trans. Path. Soc. of Lond.*, vol. xix. p. 49. *Male, aged 47. (A few weeks.)*

GROUP VII.—CASES OF BRONZED SKIN without any Disease of the Supra-renal Capsules.

231. AVERBECK. (*Hasse.*) *Die Addison'sche Krankheit.* Erlangen, 1869. p. 65. *Female, aged 60. (Vagabonds' discoloration.)*
232. FRÉMY. *Bullet. de la Soc. Anat.*, 1863, p. 42. *Male, aged 59. (Cancer, not involving supra-renal capsules.)*
233. FRICKE. *North Amer. Med. Chi. Rev.*, 1857, p. 604. *Male, aged 25. (Jaundice and cirrhosis of liver.)*
234. GIBB. *Trans. Path. Soc. of Lond.*, vol. xix. p. 408. *Male, aged 47. (Disease of the aortic valves.)*
235. GORDON. (*Wales.*) *Med. Times and Gazette*, 1870, vol. i. p. 281. *Male, young. (Syphilis.)*
236. HARLEY. *Trans. Path. Soc. of Lond.*, vol. xiii. p. 262. *Female, aged 64. (Hepatic symptoms during four years.)*
237. HARLEY. (*Parker.*) *Trans. Path. Soc. of Lond.*, vol. x. p. 264. *Male, aged 66. (Jaundice and liver disease.)*
238. HODGES. *Boston Med. and Surg. Journ.*, vol. lviii. p. 19. *Male, aged 75. (Mania.)*
239. HODGES. *Boston Med. and Surg. Journ.*, vol. lviii. p. 20. *Male, old.*
240. HUTCHINSON. (*Allen.*) *Trans. Path. Soc. of Lond.*, vol. viii. p. 341. *Male, aged 25. (Tropical fever.)*
241. LUTON. (*Gubler.*) *Compt. Rend. de la Soc. de Biol.*, 1856. p. 241. *Female, aged 57. (Liver complaint and phthisis.)*
242. MARTINEAU. (*Vernois.*) *De la Maladie d'Addison*, Paris, 1864. p. 40. *Female, aged 77. (Vagabonds' discoloration.)*

243. MAY. Brit. Med. Journ., 1856. p. 819. *Male, aged 46.*
(*Heart and lung disease. Gout.*)
244. MERKEL. Deutsch. Archiv f. Klin. Med., vol. x. p. 205.
Male, aged 46. (Ague, large liver and spleen, fatty disease
of heart, liver, and kidneys.)
245. MITCHELL. Amer. Journ. of Med. Sci., vol. liv. p. 413.
Female, aged 62. (Cancer, not involving the supra-renal
capsules.)
246. PUECH. Gazette Hebdom. de Méd., 1856. p. 706. *Female,*
aged 28. (Syphilis.)
247. PUECH. Gazette des Hôpitaux, 1857. p. 190. *Male, aged*
54. (Syphilis.)
248. QUAIN. (*Bucknill.*) Trans. Path. Soc. of Lond., vol. ix.
p. 412. *Female, aged 45. (Mania.)*
249. REGNARD. Gazette Hebdom. de Méd., 1865. p. 184. *Female,*
aged 43. (Mania.)
250. ROSSBACH. Virchow's Archiv f. Path. Anat., &c., vol. 1.
p. 591. *Female, aged 62; lady. (Scleroderma. Hysterical*
mania.)
251. SLOANE. (*Barclay.*) Med. Times and Gazette, vol. xxxvi.
p. 221. *Female, aged 21. (Chronic phthisis.)*

GROUP VIII.—CASES OF CANCER OF THE SUPRA-RENAL
CAPSULES without any discoloration of skin.

252. ARNOTT, H. (*Shaw.*) Trans. Path. Soc. of Lond., vol. xix.
p. 418. *Male, aged 47.*
253. BALL. (*Becquerel.*) Bullet. de la Soc. Anat., 1858. p. 423.
Male, aged 36.
254. BESNIER. Bullet. de la Soc. Anat., 1857. p. 85. *Male,*
aged 48.
255. BRISTOWE. Trans. Path. Soc. of Lond., vol. xix. p. 415.
Male, aged 62.
256. DELPIERRE. Gazette des Hôpitaux, 1856. p. 393. *Female,*
aged 81.
257. DÖDERLEIN. Schmidt's Jahrbuch, vol. cxi. p. 47. *Male,*
aged 26.
258. FALCONER. Brit. Med. Journ., 1861, vol. ii. p. 662. *Male,*
aged 49.
259. GREENHOW. (*Dickinson.*) Trans. Path. Soc. of Lond., vol.
xvii. p. 303. *Male, aged 56.*
260. GREENHOW. (*Liveing.*) Trans. Path. Soc. of Lond., vol.
xxiv. p. 238. *Male, aged 56.*

261. GRISCOM AND LEVICK. Amer. Journ. of Med. Sci., vol. xxxv. p. 392, and vol. xxxvi. p. 98. *Female, aged 58.*
262. HALDANE. Edin. Med. Journ., 1861. p. 586. *Male, aged 36.*
263. JEAFFRESON. Trans. Path. Soc. of Lond., vol. xix. p. 427. *Male, aged 68.*
264. KIRKES. Med. Times and Gazette, vol. xxxv. p. 35. *Male, aged 43.*
265. MARTINEAU. (*Second Féréol.*) De la Maladie d'Addison, Paris, 1864. p. 67. *Male.*
266. MARTINEAU. (*Letenneur.*) De la Maladie d'Addison. p. 67. *Male.*
267. MURCHISON. Trans. Path. Soc. of Lond., vol. ix. p. 400. *Female, aged 62.*
368. MURCHISON. Trans. Path. Soc. of Lond., vol. xix. p. 416. *Male, aged 55.*
269. PEACOCK and BRISTOWE. Trans. Path. Soc. of Lond., vol. viii. p. 333. *Female, aged 18.*
270. PEACOCK and BRISTOWE. Trans. Path. Soc. of Lond., vol. viii. p. 337. *Male, aged 55.*
271. SEITZ. Deutsche Klinik, 1866. p. 125. *Female, aged 28.*
272. SIBLEY. Trans. Path. Soc. of Lond., vol. x. p. 272. *Male, aged 66.*
273. SIBLEY. (*Moore.*) Med. Times and Gazette, vol. xxxiii. p. 189. *Female, aged 58.*
274. THOMPSON. Med. Times and Gazette, 1874, vol. i. p. 31. *Male, aged 49.*
275. VIRCHOW. Canstatt's Jahresbericht, 1857, Pt. IV. p. 267. *Female.*

GROUP IX.—CASES OF MISCELLANEOUS AFFECTIONS of the Supra-renal Capsules without any discoloration of skin.

276. BENNETT, RISDON. Trans. Path. Soc. of Lond., vol. xv. p. 224. *Male. (Hydatid cyst.)*
277. BRINTON. Trans. Path. Soc. of Lond., vol. ix. p. 414. *Male, aged 51. (Fatty degeneration.)*
278. CAYLEY. Trans. Path. Soc. of Lond., vol. xvi. p. 252. *Female, aged 72. (Fatty tumour.)*
279. DICKINSON. Trans. Path. Soc. of Lond., vol. xiv. p. 256. *Male. (Apoplexy.)*
280. GOOLDEN. Lancet, 1857, vol. ii. p. 266. *Male, aged 46. (Apoplexy.)*

281. GREENHOW. Trans. Path. Soc. of Lond., vol. xx. p. 429.
Male, aged 36. (Amyloid degeneration.)
282. GREENHOW. (*B. Foster.*) Trans. Path. Soc. of Lond., vol.
xviii. p. 260. *Female, aged 12. (Sarcomatous tumour.)*
283. MURRAY, J. (*Goodfellow.*) Trans. Path. Soc. of Lond.,
vol. xxi. p. 395. *Male, aged 56. (Apoplexy.)*
284. OGLE, J. W. Trans. Path. Soc. of Lond., vol. xi. p. 280.
Male, aged 43. (Apoplexy.)
285. OGLE, J. W. Trans. Path. Soc. of Lond., vol. xvi. p. 252.
Male, aged 61. (Cyst.)
286. SEITZ. Deutsche Klinik, 1866. p. 135. *Male, aged 52.*
(Hyperplastic tumour.)
287. WILKS. Trans. Path. Soc. of Lond., vol. xi. p. 280. *Male.*
(Amyloid degeneration.)

GROUP X.—CASES OF CANCER (OR SO-CALLED CANCER) of the
Supra-renal Capsules, with some discoloration of skin.

288. ADDISON. On Disease of the Supra-renal Capsules. Lond.
1855. p. 30. *Female, aged 60.*
289. ADDISON. On Disease of the Supra-renal Capsules, p. 32.
Female, aged 53.
290. ADDISON. On Disease of the Supra-renal Capsules, p. 38.
Female, aged 28.
291. ADDISON. On Disease of the Supra-renal Capsules, p. 39.
Male.
292. CAYLEY. Trans. Path. Soc. of Lond., vol. xvi. p. 250.
Female, aged 45.
293. DUCLOS. Bullet. Gén. de Thérap., 1863. p. 98. *Female,*
aged 36; laundress. (Addison's disease.)
294. GAGE. (*Heywood.*) Boston Med. and Surg. Journ., vol.
lxxi. p. 69. *Female, aged 51; lady. (Addison's disease.)*
295. METTENHEIMER. Deutsche Klinik, 1856. p. 483. *Male,*
aged 47. (Addison's disease.)
296. WILKS. (*Gibb.*) Trans. Path. Soc. of Lond., vol. viii.
p. 255. *Female, aged 33.*

GROUP XI.—CASES OF MISCELLANEOUS AFFECTIONS of the
Supra-renal Capsules, with some discoloration of skin.

297. AVERBECK. Die Addison'sche Krankheit. Erlangen, 1869.
p. 62. *Male, aged 53. (Amyloid disease.)*
298. CHARCOT. Compt. Rend. de la Soc. de Biol., 1857. p. 146.
Male, aged 57. (Fatty change.)

299. SCHET. *Presse Médicale Belge*, May, 1870. *Male, aged 39.*
(*Fatty change.*)
300. THOMPSON (Sir H.) *Trans. Path. Soc. of Lond.*, vol. ix.
p. 411. *Female, aged 81.* (*Fatty change.*)
301. WOLFF. *Berlin. Klin. Wochenschr.*, 1869. p. 195. *Male.*
(*Amyloid disease.*)

GROUP XII.—CASES IN WHICH THE LESION OF THE SUPRA-
RENAL CAPSULES is imperfectly described or of doubtful
nature.

302. ADDISON. (*Barlow.*) *On Disease of the Supra-renal Cap-*
sules. Lond., 1855. p. 35. *Male, aged 58.*
303. BARCLAY. *Lancet*, 1863, vol. i. p. 117. *Male, aged 25.*
304. BARTON. *Dub. Hosp. Gazette*, 1859. p. 203. *Female, old.*
(*Cancer?*)
305. BREHME. *Deutsche Klinik*, 1857. p. 286. *Male, aged 60*
to 70. (*Post-mortem change?*)
306. BÜHL. *Wien. Med. Wochenschr.*, 1860. p. 21. *Male.*
(*Post-mortem change?*)
307. BÜHL. *Wien. Med. Wochenschr.*, 1860. p. 22. *Female,*
aged 29.
308. CHRISTIE. *Med. Times and Gazette*, vol. xxxiv. p. 347.
Female, aged 36.
309. COLLINS. *Boston Med. and Surg. Journ.*, vol. lviii. p. 19.
Male, aged 70. (*Fatty change?*)
310. CRISP. *Trans. Path. Soc. of Lond.*, vol. xiii. p. 248. *Male,*
aged 60. (*Addison's disease?*)
311. DAYOT. *Bullet. de la Soc. Anat.*, 1857. p. 1. *Male, aged*
35.
312. FÉRÉOL, SECOND. (*Cazenave.*) *Gaz. des Hôp.*, 1856. p. 406.
Male 35. (*Fatty change?*)
313. FLETCHER, BELL. *Assoc. Med. Journ.*, 1856. p. 1011.
Male, aged 43.
314. GIBBON. *Med. Times and Gazette*, vol. xxxiv. p. 62. *Male,*
aged 52. (*Addison's disease?*)
315. HARDY. *Union Médicale*, 1858, No. 90. *Male, aged 45.*
316. HARRINSON. *Brit. Med. Journ.*, 1861, vol. ii. p. 578. *Female.*
(*Addison's disease?*)
317. HARRINSON. *Brit. Med. Journ.*, 1873, vol. ii. p. 605. *Female,*
aged 44. (*Addison's disease?*)

318. HAYDEN. Dub. Quart. Journ. Med. Sci., May 1866. p. 195.
Female, aged 58. (Fatty change?)
319. HUBER. Deutsch. Archiv f. Klin. Med., vol. iv. p. 613.
Male, aged 62. (Addison's disease?)
320. JESSOP. Trans. Path. Soc. of Lond., vol. xx. p. 384. *Female, aged 55.*
321. KELSCH: Gaz. Hebdom. de Méd., 1873. p. 607. *Male, aged 25. (Addison's disease?)*
322. LEGG, WICKHAM. (*Andrew.*) St. Barthol. Hosp. Reports, vol. x. p. 225. *Female, aged 37. (Right capsule absent, left atrophied.)*
323. LÖWE. Meissner. Schmidt's Jahrb., vol. cliv. p. 38. *Female, aged 72. (Fatty change?)*
324. MARBAIS. Berlin. Klin. Wochenschr., 1869. p. 481. *Female, aged 21. (Capsule atrophied to size of a pea.)*
325. MARTIN. Brit. Med. Journ., 1858. p. 389. *Female, aged 50. (Addison's disease?)*
326. MOXON. Trans. Path. Soc. of Lond., vol. xx. p. 385. *Female, aged 49.*
327. MURNEY. Dub. Hosp. Gaz., 1858. p. 228. *Male, aged 34. (Post-mortem change?)*
328. POPHAM. Dub. Quart. Jour. Med. Sci., Aug. 1865. p. 220.
Female, aged 50.
329. POWELL, DOUGLAS. Trans. Path. Soc. of Lond., vol. xx. p. 366. *Female, aged 22.*
330. SPENDER, J. KENT. Brit. Med. Journ., 1858. p. 768.
Female, aged 53. (Supra-renal capsules absent.)
331. TAYLOR, ISAAC. Med. Times and Gazette, vol. xxxv. p. 36.
Male, aged 42. (Post-mortem change?)
332. TUCKWELL. Trans. Path. Soc. of Lond., vol. xix. p. 421.
Male, aged 58.
333. WYATT. Med. Times and Gazette, 1865, vol. i. p. 113.
Male, aged 25. (Addison's disease?)



LONDON: PRINTED BY
SPOTTISWOODE AND CO., NEW-STREET SQUARE
AND PARLIAMENT STREET



NOVEMBER, 1874.

WORKS ON
MEDICINE, SURGERY,
AND
GENERAL SCIENCE,

PUBLISHED BY
MESSRS. LONGMANS, GREEN, AND CO.,
PATERNOSTER ROW, LONDON.

Anatomy, Surgery, and Physiology.

THE SCIENCE AND ART OF SURGERY;

Being a Treatise on Surgical Injuries, Diseases, and Operations. By JOHN ERIC ERICHSEN, Senior Surgeon to University College Hospital, and Holme Professor of Clinical Surgery in University College, London. Sixth Edition, thoroughly revised and enlarged; Illustrated by 712 Engravings on Wood. 2 vols. 8vo, price 32s.

A SYSTEM OF SURGERY,

Theoretical and Practical, in Treatises by various Authors. Edited by TIMOTHY HOLMES, M.A., Surgeon and Lecturer on Surgery, St. George's Hospital. Second Edition, thoroughly revised, with numerous Woodcuts, Lithographs, and Chromolithographs; in all 472 Illustrations. In Five Volumes, 8vo, price One Guinea each.

* * Each Volume may be had separately, as follows:—

VOL. I., price 21s., comprises all the articles on GENERAL PATHOLOGY contained in the First Volume of the previous Edition down to the end of "Collapse," with the addition of Mr. CROFT'S essay on Hectic and Traumatic Fever and the After-Treatment of Operations, which formed part of the Appendix to the previous Edition.

VOL. II., price 21s., comprises all the Treatises in the previous Edition relating to General and Special Injuries.

VOL. III., price 21s.—Diseases of the Eye and Ear, of the Organs of Circulation, Muscles, and Bones.

VOL. IV., price 21s.—Diseases of the Organs of Locomotion, of Innervation, of Digestion, of Respiration, and of the Urinary Organs.

VOL. V., price 21s.—Diseases of the Genital Organs, of the Breast, Thyroid Gland, and Skin; Operative Surgery; APPENDIX of Miscellaneous Subjects; with a General Alphabetical INDEX to the whole Work, and a List of the Authors.

QUAIN'S ELEMENTS OF ANATOMY.

Seventh Edition. Edited by WILLIAM SHARPEY, M.D., F.R.S., Professor of Anatomy and Physiology in University College, London; ALLEN THOMSON, M.D., F.R.S., Professor of Anatomy in the University of Glasgow; and JOHN CLELAND, M.D., Professor of Anatomy in Queen's College, Galway. Illustrated by upwards of 800 Engravings on Wood. 2 vols. 8vo, price 31s. 6d.

ANATOMY, DESCRIPTIVE AND SURGICAL.

By HENRY GRAY, F.R.S., late Lecturer on Anatomy at St. George's Hospital. With about 400 large Woodcuts; those in the First Edition after Original Drawings by Dr. CARTER, from Dissections made by the Author and Dr. CARTER; the additional Drawings in the Second and subsequent Editions by Dr. WESTMACOTT.

Sixth Edition, by T. HOLMES, M.A., Surgeon to St. George's Hospital; with an Introduction on General Anatomy and Development by the EDITOR. Royal 8vo, 28s.

COOPER'S DICTIONARY OF SURGERY AND ENCYCLOPÆDIA OF SURGICAL SCIENCE.

New Edition, brought down to the present time. By SAMUEL A. LANE, Surgeon to St. Mary's Hospital; assisted by various Eminent Surgeons. 2 vols. 8vo, price 50s.

TABLETS OF ANATOMY AND PHYSIOLOGY.

By THOMAS COOKE, F.R.C.S., Senior Assistant-Surgeon to, and Demonstrator of Anatomy at, the Westminster Hospital. Crown 8vo.

Nerve Centres	6d.	Bones of Upper Limb	6d.	Development of Organs.....	1s.
Sympathetic Nerves	6d.	Bones of Lower Limb	6d.	Comparative Anatomy (Eight	
Digestive Organs	6d.	Digestion	6d.	Tablets)	1s.
Peritoneum, &c.	6d.	Development (Gen. Devt. of		Ear and Eye	1s.
Arteries of Head and Neck ..	6d.	Embryo)	6d.	Circulation, Respiration, Ani-	
Arteries of Limbs	6d.	Muscles	9d.	mal Heat.....	1s. 6d.
Bones of Skull, &c.	6d.	Cranial Nerves	9d.	Loose Tablets (3 dozen) ..	2s. 6d.
Bones of Face, &c.	6d.	Surgical Anatomy	9d.		

OUTLINES OF PHYSIOLOGY, HUMAN AND COMPARATIVE.

By JOHN MARSHALL, F.R.S., Professor of Surgery in University College, London; Surgeon to the University College Hospital. With 122 Woodcut Illustrations. 2 vols. crown 8vo, 32s.

TODD AND BOWMAN'S PHYSIOLOGICAL ANATOMY AND PHYSIOLOGY OF MAN.

VOL. I. New Edition by Dr. L. S. BEALE, F.R.S., in course of publication, with numerous Illustrations. PARTS I. & II., 8vo, 7s. 6d. each.—Vol. II. 25s.

COMPARATIVE ANATOMY AND PHYSIOLOGY OF THE VERTEBRATE ANIMALS.

By RICHARD OWEN, F.R.S., Superintendent of the Nat. Hist. Departments, British Museum. 3 vols. 8vo, with 1,472 Woodcuts, 73s. 6d.

VOL. I. *Fishes and Reptiles*, with 452 Woodcuts, 21s.

VOL. II. *Warm-blooded Vertebrates*, with 406 Woodcuts, 21s.

VOL. III. *Mammalia, including Man*, with 614 Woodcuts, 31s. 6d.

Medical and Psychological Literature.

LECTURES ON THE PRINCIPLES AND PRACTICE OF PHYSIC,

Delivered at King's College, London, by Sir THOMAS WATSON, Bart., M.D., F.R.S., Hon. LL.B. Cantab., Hon. D.C.L. Oxon., &c., Physician-in-Ordinary to the Queen. Fifth Edition, revised and enlarged, with two Plates. 2 vols. 8vo, price 36s.

CLINICAL LECTURES AND ESSAYS.

By SIR JAMES PAGET, Bart. Edited by F. HOWARD MARSH, Assistant-Surgeon to St. Bartholomew's Hospital. 1 vol. 8vo.

[*In the press.*]

ON HOSPITALISM AND THE CAUSES OF DEATH AFTER OPERATIONS.

By JOHN ERIC ERICHSEN, Senior Surgeon to University College Hospital, and HOLME Professor of Clinical Surgery in University College. Crown 8vo, price 3s. 6d.

A DICTIONARY OF MEDICINE.

Edited by RICHARD QUAIN, M.D., F.R.S., Fellow of the Royal College of Physicians, and Physician to the Hospital for Diseases of the Chest at Brompton; assisted by numerous Eminent Writers. In One Volume, 8vo.

[*Preparing for publication.*]

COPLAND'S DICTIONARY OF PRACTICAL MEDICINE :

Comprising Special Pathology, the Principles of Therapeutics, the Nature and Treatment of Diseases, Morbid Structures, and the Disorders especially Incidental to Climates, to Races, to Sex, and to the Epochs of Life; with an Appendix of Approved Formulæ. Abridged from the larger work by the Author, assisted by J. C. COPLAND, M.R.C.S. 8vo, 36s.

ANALYSIS OF THE PHENOMENA OF THE HUMAN MIND.

By JAMES MILL. A New Edition, with Notes Illustrative and Critical, by ALEXANDER BAIN, ANDREW FINDLATER, and GEORGE GROTE. Edited, with additional Notes, by JOHN STUART MILL. 2 vols. 8vo, 28s.

THE SENSES AND THE INTELLECT.

By ALEXANDER BAIN, LL.D., Professor of Logic in the University of Aberdeen. Third Edition, with numerous Emendations, and a Review of Darwin on Expression as a Postscript. 8vo, 15s.

MENTAL AND MORAL SCIENCE:

A Compendium of Psychology and Ethics. By the same Author. Third Edition. Crown 8vo, 10s. 6d. To be had also in TWO PARTS:—

PART I., *Mental Science*, price 6s. 6d.; PART II., *Moral Science*, price 4s. 6d.

THE HISTORY OF PHILOSOPHY FROM THALES TO COMTE.

By GEORGE HENRY LEWES. Fourth Edition, corrected and partly rewritten. 2 vols. 8vo, price 32s.

THE SECRET OF HEGEL:

being the Hegelian System in Origin, Principle, Form, and Matter. By JAMES HUTCHISON STIRLING, F.R.C.S. & LL.D. Edin. 2 vols., 8vo, 28s.

SIR WILLIAM HAMILTON;

being the Philosophy of Perception: an Analysis. By JAMES HUTCHISON STIRLING, F.R.C.S. & LL.D. Edin. 8vo, 5s.

AN EXAMINATION OF SIR W. HAMILTON'S PHILOSOPHY,

And of the Principal Philosophical Questions discussed in his Writings. By JOHN STUART MILL. Fourth Edition. 8vo, 16s.

A SYSTEM OF LOGIC, RATIOCINATIVE AND INDUCTIVE;

Being a Connected View of the Principles of Evidence and the Methods of Scientific Investigation. By JOHN STUART MILL. Eighth Edition. 2 vols. 8vo, price 25s.

KILLICK'S HANDBOOK OF MILL'S LOGIC, price 3s. 6d.

STEBBING'S ANALYSIS OF MILL'S LOGIC, price 3s. 6d.

LOGIC, DEDUCTIVE AND INDUCTIVE.

By ALEXANDER BAIN, LL.D., Professor of Logic in the University of Aberdeen. In Two Parts, crown 8vo, price 10s. 6d. Each Part may be had separately:—

PART I., *Deduction*, price 4s.; PART II., *Induction*, price 6s. 6d.

Pathology and the Treatment of Disease.

LECTURES ON SURGICAL PATHOLOGY.

Delivered at the Royal College of Surgeons of England. By Sir JAMES PAGET, Bart., F.R.S., D.C.L., &c., Serjeant-Surgeon to the Queen, Surgeon in Ordinary to the Prince of Wales, Surgeon to St. Bartholomew's Hospital. The Third Edition, revised and re-edited by the AUTHOR and W. TURNER, M.B., Professor of Anatomy in the University of Edinburgh. 8vo, with 131 Woodcuts, price 21s.

PULMONARY CONSUMPTION; ITS NATURE, VARIETIES, AND TREATMENT:

With an Analysis of One Thousand Cases to exemplify its Duration. By C. J. B. WILLIAMS, M.D., F.R.S., Fellow of the Royal College of Physicians; Senior Consulting Physician to the Hospital for Consumption, Brompton; and by C. T. WILLIAMS, M.A., M.D. Oxon.; Fellow of the Royal College of Physicians; Physician to the Hospital for Consumption, Brompton. Post 8vo, price 10s. 6d.

CONSUMPTION,

Its Proximate Causes and Specific Treatment by the Hypophosphites, upon the Principles of Stœchiological Medicine. By J. F. CHURCHILL, M.D. With an Appendix on the Local Treatment of Respiratory Diseases by Specific Inhalants. *[In the press.]*

A TREATISE ON MEDICAL ELECTRICITY, THEORETICAL AND PRACTICAL;

And its Use in the Treatment of Paralysis, Neuralgia, and other Diseases. By JULIUS ALTHAUS, M.D., Member of the Royal College of Physicians; Fellow of the Royal Medical and Chirurgical Society; Senior Physician to the Infirmary for Epilepsy and Paralysis. Third Edition, enlarged and revised; with 147 Illustrations engraved on Wood. 8vo, price 18s.

NOTES ON THE TREATMENT OF SKIN DISEASES.

By ROBERT LIVEING, M.A. and M.D. Cantab., F.R.C.P. Lond., Physician to the Middlesex Hospital. Second Edition, with Additions. 18mo, price 2s. 6d.

ELEPHANTIASIS GRÆCORUM, or True

Leprosy; being the Goulstonian Lectures for 1873, revised and enlarged. By ROBERT LIVEING, M.A. and M.D. Cantab., F.R.C.P. London, Physician to the Middlesex Hospital. Crown 8vo, price 4s. 6d.

ON CHRONIC BRONCHITIS,

Especially as connected with GOUT, EMPHYSEMA, and DISEASES of the HEART.

By E. HEADLAM GREENHOW, M.D., F.R.C.P., &c., Consulting-Physician to the Western General Dispensary, Physician to, and Lecturer on the Principles and Practice of Medicine at, the Middlesex Hospital. 8vo, 7s. 6d.

A TREATISE ON THE CONTINUED FEVERS

OF GREAT BRITAIN. By CHARLES MURCHISON, M.D., I.L.D., F.R.S., &c., Fellow of the Royal College of Physicians; Physician and Lecturer on the Principles and Practice of Medicine, St. Thomas's Hospital. Second Edition, thoroughly revised and enlarged; with 5 Chromolithographs, 19 Diagrams in Lithography, and 22 Illustrations engraved on Wood. 8vo, price 24s.

TYPHOID FEVER;

Its Nature, Mode of Spreading, and Prevention. By WILLIAM BUDD, M.D., F.R.S. With Four Plates (one coloured). Royal 8vo, price 16s.

LECTURES ON FEVER

Delivered in the Theatre of the Meath Hospital and County of Dublin Infirmary. By WILLIAM STOKES, M.D., D.C.L. Oxon., F.R.S., Regius Professor of Physic in the University of Dublin and Physician-in-Ordinary to the Queen in Ireland. Edited by J. W. MOORE, M.D., F.K.Q.C.P., Assistant-Physician to the Cork-Street Fever Hospital, Dublin. 8vo, price 15s.

A TREATISE ON GOUT AND RHEUMATIC

GOUT. By ALFRED B. GARROD, M.D., F.R.S., &c., Physician to King's College Hospital. A New Edition, thoroughly revised, with much additional practical matter. Crown 8vo. [Nearly ready.]

CLINICAL RESEARCHES ON DISEASE IN INDIA.

By CHARLES MOREHEAD, M.D., Surgeon to the Jarnsetjee Jeejeebhoy Hospital. Second Edition, thoroughly revised. 8vo, 21s.

ON CANCER: ITS ALLIES AND COUNTERFEITS.

By WEEDEN COOKE, Surgeon to the Cancer Hospital and to the Royal Free Hospital. With 12 Coloured Plates. 8vo, 12s. 6d.

DISEASES OF THE KIDNEY AND URINARY DERANGEMENTS.

By W. HOWSHIP DICKINSON, M.D. Cantab. F.R.C.P., &c., Physician and Lecturer on Pathology, St. George's Hospital; Physician to the Hospital for Sick Children. New Edition, in Three Parts:—

PART I.—*Diabetes*. 8vo.

[Nearly ready.]

THE SKIM-MILK TREATMENT OF DIABETES AND BRIGHT'S DISEASE ;

With Clinical Observations on the Symptoms and Pathology of these Affections. By ARTHUR SCOTT DONKIN, M.D. Edin., M.D. Durham, &c. Crown 8vo, price 10s. 6d.

ON THE SURGICAL DISEASES OF THE TEETH AND CONTIGUOUS STRUCTURES. With their Treatment. By S. JAMES A. SALTER, M.B., F.R.S., Dental Surgeon to Guy's Hospital. 8vo, with numerous Illustrations. [*Nearly ready.*]

INJURIES OF THE EYE, ORBIT, AND EYE-LIDS ;

Their Immediate and Remote Effects. By GEORGE LAWSON, F.R.C.S., Surgeon to the Royal London Ophthalmic Hospital, Moorfields. 8vo, with 92 Woodcuts, price 12s. 6d.

Diseases of Women and Children, and Popular Medical Works.

THE DIAGNOSIS AND TREATMENT OF DISEASES OF WOMEN, INCLUDING THE DIAGNOSIS OF PREGNANCY.

By GRAILY HEWITT, M.D., Professor of Midwifery and Diseases of Women, University College, and Obstetric Physician to the Hospital; Examiner in Obstetric Medicine to the University of London. Third Edition, revised, and for the most part re-written; with several additional Illustrations. 8vo, with 132 Engravings on Wood, price 24s.

THE DUBLIN PRACTICE OF MIDWIFERY.

By HENRY MAUNSELL, M.D., formerly Professor of Midwifery in the Royal College of Surgeons in Ireland. New Edition, enlarged and revised. Edited by T. M. MADDEN, M.R.I.A., &c., Senior Assistant-Physician to the Dublin Lying-in-Hospital. Fcap. 8vo, 5s.

HINTS TO MOTHERS FOR THE MANAGEMENT OF THEIR HEALTH DURING PREGNANCY AND IN THE LYING-IN ROOM :

With Hints on Nursing, &c. By THOMAS BULL, M.D. New Edition, revised and enlarged. Fcap. 5s.

THE MATERNAL MANAGEMENT OF CHILDREN IN HEALTH AND DISEASE.

By the same Author. New Edition, revised and enlarged. Fcap. 5s.

ON THE SURGICAL TREATMENT OF CHILDREN'S DISEASES.

By TIMOTHY HOLMES, Surgeon to St. George's Hospital, and Surgeon-in-Chief to the Metropolitan Police. Second Edition, thoroughly revised; with Additional Chapters on Orthopædic Surgery and Paracentesis Thoracis. With 9 Chromolithographic Plates and 112 Woodcut Illustrations from Original Drawings. 8vo, 21s.

LECTURES ON THE DISEASES OF INFANCY AND CHILDHOOD.

By CHARLES WEST, M.D., &c., Physician to the Hospital for Sick Children; Fellow of the Royal College of Physicians. Sixth Edition, revised and enlarged. 8vo, price 18s.

THE HANDBOOK FOR MIDWIVES.

By HENRY FLY SMITH, M.B. Oxon., M.R.C.S., late Assistant-Surgeon at the Hospital for Sick Women, Soho Square. With 41 Woodcuts. Crown 8vo, price 5s.

Materia Medica and Therapeutics.

THOMSON'S CONSPECTUS ADAPTED TO THE BRITISH PHARMACOPŒIA.

By EDMUND LLOYD BIRKETT, M.D., &c., Physician to the City of London Hospital for Diseases of the Chest. New Edition, with Supplement containing Notices of the New Medicines and Preparations added in 1874 to the British Pharmacopœia. 18mo, 6s.

THE ESSENTIALS OF MATERIA MEDICA AND THERAPEUTICS.

By ALFRED BARING GARROD, M.D., F.R.S., Fellow of the Royal College of Physicians; Professor of Materia Medica and Therapeutics, King's College, London. Fourth Edition, revised and edited, under the supervision of the Author, by E. B. BAXTER, M.D., Med. Tutor King's Coll. and Physician to the Evelinor Hospital for Sick Children. Crown 8vo, price 12s. 6d.

DR. PEREIRA'S MATERIA MEDICA AND THERAPEUTICS,

Abridged, and adapted for the use of Medical and Pharmaceutical Practitioners and Students. Edited by Professor R. BENTLEY, M.R.C.S., F.L.S., and by Professor T. REDWOOD, Ph.D., F.C.S. With an Appendix containing the New Medicines included in 1874 by the Medical Council in the British Pharmacopœia, and Commentaries thereon by the Editors. 8vo, with 126 Woodcuts, price 25s.

Chemistry.

DICTIONARY OF CHEMISTRY AND THE ALLIED BRANCHES OF OTHER SCIENCES.

By HENRY WATTS, F.R.S., Editor of the Journal of the Chemical Society, assisted by eminent Scientific and Practical Chemists. 6 vols. 8vo, £8 14s. 6d.

SECOND SUPPLEMENT, bringing the Record of Chemical Discovery down to the end of 1874, *in the press*.

ELEMENTS OF CHEMISTRY,

Theoretical and Practical. By WILLIAM ALLEN MILLER, M.D., F.R.S., late Professor of Chemistry, King's College, London. Revised, with Additions, by HERBERT MACLEOD, F.C.S., Professor of Experimental Science, Indian Civil Engineering College, Cooper's Hill. 3 vols. 8vo, price 3*l*. May be had separately:—

PART I.—CHEMICAL PHYSICS. 8vo, price 15*s*.

PART II.—INORGANIC CHEMISTRY, price 21*s*.

PART III.—ORGANIC CHEMISTRY, price 24*s*.

INTRODUCTION TO THE STUDY OF INORGANIC CHEMISTRY.

By the same Author. (Forming one of the Series of Text-Books of Science, Physical and Mechanical, in course of publication, edited by T. M. GOODEVE, M.A., and C. W. MERRIFIELD, F.R.S.) With 71 Figures on Wood. Small 8vo, price 3*s*. 6d.

QUANTITATIVE CHEMICAL ANALYSIS.

By T. E. THORPE, Ph.D., F.R.S.E., Professor of Chemistry in the Andersonian University, Glasgow. (Forming one of the Series of Text-Books of Science, Physical and Mechanical, in course of publication, edited by T. M. GOODEVE, M.A., and C. W. MERRIFIELD, F.R.S.) With 88 Woodcuts. Small 8vo, price 4*s*. 6d.

QUALITATIVE CHEMICAL ANALYSIS AND

LABORATORY PRACTICE. By T. E. THORPE, Ph.D., F.R.S.E., Professor of Chemistry in the Andersonian University, Glasgow; and M. M. PATTISON MUIR. (Forming one of the Series of Text-Books of Science, Physical and Mechanical, in course of publication, edited by T. M. GOODEVE, M.A., and C. W. MERRIFIELD, F.R.S.) With Plate and 57 Woodcuts. Small 8vo, price 3*s*. 6d.

INTRODUCTION TO THE STUDY OF ORGANIC CHEMISTRY;

The Chemistry of Carbon and its Compounds. By H. E. ARMSTRONG, Ph.D., Professor of Chemistry in the London Institution. (Forming one of the Series of Text-Books of Science, Physical and Mechanical, in course of publication, edited by T. M. GOODEVE, M.A., and C. W. MERRIFIELD, F.R.S.) With 8 Woodcuts. Small 8vo, price 3*s*. 6d.

A MANUAL OF CHEMICAL PHYSIOLOGY,
Including its Points of Contact with Pathology. By J. LOUIS W.
THUDICUM, M.D. With 10 Woodcuts. 8vo, price 7s. 6d.

A COURSE OF PRACTICAL CHEMISTRY,
Arranged for the use of Medical Students. By WILLIAM ODLING, M.B.,
F.R.S., Fellow of the Royal College of Physicians, Secretary to the
Chemical Society, and Lecturer on Chemistry at St. Bartholomew's
Hospital. Fourth Edition. Crown 8vo, with 71 Woodcuts, price 7s. 6d.

CHEMICAL NOTES FOR THE LECTURE
ROOM—ON HEAT, LAWS OF CHEMICAL COMBINATION,
AND CHEMISTRY OF THE NON-METALLIC ELEMENTS.
By THOMAS WOOD, Ph.D., F.C.S. Third Edition. Crown 8vo, 5s.
NOTES ON THE METALS, by the same Author, Second Edition, price 5s.

SELECT METHODS IN CHEMICAL ANA-
LYSIS, CHIEFLY INORGANIC.
By WILLIAM CROOKES, F.R.S., F.C.S., &c. Editor of "The Chemical
News" and of "The Quarterly Journal of Science." With 22 Woodcuts.
Crown 8vo, price 12s. 6d., cloth.

A PRACTICAL HANDBOOK OF DYEING
AND CALICO PRINTING.
By W. CROOKES, F.R.S., F.C.S., &c. With 11 Page Plates, 49 Speci-
mens of Dyed and Printed Fabrics, and 36 Woodcuts. 8vo, price 24s.

INDUSTRIAL CHEMISTRY ;
A Manual for Manufacturers and for use in Colleges or Technical Schools.
Being a Translation by Dr. J. D. BARRY of Professors Stohmann and
Engler's German Edition of PAYEN'S *Précis de Chimie Industrielle*. Edited
throughout and supplemented with Chapters on the Chemistry of the
Metals by B. H. PAUL, Ph.D. In One thick Volume, 8vo, with very
numerous Plates and Woodcuts.

Science and Natural History.

BRANDE'S DICTIONARY OF SCIENCE, LITE-
RATURE, AND ART ;

Comprising the Definitions and Derivations of the Scientific Terms in
general use, together with the History and Descriptions of the Scientific
Principles of nearly every branch of Human Knowledge. Fourth Edition,
reconstructed and extended under the Joint-Editorship of the late Author
and the Rev. GEORGE W. COX, M.A. ; assisted by Contributors of eminent
Scientific and Literary Acquirements. 3 vols. medium 8vo, 63s.

URE'S DICTIONARY OF ARTS, MANUFACTURES, AND MINES;

Containing a clear Exposition of their Principles and Practice. Sixth Edition, re-written and enlarged by ROBERT HUNT, F.R.S., Keeper of Mining Records, assisted by numerous Contributors. With above 2000 Woodcuts. 3 vols. medium 8vo, 4*l.* 14*s.* 6*d.*

INTRODUCTION TO EXPERIMENTAL PHYSICS, THEORETICAL AND PRACTICAL; including Directions for Constructing Physical Apparatus and for Making Experiments. By A. F. WEINHOLD, Professor in the Royal Technical School at Chemnitz. Translated and edited (with the Author's sanction) by B. LOEWY, F.R.A.S. With a Preface by G. C. FOSTER, F.R.S., Professor of Physics in University College, London. With numerous Wood Engravings. 8vo. [Nearly ready.]

ELEMENTARY TREATISE ON PHYSICS,

Experimental and Applied, for the use of Colleges and Schools. Translated and edited from GANOT'S *Eléments de Physique* (with the Author's sanction) by E. ATKINSON, Ph.D., F.C.S., Professor of Experimental Science, Staff College, Sandhurst. Sixth Edition, revised and enlarged, with 4 Coloured Plates and 746 Woodcuts. Post 8vo, price 15*s.*

NATURAL PHILOSOPHY FOR GENERAL READERS AND YOUNG PERSONS;

Being a Course of Physics divested of Mathematical Formulæ, and expressed in the language of daily life. Translated from GANOT'S *Cours de Physique*, with the Author's sanction, by E. ATKINSON, Ph.D., F.C.S. With 404 Woodcuts. Crown 8vo, price 7*s.* 6*d.*

THE CORRELATION OF PHYSICAL FORCES.

Sixth Edition, with other contributions to Science. By the Hon. Sir W. R. GROVE, M.A., F.R.S., one of the Judges of the Court of Common Pleas. 8vo, price 15*s.*

AN ELEMENTARY EXPOSITION OF THE DOCTRINE OF ENERGY.

By D. D. HEATH. Post 8vo, with Woodcuts. [In the press.]

AIR AND RAIN;

The Beginnings of a Chemical Climatology. By ROBERT ANGUS SMITH, Ph.D., F.R.S., F.C.S. (General) Inspector of Alkali Works for the Government. With 8 Illustrations. 8vo, price 24*s.*

HEAT A MODE OF MOTION.

By JOHN TYNDALL, LL.D., D.C.L., F.R.S., Professor of Natural Philosophy in the Royal Institution of Great Britain. Fourth Edition, with Additions and Illustrations. Crown 8vo, with Plate and 108 Woodcuts, 10s. 6d.

SOUND; A COURSE OF EIGHT LECTURES

Delivered at the Royal Institution. By the same Author. Second Edition. With a Portrait of M. CHLADNI, and 169 Woodcuts. Crown 8vo, 9s.

LECTURES ON LIGHT delivered in the United States of America in the years 1872 and 1873; with an Appendix. By the same Author. With Frontispiece and 59 Diagrams. Crown 8vo. Price 7s. 6d.

CONTRIBUTIONS TO MOLECULAR PHYSICS IN THE DOMAIN OF RADIANT HEAT.

By the same Author. With 2 Plates and 31 Woodcuts. 8vo, price 16s.

RESEARCHES ON DIAMAGNETISM AND MAGNETIC-CRYSTALLIC ACTION; including the Question of Diamagnetic Polarity. By the same Author. With 6 Plates and many Woodcuts. 8vo, price 14s.

NOTES OF A COURSE OF SEVEN LECTURES ON ELECTRICAL PHENOMENA AND THEORIES. By the same Author. Crown 8vo, price 1s. sewed, or 1s. 6d. cloth.

NOTES OF A COURSE OF NINE LECTURES ON LIGHT. By the same Author. Crown 8vo, 1s. sewed, or 1s. 6d. cloth.

FRAGMENTS OF SCIENCE.

By the same Author. Fourth Edition. 8vo, price 14s.

ADDRESS

Delivered before the British Association assembled at Belfast; with Additions and a Preface. By JOHN TYNDALL, F.R.S., President. 8vo, price 3s.

THEORY OF HEAT.

By J. CLERK MAXWELL, M.A., LL.D. Edin., F.R.SS. L. & E., Professor of Experimental Physics in the University of Cambridge. (Forming one of the Series of Text-Books of Science, Mechanical and Physical, in course of publication, edited by T. M. GOODEVE, M.A., and C. W. MERRIFIELD, F.R.S.) With 41 Woodcuts and Diagrams. Small 8vo, price 3s. 6d. cloth.

BRINKLEY'S ASTRONOMY.

Revised and partly re-written. By J. W. STUBBS, D.D., Fellow and Tutor of Trinity College; and F. BRUNNOW, Ph.D. Professor of Astronomy in the University of Dublin. With Additional Chapters and Questions for Examination. Second Edition, enlarged and improved. Crown 8vo, with Diagrams, price 6s.

OUTLINES OF ASTRONOMY.

By Sir JOHN F. W. HERSCHEL, Bart., K.H., &c., Member of the Institute of France. Twelfth Edition, with 9 Plates, and numerous Diagrams. Square crown 8vo, price 12s.

CELESTIAL OBJECTS FOR COMMON TELESCOPES.

By the Rev. T. W. WEBB, M.A., F.R.A.S., Incumbent of Hardwick, Herefordshire. New Edition, thoroughly revised; with Map of the Moon and numerous Woodcuts. Crown 8vo, price 7s. 6d.

A NEW STAR ATLAS,

For the Library, the School, and the Observatory, in Twelve Circular Maps (with Two Index Plates). Intended as a Companion to 'Webb's Celestial Objects for Common Telescopes.' With a Letterpress Introduction on the Study of the Stars, illustrated by 9 Diagrams. By RICHARD A. PROCTOR, B.A., Hon. Sec. R.A.S. Crown 8vo, price 5s.

SPECTRUM ANALYSIS

In its Application to Terrestrial Substances and the Physical Constitution of the Heavenly Bodies. Familiarly explained by Dr. H. SCHELLEN, Director der Realschule, Cologne. Translated from the German by JANE and CAROLINE LASSELL; edited, with Notes, by W. HUGGINS, LL.D., F.R.S. With 13 Plates (6 Coloured), including Angström's and Kirchhoff's Maps, and 223 Woodcuts. 8vo, price 28s.

THE MOON,

And the condition and Configurations of its Surface. By EDMUND NEILSON, Fellow of the Royal Astronomical Society, &c. Illustrated by Maps and Plates. *[In preparation.]*

THE TRANSITS OF VENUS;

A Popular Account of Past and Coming Transits, from the first observed by Horrocks A.D. 1639 to the Transit of A.D. 2112. By R. A. PROCTOR, B.A. Crown 8vo, with 20 Plates and numerous Woodcut Illustrations. *[Nearly ready.]*

THE UNIVERSE AND THE COMING TRANSITS:

Presenting Researches into and New Views respecting the Constitution of the Heavens. By R. A. PROCTOR, B.A. With 22 Lithographic Charts (4 Coloured), and 22 Woodcut Diagrams. 8vo, price 16s.

THE MOON; her Motions, Aspect, Scenery, and Physical Condition.

By RICHARD A. PROCTOR, B.A. With 22 Lithographic Plates, Charts, and Diagrams, 1 Wood Engraving, and 3 Lunar Photographs by Rutherford, of New York. Crown 8vo. Price 15s.

THE SUN: RULER, LIGHT, FIRE, AND LIFE OF THE PLANETARY SYSTEM.

By RICHARD A. PROCTOR, B.A. Second Edition, revised ; with 10 Plates (7 coloured) and 106 Figures engraved on Wood. Crown 8vo, price 14s.

OTHER WORLDS THAN OURS ;

The Plurality of Worlds Studied under the Light of Recent Scientific Researches. By R. A. PROCTOR, B.A. Third Edition, revised and enlarged ; with 14 Illustrations (6 coloured). Crown 8vo, price 10s. 6d.

THE ORBS AROUND US ;

A Series of Familiar Essays on the Moon and Planets, Meteors and Comets, the Sun and Coloured Pairs of Suns. By RICHARD A. PROCTOR, B.A. Crown 8vo, price 7s. 6d.

ESSAYS ON ASTRONOMY :

A Series of Papers on Planets and Meteors, the Sun and sun-surrounding Space, Stars, and Star Cloudlets ; and a Dissertation on the approaching Transit of Venus : preceded by a Sketch of the Life and Work of Sir John Herschel. By the same Author. With 10 Plates and 24 Woodcuts. 8vo, price 12s.

LIGHT SCIENCE FOR LEISURE HOURS ;

A Series of Familiar Essays on Scientific Subjects, Natural Phenomena, &c. By the same Author. First and Second Series. Crown 8vo, price 7s. 6d. each.

A HANDBOOK OF PRACTICAL TELEGRAPHY.

By R. S. CULLEY, Member Inst. C.E., Engineer-in-chief of Telegraphs to the Post Office. The Sixth Edition, revised and enlarged ; with 144 Woodcuts and 5 Lithographic Plates of Apparatus. 8vo, price 16s.

METALS, THEIR PROPERTIES AND TREATMENT.

By CHARLES LOUDON BLOXAM, Professor of Chemistry in King's College, London ; Professor of Chemistry in the Royal Military Academy and in the Department of Artillery Studies, Woolwich. (Forming one of the Series of Text-Books of Science, Physical and Mechanical, edited by T. M. GOODEVE, M.A., and C. W. MERRIFIELD, F.R.S.) With 105 Figures on Wood. Small 8vo, price 3s. 6d.

MANUAL OF PRACTICAL ASSAYING.

By JOHN MITCHELL, F.C.S. Fourth Edition, in which are incorporated all the recent valuable improvements in Assaying ; including Volumetric and Colorimetric Assays, and the Blowpipe Assays. Edited and re-written by W. CROOKES, F.R.S., with 199 Figures and Diagrams engraved on wood. 8vo, price 31s. 6d.

A PRACTICAL TREATISE ON METALLURGY,

Adapted from the last German Edition of Professor KERL'S *Metallurgy*, by WILLIAM CROOKES, F.R.S., and ERNST RÖHRIG, Ph.D. 3 vols. 8vo, price 4*l.* 19*s.*

VOL. I. LEAD, SILVER, ZINC, CADMIUM, TIN, MERCURY, BISMUTH, ANTIMONY, NICKEL, ARSENIC, GOLD, PLATINUM, and SULPHUR, with 207 Woodcuts. 8vo, price 31*s.* 6*d.*

VOL. II. COPPER and IRON, with 273 Woodcuts, price 36*s.*

VOL. III. STEEL, FUEL, and Supplement, with 145 Woodcuts, 31*s.* 6*d.*

THE TREASURY OF BOTANY, OR POPULAR DICTIONARY OF THE VEGETABLE KINGDOM;

With which is incorporated a Glossary of Botanical Terms. Edited by J. LINDLEY, M.D., F.R.S., and T. MOORE, F.L.S., assisted by numerous Contributors. With 20 Steel Plates, and numerous Woodcuts from Original Designs by W. H. FITCH. 2 Parts, fcap. 8vo, 12*s.*

LOUDON'S ENCYCLOPÆDIA OF PLANTS:

Comprising the Specific Character, Description, Culture, History, Application in the Arts, and every other desirable particular respecting all the plants indigenous to, cultivated in, or introduced into, Britain. Corrected by Mrs. LOUDON. 8vo, with above 12,000 Woodcuts, price 42*s.*

HANDBOOK OF HARDY TREES, SHRUBS, AND HERBACEOUS PLANTS.

Containing Descriptions, Native Countries, &c., of a Selection of the Best Species in Cultivation; together with Cultural Details, Comparative Hardiness, suitability for particular Positions, &c. Based on the French Work of Messrs. DECAISNE and NAUDIN, intitled "Manuel de l'Amateur des Jardins," and including the 264 original Woodcut Illustrations. By W. B. HEMSLEY, formerly Assistant at the Herbarium of the Royal Gardens, Kew. Medium 8vo, price 21*s.*

DECAISNE & LE MAOUT'S GENERAL SYS- TEM OF DESCRIPTIVE AND ANALYTICAL BOTANY:

Comprising: I. Outlines of Organography, Anatomy, and Physiology; II. Descriptions and Illustrations of the Orders. Translated from the French by MRS. HOOKER. The orders arranged after the method followed in the Universities and Schools of Great Britain, its Colonies, America, and India, with Additions, an Appendix on the Natural Method, and a Synopsis of the Orders, by J. D. HOOKER, C.B., F.R.S., &c., Director of the Royal Botanic Gardens, Kew. With 5,500 Woodcuts from Designs by L. Stenheil and A. Riocreux. Imperial 8vo, price 52*s.* 6*d.*

Index.

Althaus's Medical Electricity 5	Neison on the Moon 13
Armstrong's Organic Chemistry 9	Odling's Practical Chemistry 10
Bain on Mental and Moral Science 4	Owen's Comparative Anatomy and Physiology of Vertebrata 3
— on the Senses and Intellect 4	Paget's Clinical Lectures and Ad- dresses 3
—'s Logic 4	Paget's Surgical Pathology 5
Bloxam on Metals 14	Payen's Industrial Chemistry 10
Brande's Dictionary of Science, Literature, and Art 10	Pereira's Elements of Materia Medica 8
Brinkley's Astronomy 12	Proctor on Plurality of Worlds 14
Budd on Typhoid Fever 6	— on the Sun 14
Bull's Hints to Mothers 7	Proctor's Astronomical Essays 14
— Management of Children 7	— Moon 13
Churchill on Consumption 5	— New Star Atlas 13
Cooke on Cancer 6	— Orbs Around us 14
Cooke's Tablets of Anatomy and Physiology 2	— Scientific Essays 14
Cooper's Surgical Dictionary 2	— Transits of Venus 13
Copland's Dictionary of Medicine 3	— Universe 13
Crookes on Chemical Analysis 10	Quain's Anatomy 2
— Handbook on Dyeing 10	— Medical Dictionary 3
Culley's Handbook of Telegraphy 14	Salter on the Teeth 7
Decaisne and Le Maout's Botany 15	Schellen's Spectrum Analysis 13
Dickinson on Diseases of the Kidney 6	Smith's Air and Rain 11
Donkin's Skim-Milk Treatment of Diabetes and Bright's Disease 7	— Handbook for Midwives 8
Erichsen's Hospitalism 3	Stebbing's Analysis of Mill's Logic 4
— Surgery 1	Stirling's Hamilton 4
Ganot's Natural Philosophy 11	— Secret of Hegel 4
— Physics 11	Stokes on Fever 6
Garrod on Gout 6	Thomson's Conspectus, by Birkett 8
Garrod's Materia Medica 8	Thorpe's Quantitative Chemical Analysis 9
Gray's Anatomy 2	Thorpe and Muir's Qualitative Analysis 9
Greenhow on Chronic Bronchitis 6	Thudichum's Chemical Physiology 10
Grove's Correlation of Physical Forces 11	Todd and Bowman's Anatomy and Physiology of Man 2
Heath on Doctrine of Energy 11	Tyndall on Diamagnetism 12
Hemsley's Trees, Shrubs, &c. 15	Tyndall's Belfast Address 12
Herschel's Outlines of Astronomy 12	— Fragments of Science 12
Hewitt on the Diseases of Women 7	— Lectures on Heat 12
Holmes's Surgery 1	— Light 12
— Surgical Diseases of Infancy 8	— Sound 12
Kerl's Metallurgy 15	— Molecular Physics 12
Killick's Handbook of Mill's Logic 4	— Notes on Electricity 12
Lawson on Injuries of the Eye 7	— Notes on Light 12
Lewes's History of Philosophy 4	Ure's Dictionary of Arts, Manufac- tures, and Mines 11
Lindley's Treasury of Botany 15	Watson's Principles and Practice of Physic 3
Living on Skin Diseases 5	Watts's Dictionary of Chemistry 9
— Leprosy 5	— Supplements to ditto 9
Loudon's Encyclopædia of Plants 15	Webb's Celestial Objects for Com- mon Telescopes 13
Marshall's Outlines of Physiology 2	Weinhold's Experimental Physics 11
Maunsell's Dublin Midwifery 7	West on the Diseases of Children 8
Maxwell's Theory of Heat 12	Williams on Pulmonary Consumption 5
Mill on the Human Mind 4	Wood's Chemical Notes 10
Mill's Hamilton's Philosophy 4	— Notes on the Metals 10
— System of Logic 4	
Miller's Elements of Chemistry 9	
— Inorganic Chemistry 9	
Mitchell's Assaying 14	
Morehead on Disease in India 6	
Murchison on Continued Fevers 6	

